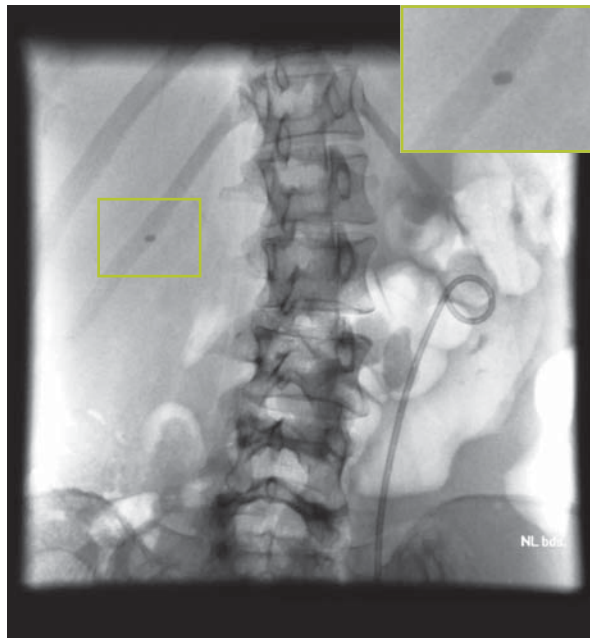


Dr. Thorsten Bergsdorf

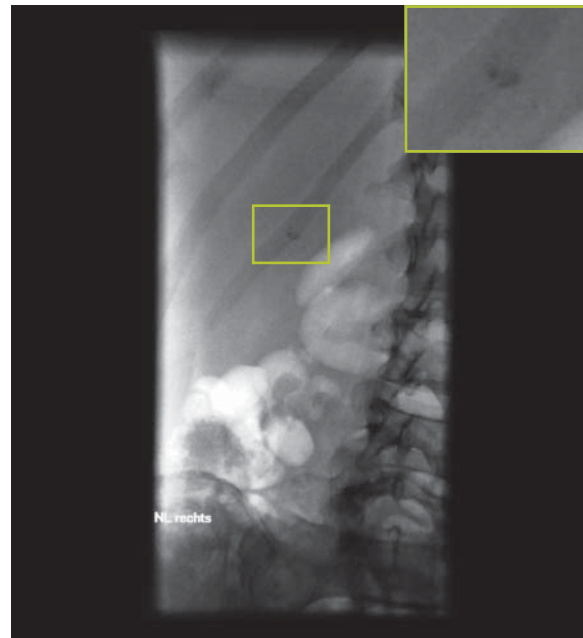
Selected SWL Cases on Siemens LITHOSKOP

Urology Department, Klinikum Harlaching
Teaching Hospital of the Ludwig-Maximilians-Universität Munich
Acting Chairman Dr. Stefan Thüroff

Small radio-opaque caliceal stone – localization with inline fluoroscopy



KUB pre SWL



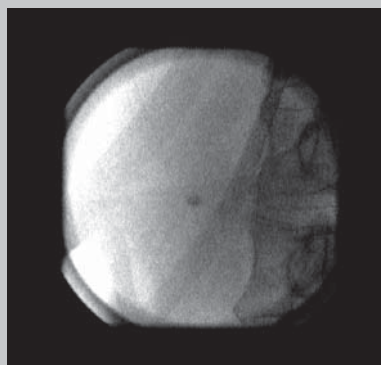
KUB (24 h) post SWL

Female patient (40 years) with small (5 mm) asymptomatic radio-opaque caliceal stone in the upper calix of right kidney

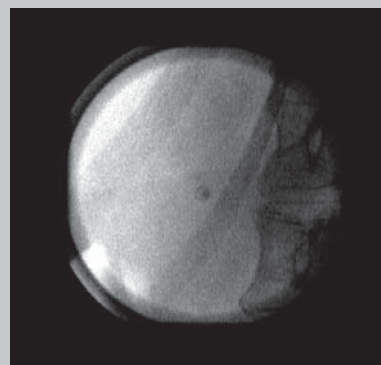
- URS left side one week ago
- patient preferred SWL for the therapy of the caliceal stone

Interposition of the twelfth rib occurred in this case when the shock wave system was positioned undertable (-40°).


Solution: Orbital movement of the shock wave system into -30° position in order to bypass the rib.



before SW*



after 500 SW*



after 2,300 SW*

SW-position:	undertable right (-30°)
SW-number:	2,300 SW
SW-frequency:	60 SW/min
Energy level (max):	2.5
Energy (total):	27 J
Duration of procedure:	45 min
X-ray:	1:41 min; 94 $\mu\text{Gy}/\text{m}^2$
Analgesia:	2.0 mg alfentanil

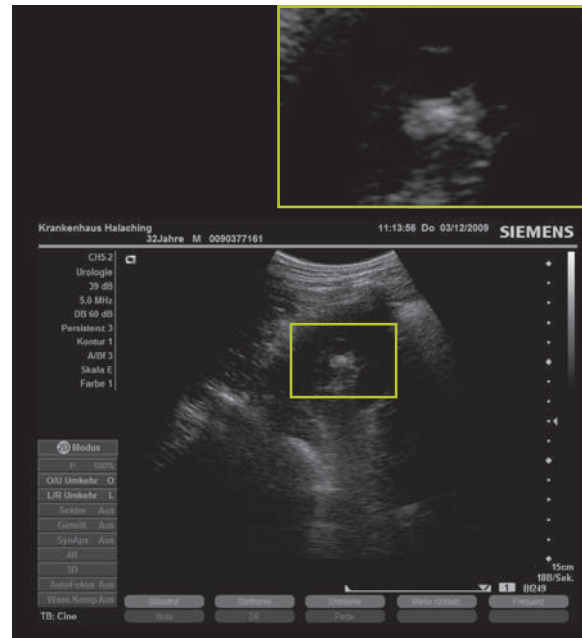
* Cross hair hidden to improve stone visibility

Small radiolucent caliceal stone – inline ultrasound localization

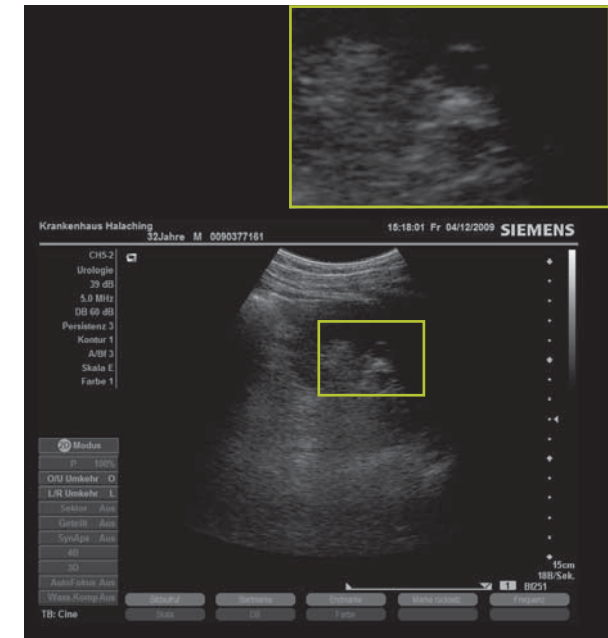
Male patient (32 years) with small (6 mm) radiolucent stone in the middle calix of left kidney

- recurrent hematuria and flank pain
- von Willebrand Jürgens Syndrom

Ultrasound guided SWL was performed with moderate shock wave parameters after normalization of coagulation (0.4 µg/kg desmopressin i.v.).

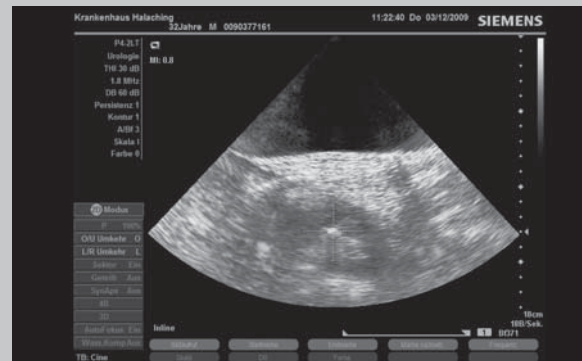

Ultrasound pre SWL

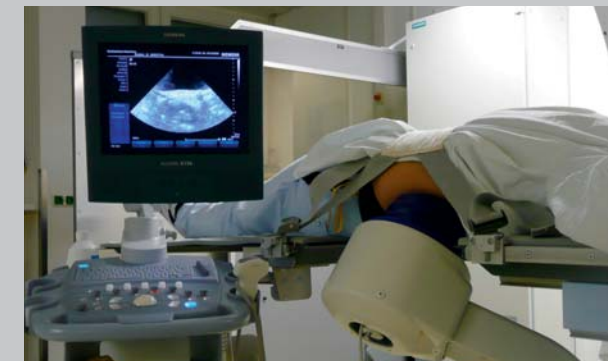

Ultrasound post SWL (24 hours)

SW-position:	undertable left (+40°)
SW-number:	2,000 SW
SW-frequency:	60 SW/min
Energy level (max):	2.5
Energy (total):	26 J
Duration of procedure:	42 min
X-ray:	0:08 min; 18 µGy/m ²
Analgesia:	2.0 mg alfentanil

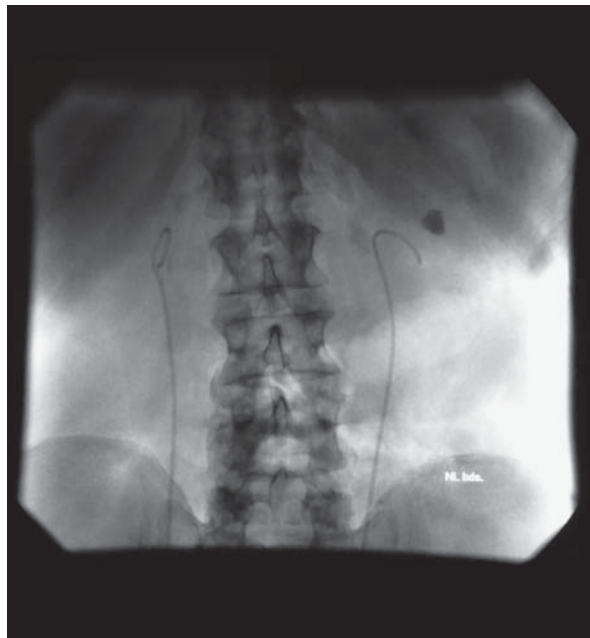


Inline ultrasound localization

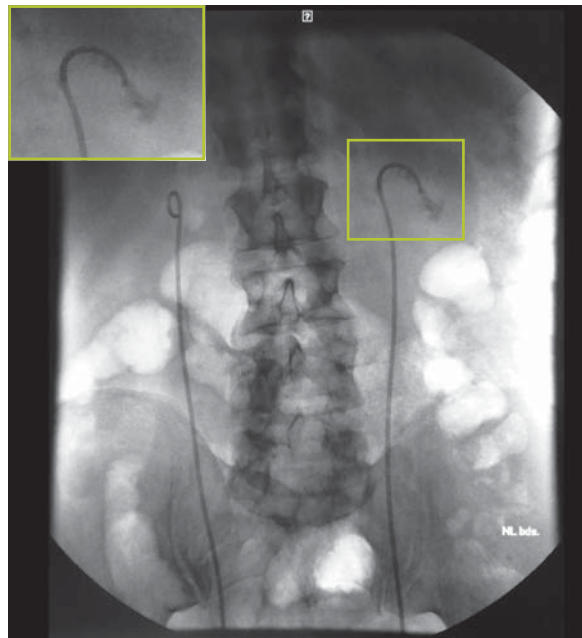


Shock wave system in undertable position with inserted ultrasound probe

Big renal stone – localization with inline fluoroscopy



KUB pre SWL

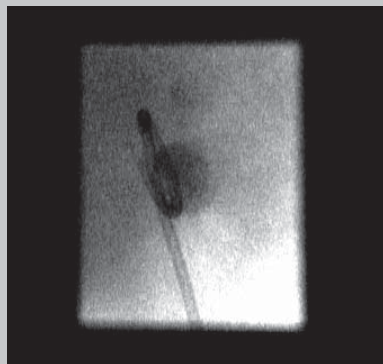


KUB (2 weeks) after first SWL

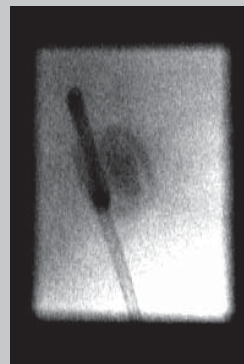Male patient (63 years) with big (18 mm) radio-opaque stone in the middle calyx of left kidney

- recurrent stone former
- M. Crohn
- JJ-stent before SWL

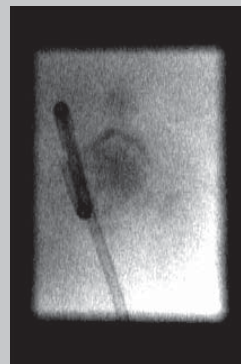Despite the big stone size, SWL was chosen due to the least invasive option for stone therapy and to the good susceptibility of calcium oxalate stones (M. Crohn) to SWL.



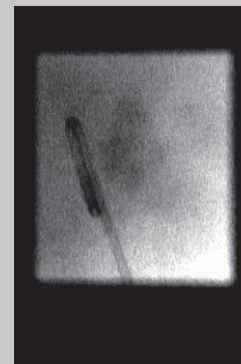
before SW*



after 500 SW*



after 2,000 SW*



after 3,000 SW*

SW-position:	undertable left (+40°)
SW-number:	3,000 SW
SW-frequency:	60 SW/min
Energy level (max):	3.2
Energy (total):	58 J
Duration of procedure:	55 min
X-ray:	1:25 min; 64 $\mu\text{Gy}/\text{m}^2$
Analgesia:	1.5 mg alfentanil

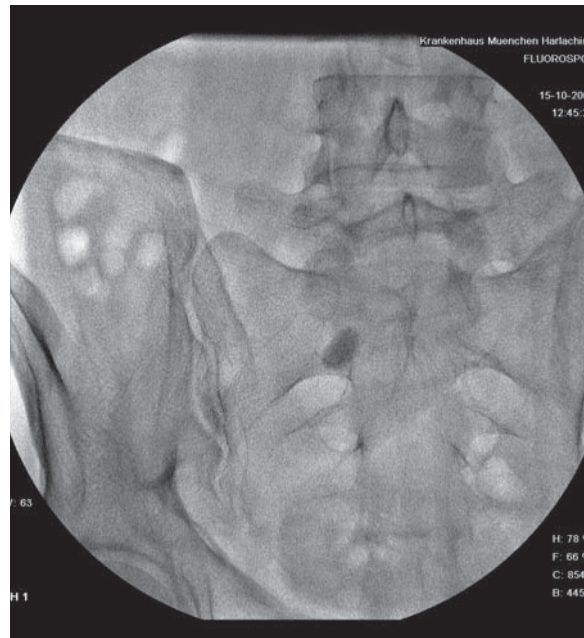
* Cross hair hidden to improve stone visibility

Big renal stone in anomalous kidney – localization with inline fluoroscopy

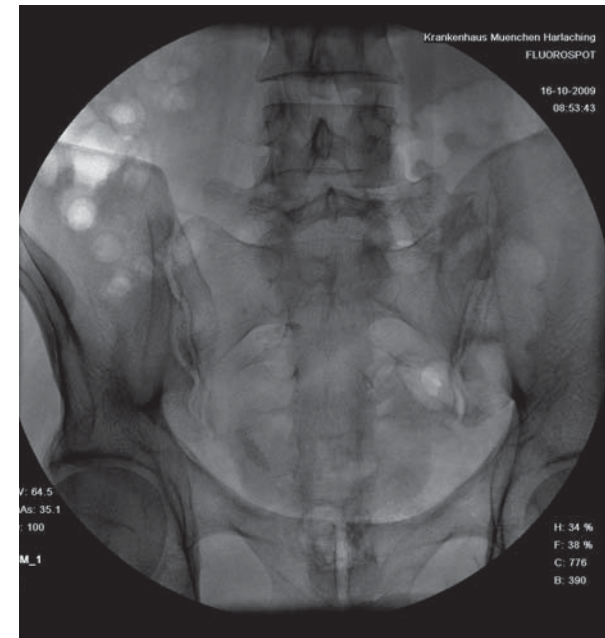
Male patient (52 years) with a big stone (15 mm) in the renal pelvis of an anomalous right kidney

- pelvic kidney with first presentation of stone

In this case the overtable position of the shock wave system was preferred to avoid an interposition of pelvic bone.

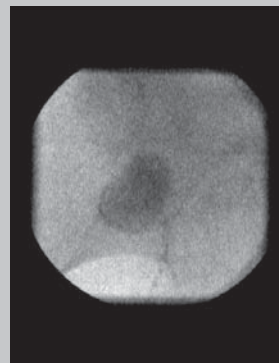


KUB pre SWL

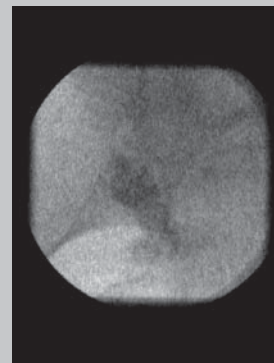


KUB (24 h) post SWL

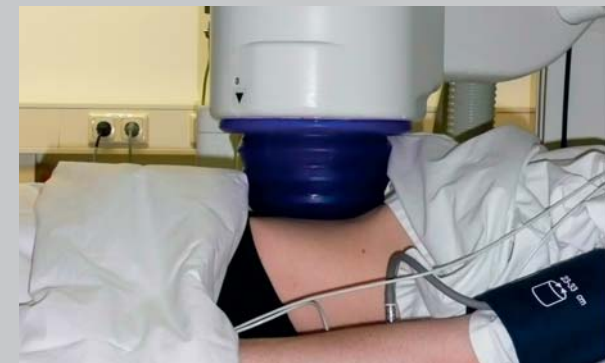SW-position:	overtable (+180°)
SW-number:	3,000 SW
SW-frequency:	60 SW/min
Energy level (max):	3.5
Energy (total):	64 J
Duration of procedure:	53 min
X-ray:	0:38 min; 55 $\mu\text{Gy}/\text{m}^2$
Analgesia:	1.5 mg alfentanil



before SW*



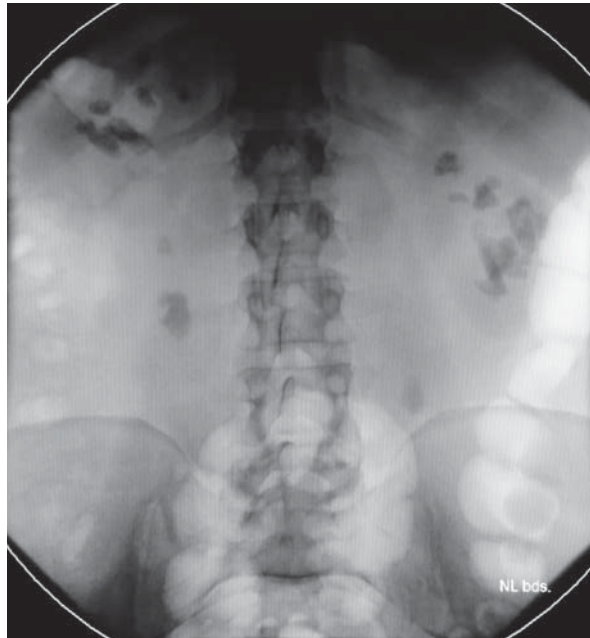after 3,000 SW*



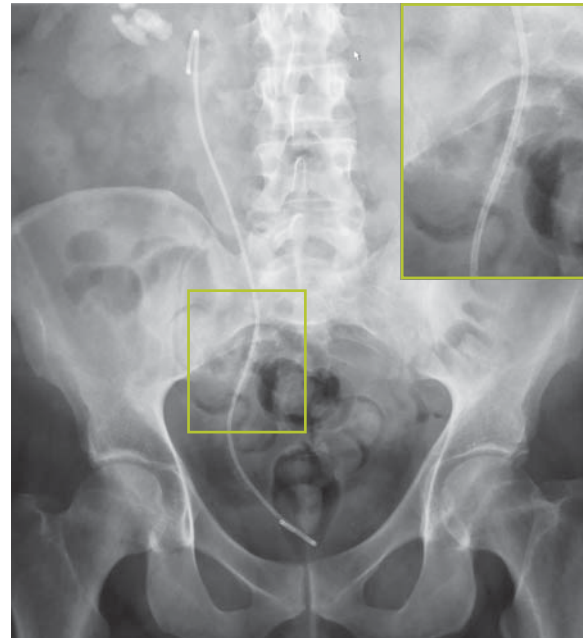
Shock wave system in overtable position

* Cross hair hidden to improve stone visibility

Huge ureteric stone – localization with inline fluoroscopy



KUB before JJ-stent and SWL

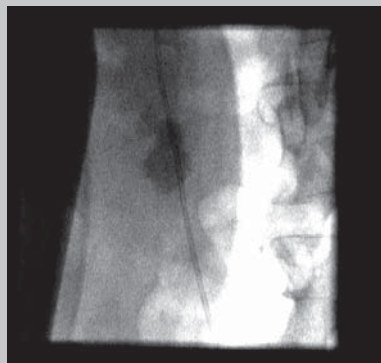


KUB (1 week) after JJ-insertion and first SWL

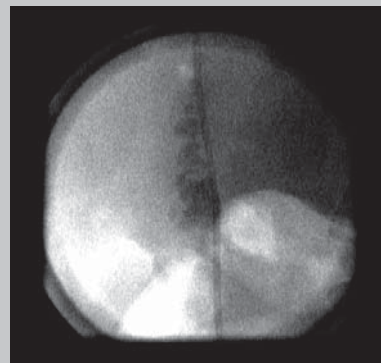
Male patient (31 years) with huge stone (25 mm) in the upper part of right ureter (in addition lumbar ureteric stone left and multiple bilateral renal stones)

- renal tubular acidosis (RTA I)
- recurrent stone former (>100 SWL and multiple URS in the last 25 years)
- hard stones (Brushit)

Because of elevated shock wave parameters and tolerance to opioids (>100 SWL procedures with i.v. analgesia) the patient required a high dosage of alfentanil.



before SW*



after 3,200 SW*

SW-position:	undertable right (-40°)
SW-number:	3,200 SW
SW-frequency:	90 SW/min
Energy level (max):	6.0
Energy (total):	128 J
Duration of procedure:	45 min
X-ray:	1:25 min; 120 µGy/m ²
Analgesia:	5.5 mg alfentanil

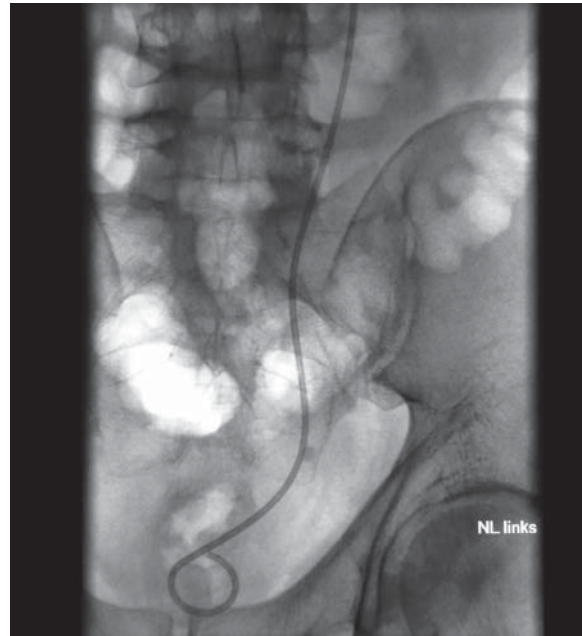
* Cross hair hidden to improve stone visibility

Small ureteric stone – localization with inline fluoroscopy

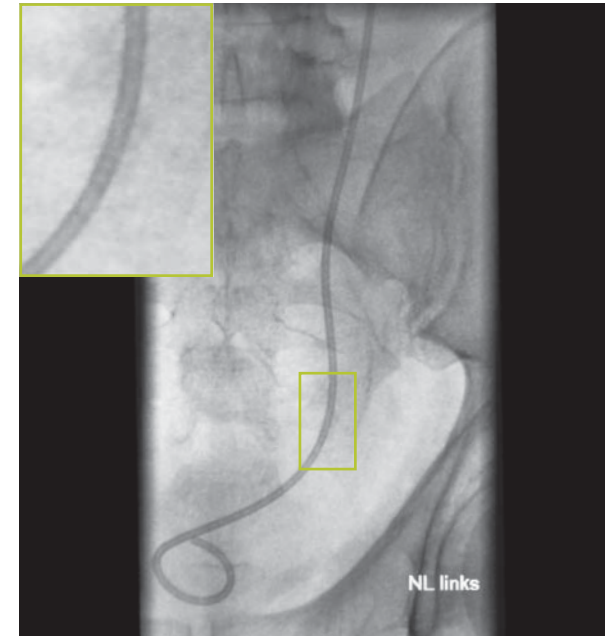
Male patient (42 years) with small (5 mm) stone in the lower part of left ureter

- insertion of JJ-stent because of renal failure (creatinine 1.8 mg/dl)

Treatment in overtable position reduces analgetic requirements (bypassing pelvic bone and sciatic nerve) and lowers radiation exposure in comparison to SWL in undertable position.



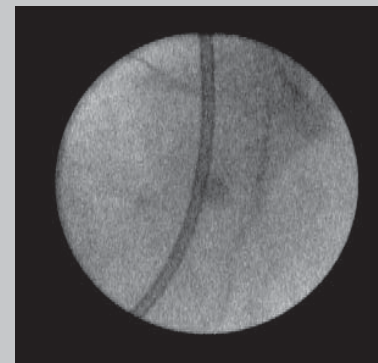
KUB pre SWL



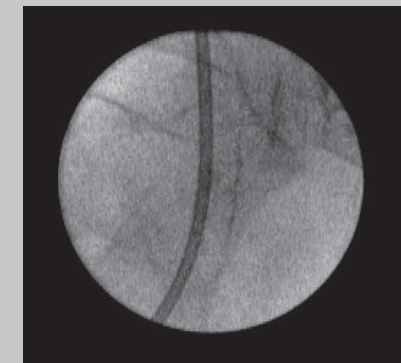
KUB (1 week) post SWL

SW-position:	overtable (180°)
SW-number:	4,000 SW
SW-frequency:	90 SW/min
Energy level (max):	5.0
Energy (total):	140 J
Duration of procedure:	50 min
X-ray:	0:55 min; 76 $\mu\text{Gy}/\text{m}^2$
Analgesia:	2.5 mg alfentanil

* Cross hair hidden to improve stone visibility

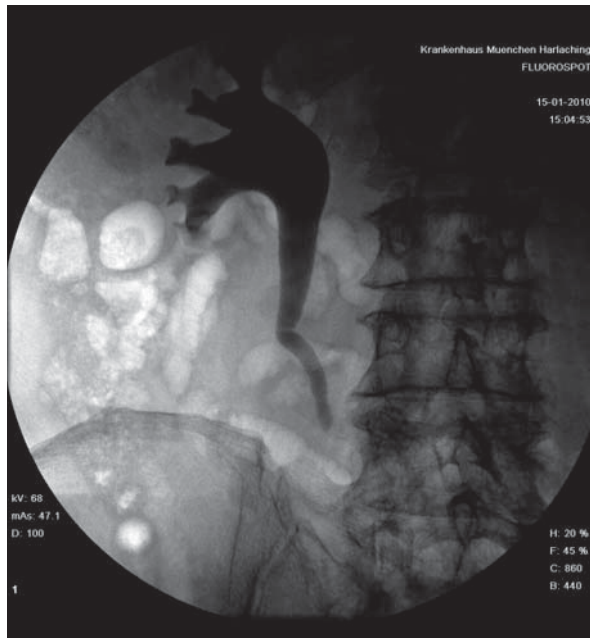


before SW*

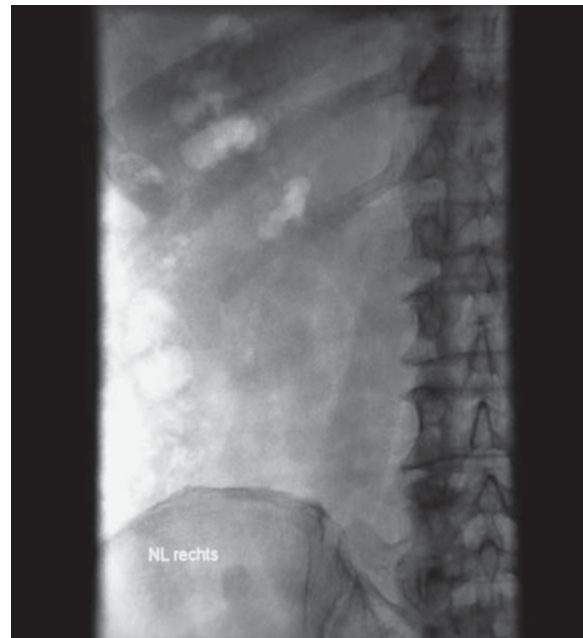


after 4,000 SW*

Ureteric stone – fluoroscopic localization (inline) with i.v. contrast



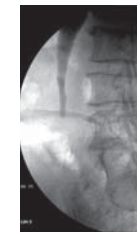
IVP pre SWL



KUB (24 h) post SWL

Male patient (72 years) with faint lumbar ureteric stone (10 mm) right side close to pelvic brim

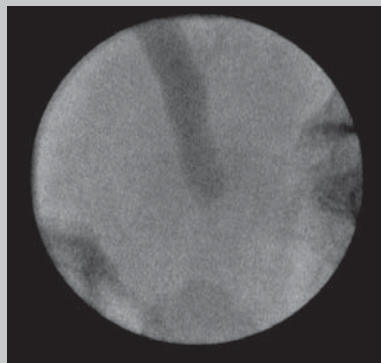
- intravenous pyelogram (IVP) on lithotripsy table before SWL



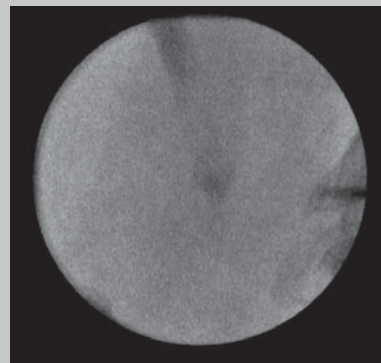
In undertable position (-40°) of shock wave source, the stone was located behind the pelvic bone.

Solution: SWL therapy in overtable position to avoid interposition of pelvic brim.


Inline fluoroscopy in undertable position



before SW*



after 1,500 SW*



after 3,000 SW*

SW-position:	overtable (180°)
SW-number:	3,000 SW
SW-frequency:	90 SW/min
Energy level (max):	4.0
Energy (total):	85 J
Duration of procedure:	50 min
X-ray:	2:38 min; 287 $\mu\text{Gy}/\text{m}^2$
Analgesia:	1.0 mg alfentanil

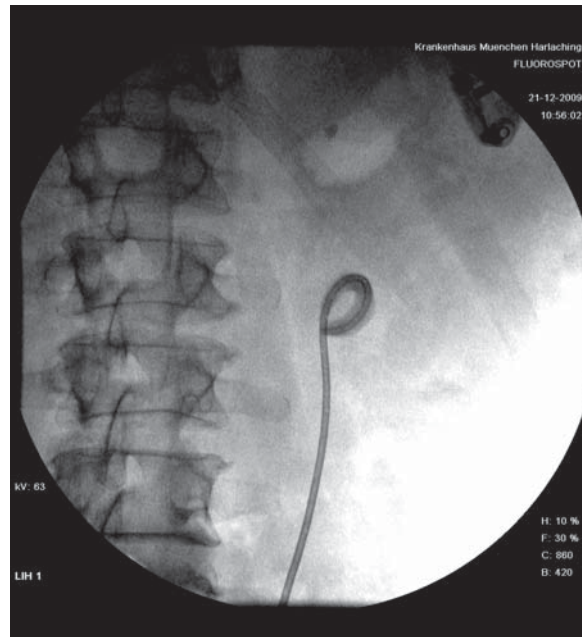
* Cross hair hidden to improve stone visibility

Calcified JJ-stent – localization with inline fluoroscopy

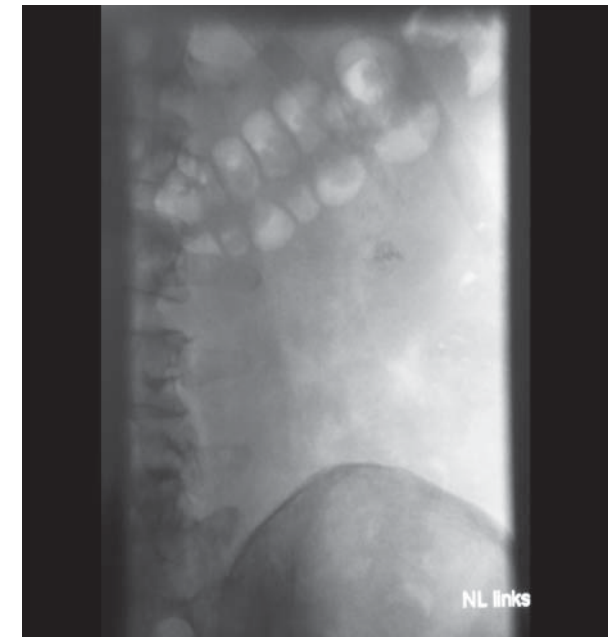
Male patient (54 years) with forgotten indwelling JJ-stent left side (for 12 months)

- frustrane attempt of endoscopic removal of calcified stent

In this case, the recommended energy levels for renal application were exceeded in order to fragment the massive calcification of the proximal loop (no evidence of renal hematoma in ultrasound control).

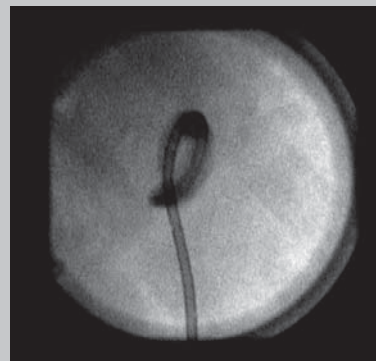


KUB pre SWL

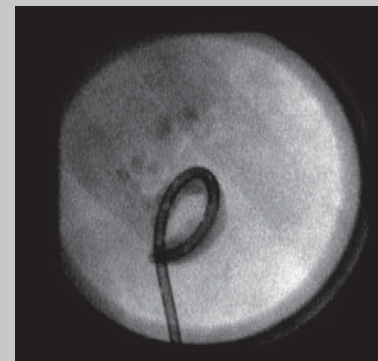


KUB (2 weeks) after 2nd SWL and JJ-stent extraction

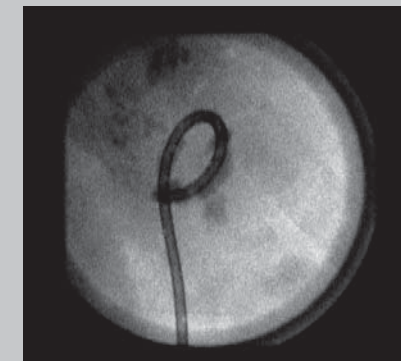SW-position:	undertable left (+40°)
SW-number:	3,500 SW
SW-frequency:	90 SW/min
Energy level (max):	4.5
Energy (total):	104 J
Duration of procedure:	48 min
X-ray:	1:30 min; 130 µGy/m ²
Analgesia:	2.0 mg alfentanil



before SW*



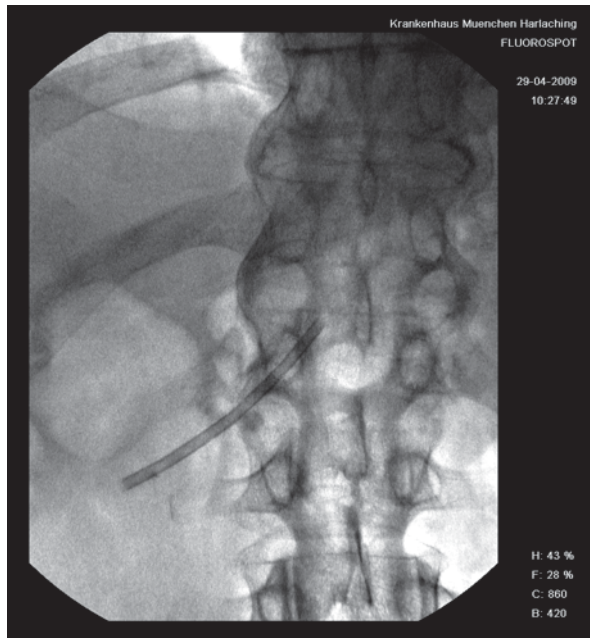
after 1,500 SW*



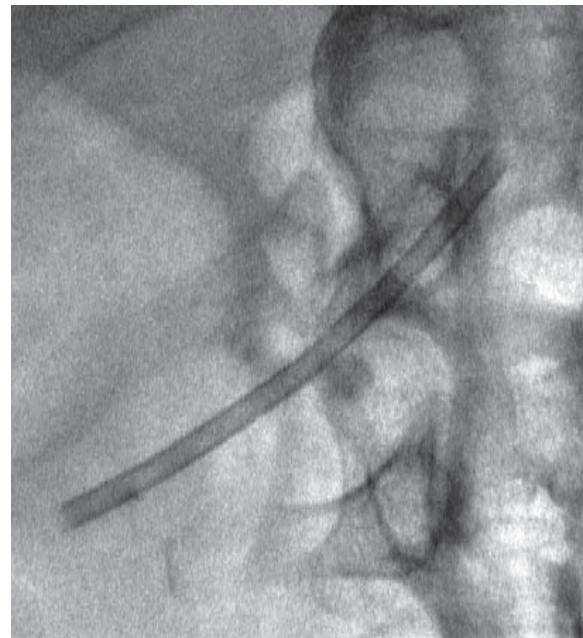
after 3,500 SW*

* Cross hair hidden to improve stone visibility

Pancreatic duct stone – localization with inline fluoroscopy



X-ray pre SWL

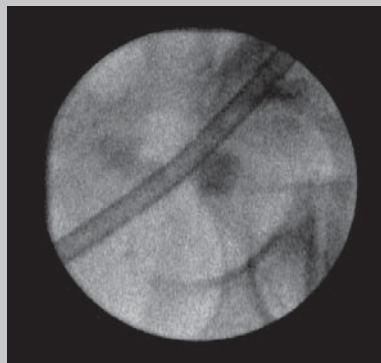

Enlarged detail of X-ray

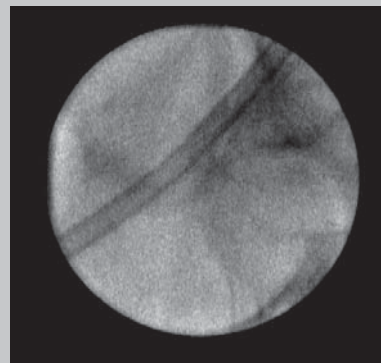
Male patient (54 years) with chronic pancreatitis and stone (10 mm) in pancreatic duct

- chronic pancreatitis
- frustrane attempt of endoscopic stone removal (ERCP)
- insertion of pancreatic drain

Two weeks after shock wave therapy the colleagues from the gastroenterology department removed the intrapancreatic drain and stone remnants by endoscopic means (ERCP).



before SW*



after 2,000 SW*

SW-position:	overtable (+180°)
SW-number:	2,000 SW
SW-frequency:	60 SW/min
Energy level (max):	3.5
Energy (total):	40 J
Duration of procedure:	48 min
X-ray:	1:35 min; 128 $\mu\text{Gy}/\text{m}^2$
Analgesia:	3.0 mg alfentanil

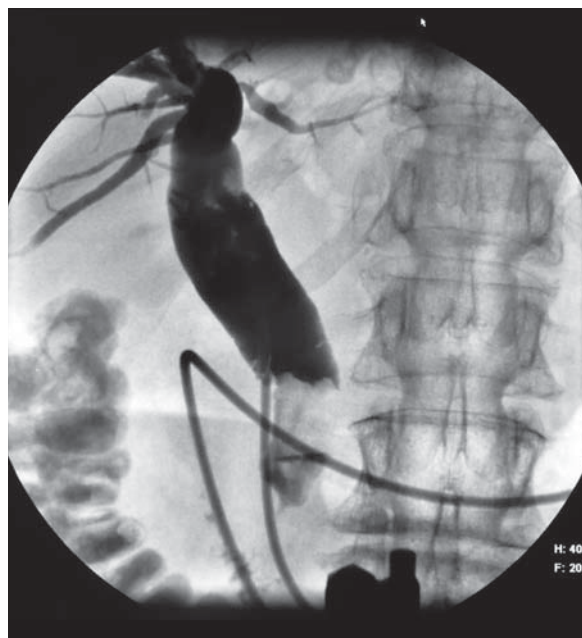
* Cross hair hidden to improve stone visibility

Biliary stone in ductus choledochus – localization with inline fluoroscopy

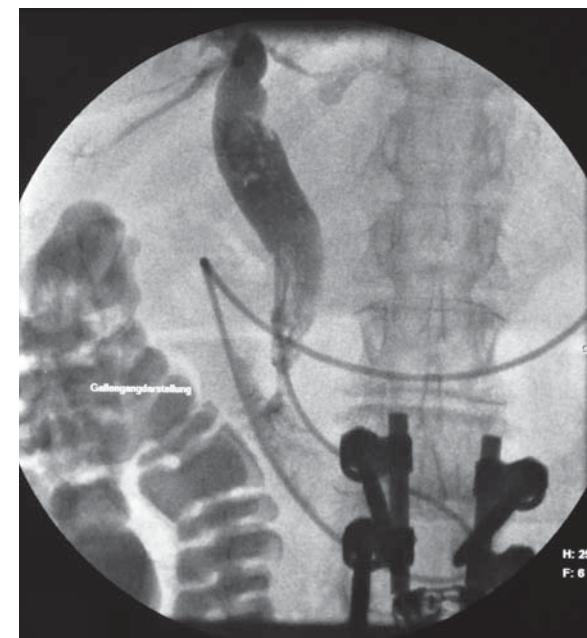
Female patient (80 years) with huge radiolucent stone in ductus choledochus (25 mm)

- nasobiliary probe
- spinal surgery (3 months ago)
- cholecystectomy (5 years ago)

SWL was chosen because this patient had a significant comorbidity.

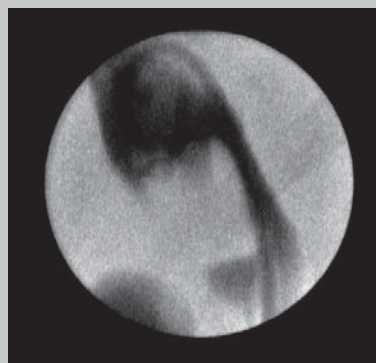


X-ray with antegrade contrast pre SWL

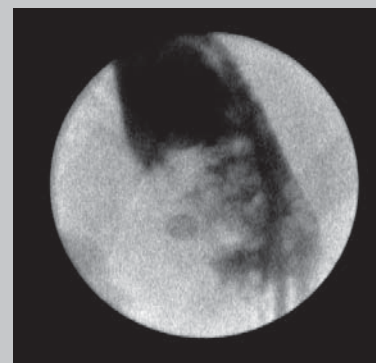


X-ray with antegrade contrast post SWL

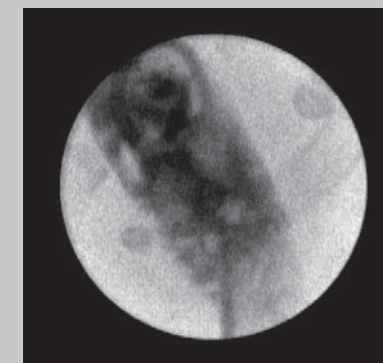
SW-position:	overtable (+180°)
SW-number:	3,000 SW
SW-frequency:	60 SW/min
Energy level (max):	4.2
Energy (total):	84 J
Duration of procedure:	57 min
X-ray:	4:06 min; 393 $\mu\text{Gy}/\text{m}^2$
Analgesia:	2.0 mg alfentanil



before SW*



after 1,500 SW*



after 3,000 SW*

* Cross hair hidden to improve stone visibility

> Klinikum Harlaching

Städtisches Klinikum München GmbH
Sanatoriumsplatz 2
81545 München
Telefon +49 (89) 6210-0
www.klinikum-muenchen.de

Copyright© 03.2010, Klinikum Harlaching, Städtisches Klinikum München GmbH
Order-No.: A91SU-10002-7C1-7600

