

# Enhanced Imaging in Electrophysiology

Interview from the customer magazine AXIOM Innovations, March 2008

[www.siemens.com/healthcare-magazine](http://www.siemens.com/healthcare-magazine)

**SIEMENS**



Treatment of complex arrhythmias is supported by 3D imaging. Until today, pre-procedural imaging with CT or MRI has been used to plan ablations of atrial fibrillation. With *syngo* DynaCT Cardiac, Siemens introduced new ways of 3D imaging. The acquisition and reconstruction of CT-like images directly in the cath lab just before the ablation is revolutionizing imaging in electrophysiology. AXIOM Innovations spoke with Professor Brachmann and Dr. Nölker from Klinikum Coburg.

## Enhanced Imaging in Electrophysiology

Prof. Brachmann, Dr. Nölker, the Klinikum Coburg has offered ablation therapy for complex arrhythmias for almost ten years, and your department for electrophysiology (EP) is expanding. In May 2007, an Artis system with *syngo* DynaCT Cardiac was installed in your institution. Why did the hospital decide on this new way of imaging in EP?

**Prof. Brachmann** Electrophysiology is a growing therapeutic field. The treatment on atrial fibrillation (AF) is of major interest. Finally some years ago, treatment techniques were established for this complex arrhythmia and we are seeing a stabilization of the success rate. This is not only due to the guidelines published by the HRS at the end of 2006 and the studies of ablation therapy versus medical treatment of AF patients and patients with heart insufficiencies. Here in Coburg

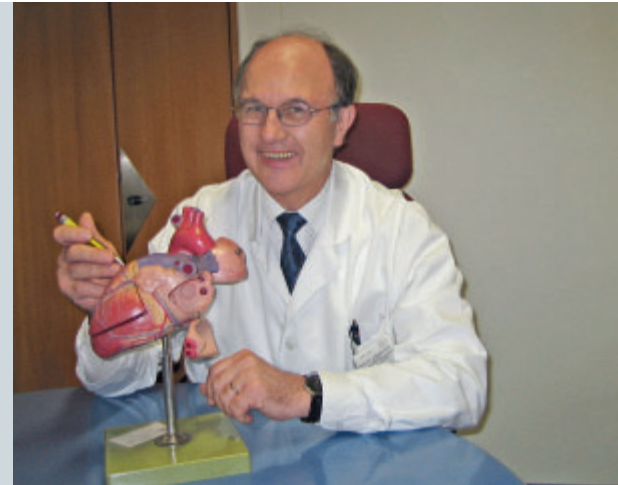we recently initiated the CASTLE AF study in cooperation with the University of Utah in Salt Lake City, USA. First results indicate that the importance of ablations for therapy of AF will grow.

**So you expect to treat more patients with ablation therapy in the future?**

**Prof. Brachmann** Yes, we expect an increasing patient load with AF in the future. Therefore we wanted to set up our hospital to treat on a high technical level. It became obvious during the recent years that the quality and the possibilities of imaging are key for efficient therapy. We are convinced that *syngo* DynaCT Cardiac is adding an essential new functionality to imaging and helps to improve the quality of intra-procedural imaging. Besides greater efficiency, we expect to increase the safety of proce-

“We are convinced that *syngo* DynaCT Cardiac is adding an essential new functionality to imaging and helps to improve the quality of intra-procedural imaging.”

Prof. J. Brachmann, Department of Electrophysiology, Klinikum Coburg, Germany



dures with *syngo* DynaCT Cardiac, due to the improved information on cardiac structures and the surrounding anatomy. The guidance of the ablation catheters can be facilitated through intra-procedural 3D imaging techniques like *syngo* DynaCT Cardiac or intravascular ultrasound (ICE).

#### How do you think you will increase the efficiency of your procedures with *syngo* DynaCT Cardiac?

**Dr. Nölker** For me, there are different components of efficiency: procedure time, effectiveness and safety. So far realtime imaging has been possible only in 2D with fluoroscopy and intracardiac echo (ICE). Now there is *syngo* DynaCT Cardiac, which can be combined with fluoroscopy. In my opinion the intra-procedural fusion of 2D and 3D is the actual innovation as it will lead us to more innovation: it provides greater accuracy and thus higher efficiency. We are currently using *syngo* DynaCT Cardiac as an add-on to compare its feasibility with it to conventional imaging techniques. In our abstract entitled “Three-dimensional Left Atrial And Esophagus Reconstruction Using Cardiac C-arm Computed Tomography For Ablation Of Atrial Fibrillation: Preliminary Experience” presented at AHA 2007, we came to the conclusion that *syngo* DynaCT Cardiac

seems to provide a feasible and reliable left atrial oesophagus image to help mapping and navigation during the PVAI (Circulation 2007; 116:II\_365, Abstract 1732).

#### How do you perform ablations of atrial fibrillation in your department? What kind of imaging techniques did you use before the installation of *syngo* DynaCT Cardiac?

**Dr. Nölker** Before the installation of *syngo* DynaCT Cardiac we performed pulmonary vein isolations (PVI) guided by ICE, fluoroscopy and lasso catheter. Prior to the installation of *syngo* DynaCT Cardiac, we relied on pre-procedural CT images segmented with *syngo* InSpace EP to plan the procedure. This already was helpful. We think that 3D information of the cardiac anatomy is crucial to improve the ablation.

#### And what is your approach to isolating of the pulmonary veins?


**Prof. Brachmann** Our approach for ablation of AF is PV LA junction isolation, an anatomy-based PV antrum isolation combined with electrical guided confirmation. All four pulmonary veins are completely isolated as required and in accordance with the AXIOM Sensis XP recordings.

#### Currently you use *syngo* DynaCT Cardiac mainly in AF therapy. Could you describe the workflow used to implement intra-procedural 3D imaging in these procedures?

**Dr. Nölker** We now start the procedure with rotational angiography to create a *syngo* DynaCT image of the patient’s heart. During the rotation we inject about 100 ml of contrast medium right in the pulmonary artery. The acquired projections are automatically transferred to the *syngo* workplace for the 3D reconstruction, and the reconstructed image pops up on the monitor a few seconds later. Usually, I then segment the left atrium with the convenient segmentation tool, *syngo* InSpace EP. If we also gave the patient some barium to swallow, I can segment the esophageous. I then rotate the extracted 3D structures around to get an understanding of the patient’s pulmonary vein structure. Sometimes I also use the endoscopic view to see the relation of the PV ostia and the appendage. Then we overlay live fluoroscopy and the 3D segmentation to guide the positioning of the ablation catheters. As the 3D image was acquired on the same system as the fluoroscopy, we do not need time-consuming registration. Only if the patient

“Additional to this, *syngo* DynaCT Cardiac is extremely helpful for education to shorten learning curves.”

Dr. G. Nölker, Department of Electrophysiology, Klinikum Coburg, Germany



moved after the rotational run, we have to adjust the overlay a little bit, but this is quickly done by a kind of manual drag and drop. The 2D/3D fusion makes the orientation during mapping and ablation much easier.

#### What are the main advantages of *syngo* DynaCT Cardiac?

**Prof. Brachmann** *syngo* DynaCT Cardiac provides a real-time 3D dataset of the heart that can be related to the left atria, pulmonaries, coronary sinus, etc. This

can be integrated with *syngo* iPilot as 2D-3D overlay with the actual fluoroscopic images in various projections. The esophagus can also be displayed to reduce the risk of esophagus fistula.

**Dr. Nölker** There are various ways to use *syngo* DynaCT Cardiac for navigation besides the left atrium, like navigation for tachycardias originating from the aortic cusps.

In addition, *syngo* DynaCT Cardiac is extremely helpful for education to shorten learning curves. The 3D visualization supports the understanding of the anatomy and helps for orientation as we witnessed in training our colleagues.

#### Where do you see this innovative 3D imaging technique headed? What future applications could you imagine?

**Prof. Brachmann** Beside visualization of the atria in 3D, we also aim for 3D imaging of other structures like the coronary sinus in CRT (cardiac resynchronization-therapy).

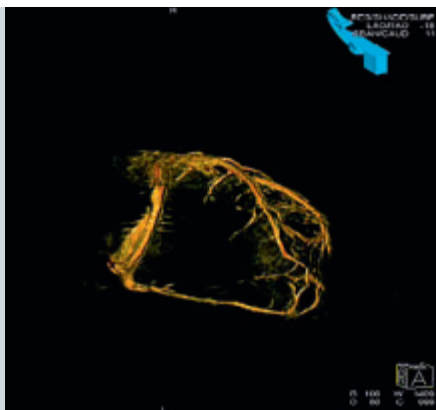
The additional feature of ECG-triggered acquisition and reconstruction with *syngo* DynaCT Cardiac is currently under investigation in our institution. This should further enhance the quality of the images and allow for more de-

tailed analysis of cardiac structures, e.g. for other procedures in interventional cardiology.

The development of cardiac imaging has been continuously improving both efficiency and safety of cardiac procedures. In particular, 3D imaging has been very helpful, thus the advantages now obvious with the 2D/3D fusion function of *syngo* iPilot and *syngo* DynaCT Cardiac. I think we are just beginning to develop applications with *syngo* DynaCT Cardiac but I see a promising future.

#### References

Georg Nölker, Johannes Brachmann et al. Three-dimensional Left Atrial And Oesophagus Reconstruction Using Cardiac C-arm Computed Tomography For Ablation Of Atrial Fibrillation: Preliminary Experience In Circulation 2007;116: II\_365.



3D visualization of coronary sinus with *syngo* DynaCT Cardiac, Courtesy of Klinikum Coburg

#### Contact

dirk.sunderbrink@siemens.com

# AXIOM Innovations - Imprint

© 2008 by Siemens AG, Berlin and Munich, All Rights Reserved

## Publisher

Siemens AG  
Medical Solutions  
Angiography, Fluoroscopic  
and Radiographic Systems  
Siemensstr. 1,  
91301 Forchheim, Germany

## Responsible for contents

Norbert Gaus, PhD

## Chief editor

Sabine Wich  
sabine.wich@siemens.com

## Editorial board

Andrea Beulcke  
Monika Böhmer  
Vera Jünnemann  
Oliver Meissner, MD  
Andrea Müller  
Roland Papenfuß  
Siegfried Prell  
Kristina Seel  
Susanne Seah

## Contributors to this issue

Martin von Roden, Michael Pflaum,  
Dirk Sunderbrink, Dominique  
Sandner-Porkristl, Alois Poslusny,  
David Boom

All at Siemens AG Medical Solutions

G. Bongartz, MD  
T. Niemann, MD  
University Hospital Basel  
Basel, Switzerland

Winanda Buijserd-van Nifterik  
Hans Biemans, MD  
Beatrix Hospital  
Gorinchem, The Netherlands

Johannes Brachmann, MD  
Georg Nölker, MD  
Klinikum Coburg  
Coburg, Germany

Arnd Dörfler, MD  
Tobias Stuffert, MD  
Gregor Richter, MD  
University of Erlangen-Nuremberg  
Erlangen, Germany

Anieke Eikelenboom  
Academic Medical Center Amsterdam,  
The Netherlands

Dietmar Glogar, MD  
Allgemeines Krankenhaus (AKH)  
Vienna, Austria

Hsien-Li Paul Kao, MD  
National Taiwan University Hospital  
Taipei, Taiwan

Wolfgang Kumpan, MD  
Kaiser Franz Josef Hospital Vienna,  
Austria

Yvan Palmers, MD  
Ben Welckenhuyzen  
Ziekenhuis Oost-Limburg  
Genk, Belgium

Dae Chul Suh, MD  
Asan Medical Center  
University of Ulsan  
Seoul, South Korea

Maximilian Reiser, MD  
Christoph Becker, MD  
Tobias Waggerhauser, MD  
University of Munich  
Munich, Germany

## Production

Michael Brumme  
Siemens Medical Solutions

## Layout and editorial staff

Satzwerker – Jäger & Tuppi  
Nuremberg/Karlsruhe, Germany

## Pre Press

MEDIA\_asset\_pool  
Waldstraße 18  
91054 Erlangen, Germany

## Printer

Farbendruck Hofmann  
Gewerbestraße 5  
90579 Langenzenn, Germany

## AXIOM Innovations on the net:

[www.siemens.com/healthcare-magazine](http://www.siemens.com/healthcare-magazine)

Note in accordance with § 33 Para.1 of the Federal Data Protection Law: Dispatch is made using an address file which is maintained with the aid of an automated data processing system. We remind our readers that, when printed, X-ray films never disclose all the information content of the original. Artifacts in X-ray, CT, MR and ultrasound images are recognizable by their typical features and are generally distinguishable from existing pathology.

As referenced above, healthcare practitioners are expected to utilize their own learning, training and expertise in evaluating images.

Partial reproduction in printed form of individual contributions is permitted, provided the customary bibliographical data such as author's name and title of the contribution as well as date and pages of "AXIOM Innovations" are named. The editors

request that two copies be sent to their attention. The consent of the authors and editors is required for the complete reprint of an article.

Manuscripts submitted without prior agreement as well as suggestions, proposals and information are always welcome; they will be carefully assessed and submitted to the editorial conference for attention.