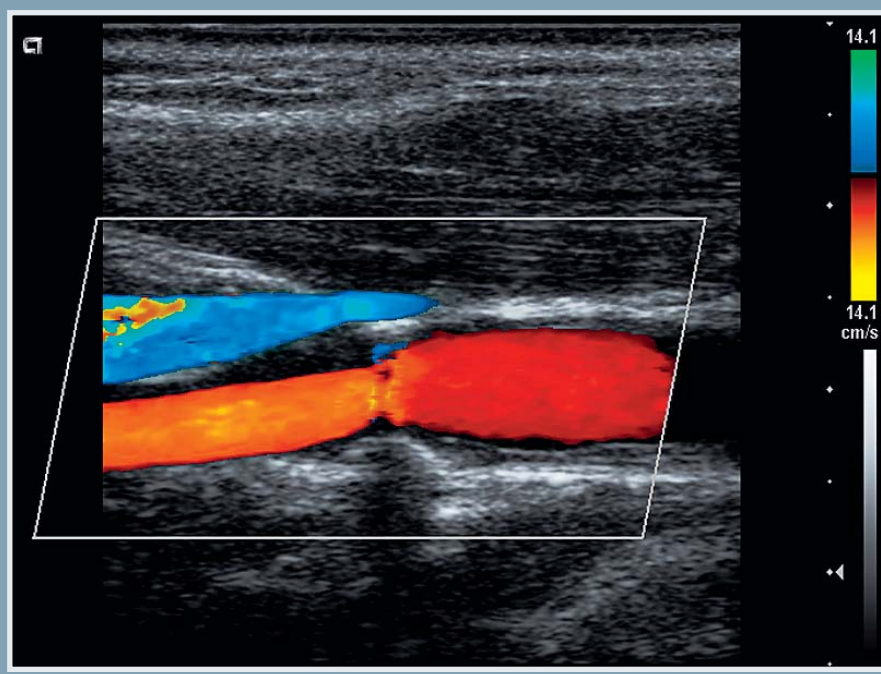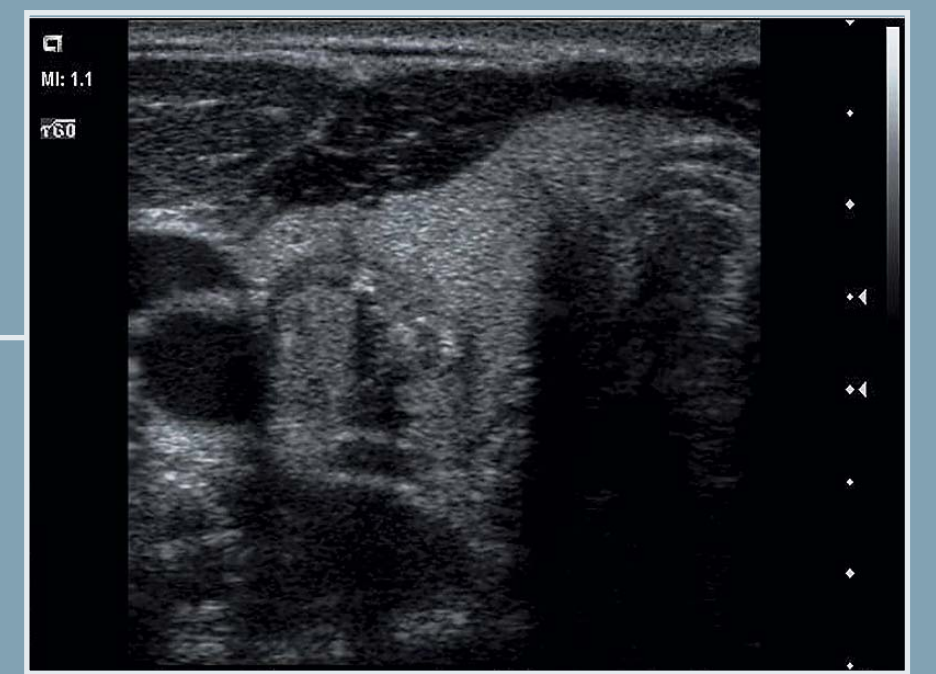
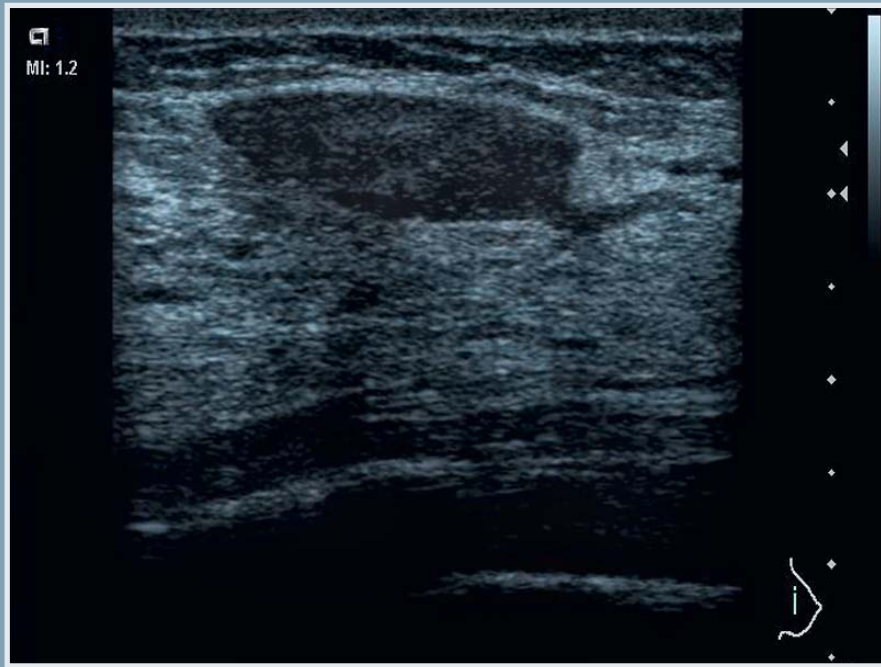


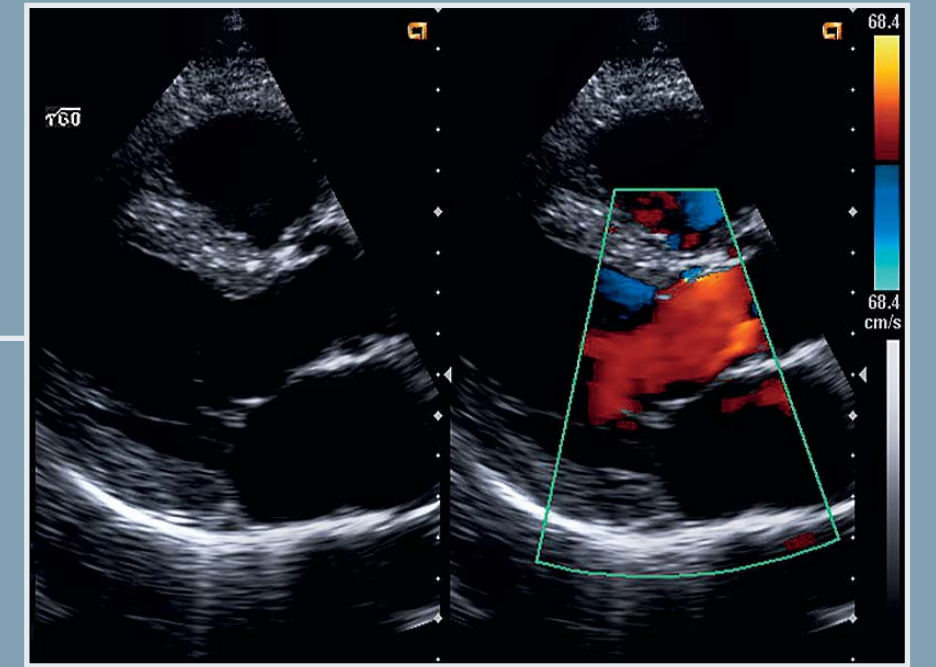
Plaque in Carotid Bulb



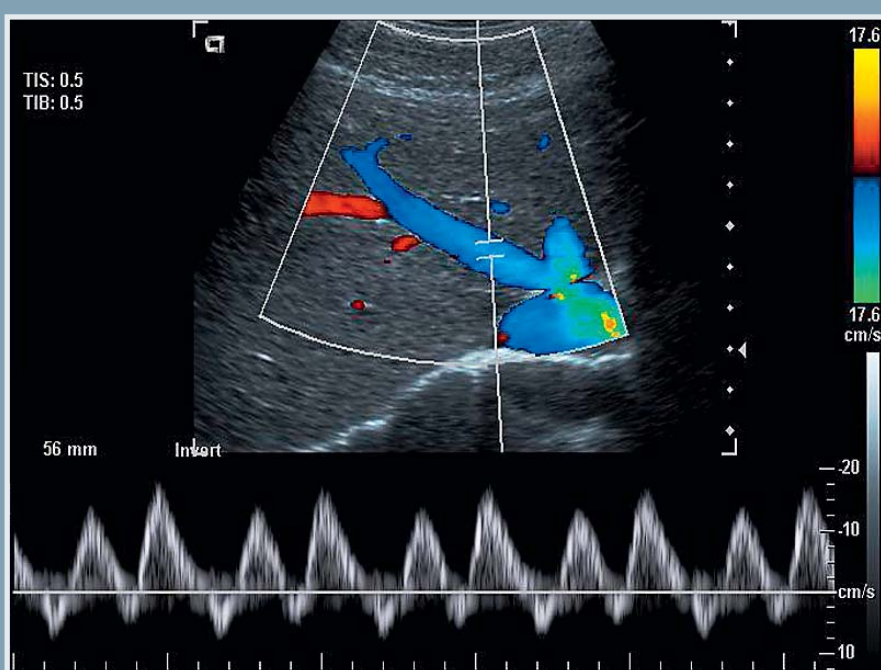
Solid Mass – Right Lobe Thyroid



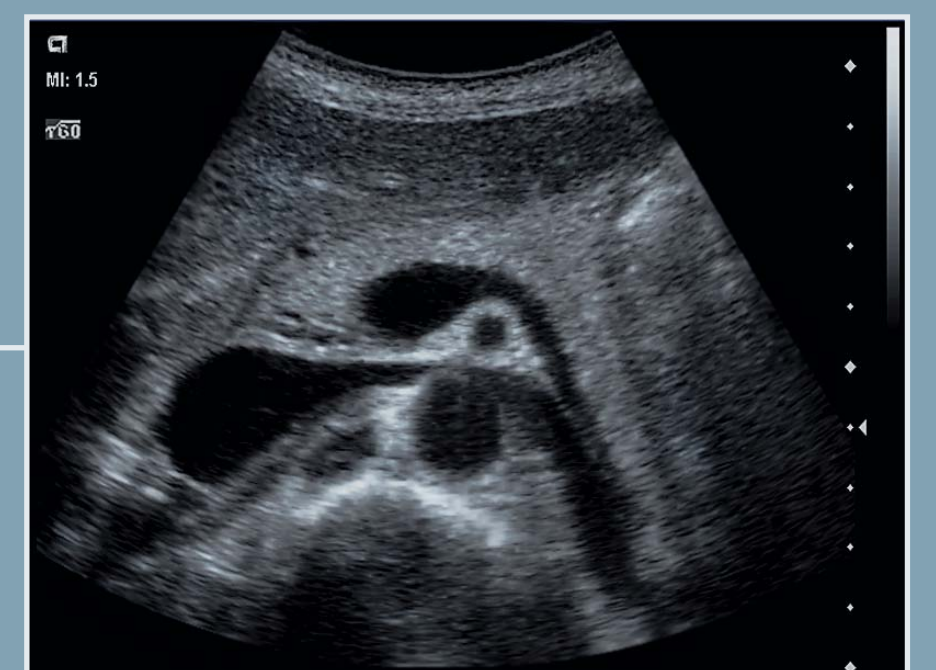Solid Breast Mass



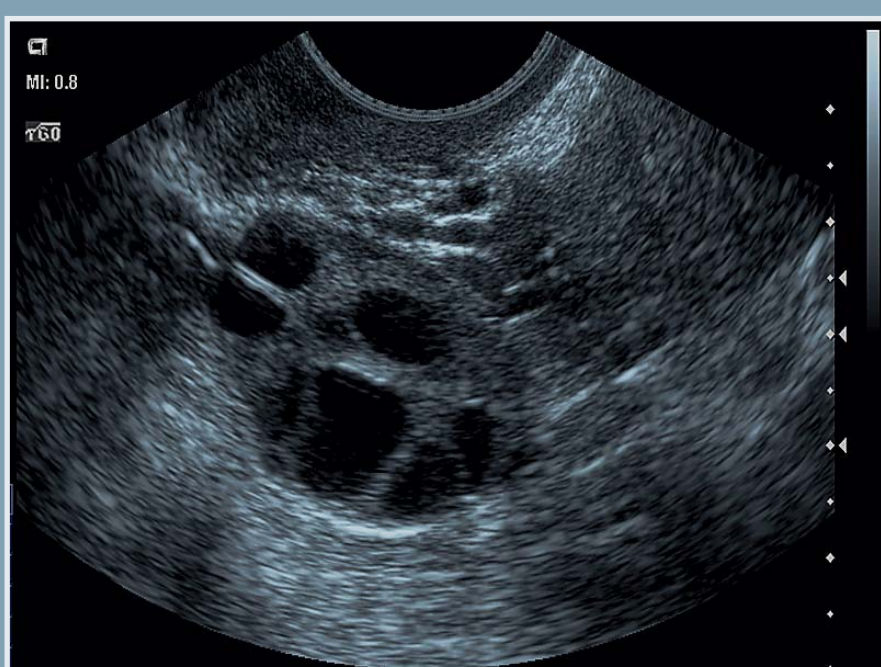Color Doppler across the Aortic Valve



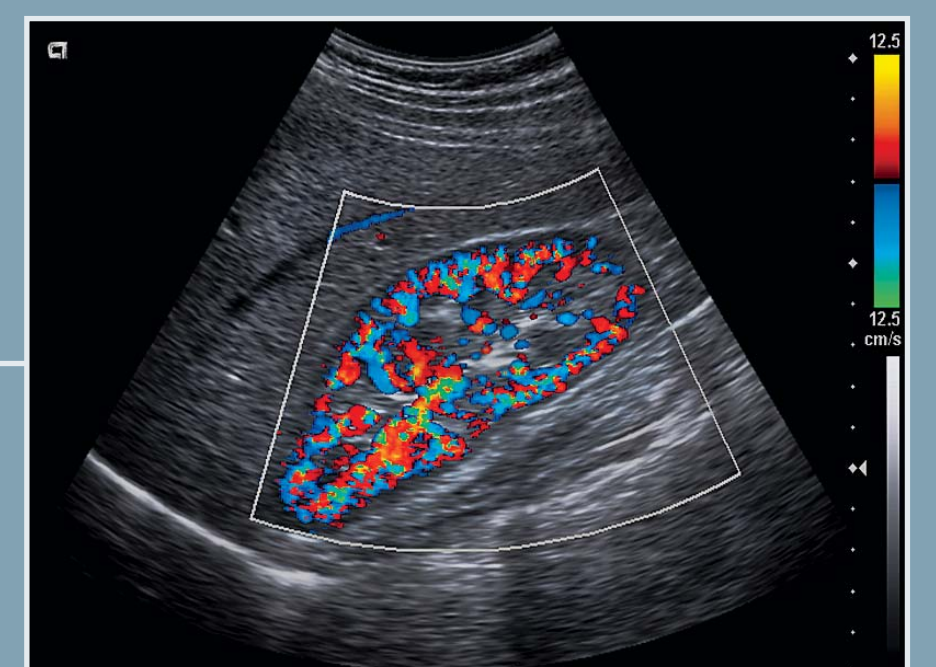Hepatic Vein Flow



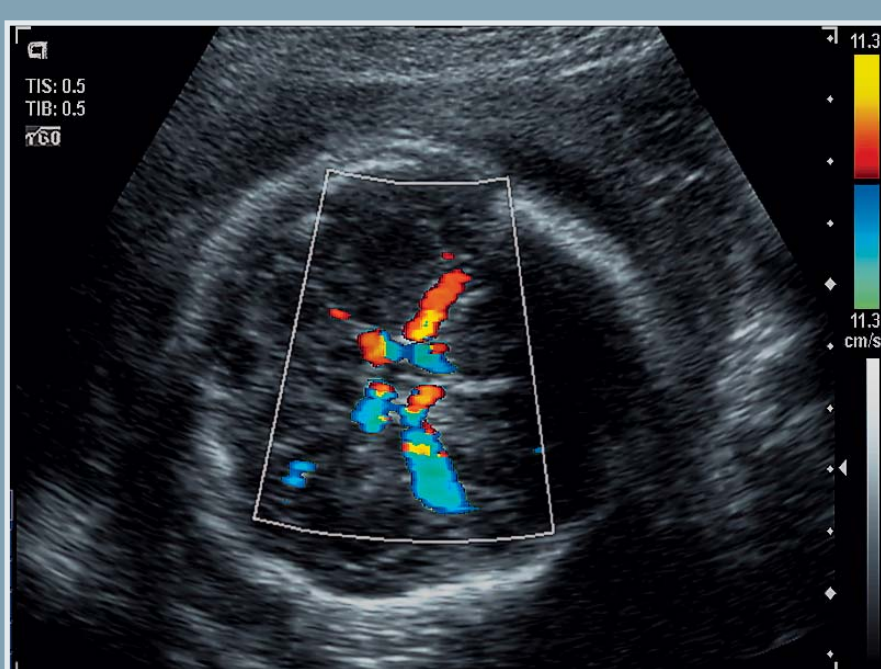
Pancreas / Midline Abdominal Vasculature



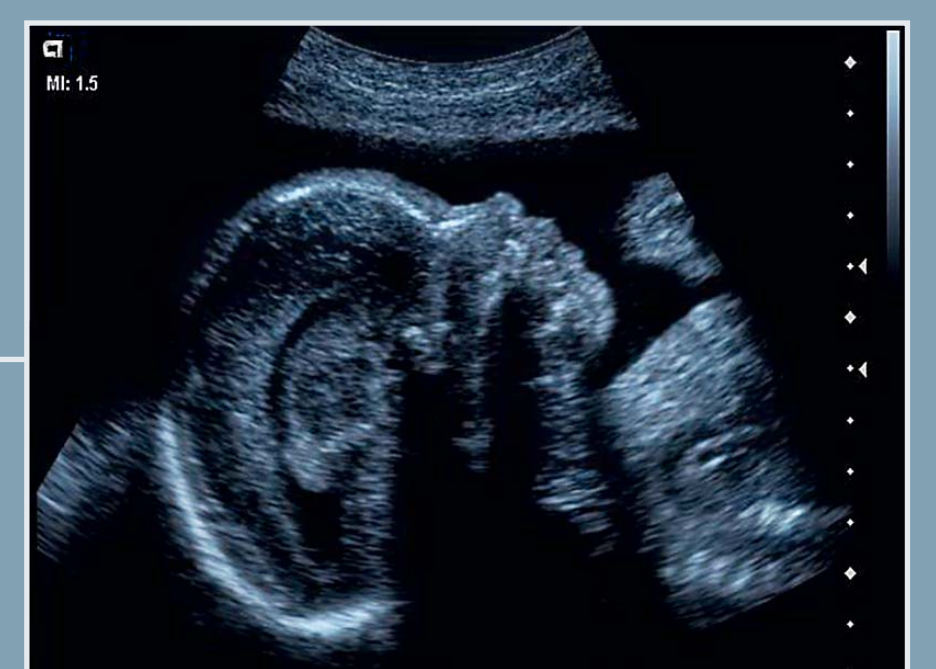
Multiple Ovarian Follicles



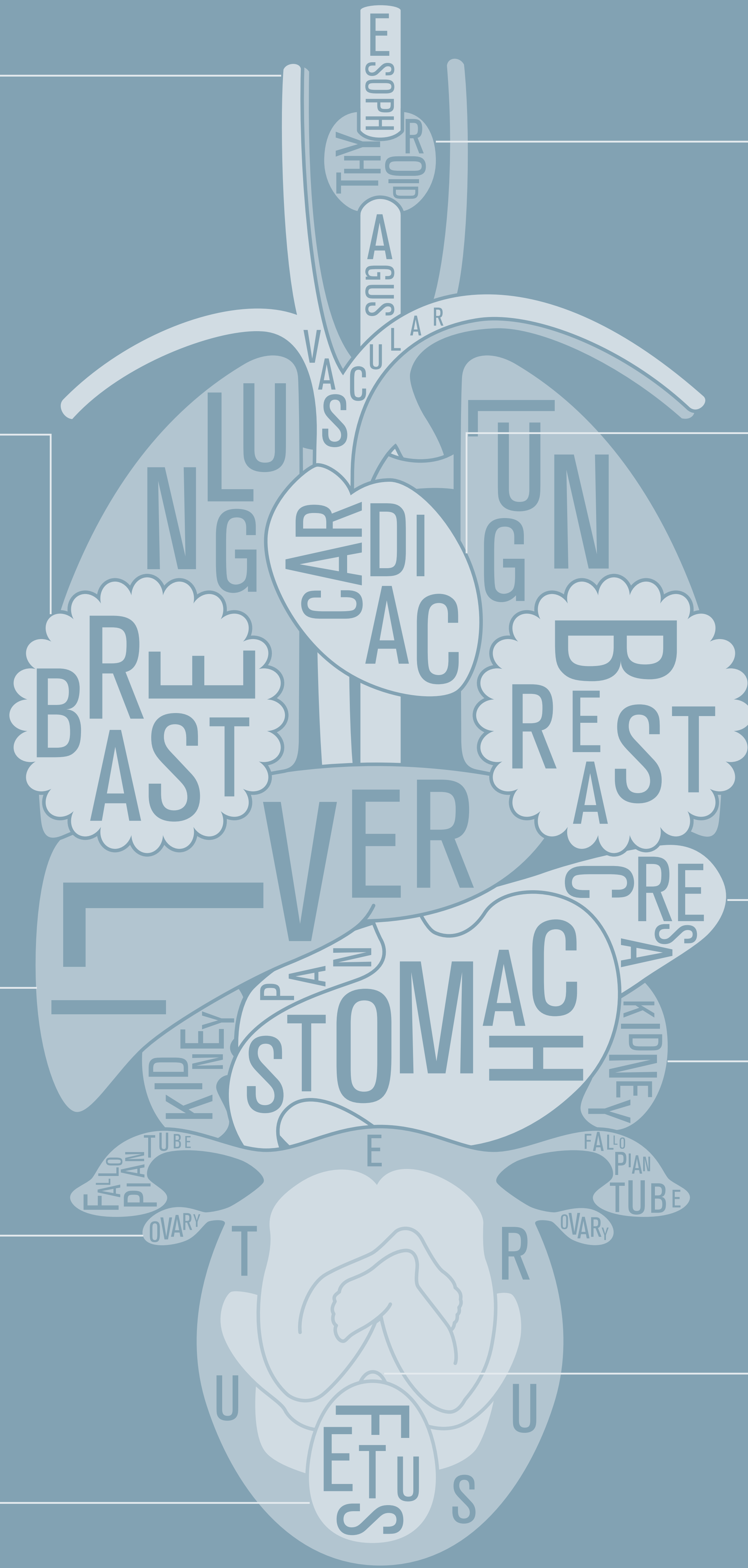Color Doppler of Renal Vasculature



Circle of Willis – 27 Week Fetus



Fetal Profile – 27 Weeks



# THE ART OF ULTRASOUND

Beautiful Images. Diagnostic Confidence. Better Patient Care.

ACUSON X150™ Ultrasound System

[www.siemens.com/healthcare](http://www.siemens.com/healthcare)

**SIEMENS**