Acute Occlusion of the Basilar Artery

Noninvasive therapy planning in neuroradiology using the SOMATOM Sensation 64 CT scanner.

By Birgit Ertl-Wagner, M.D., Institute of Clinical Radiology, Roland Bruening, M.D., Department of Neuroradiology, University of Munich – Klinikum Grosshadern, Munich, Germany, and Sieglinde Scheuerer, CT Application Consultant, Siemens Medical Solutions

History

An 89-year-old man was presented to the hospital in a comatose state with signs and symptoms of hind circulation ischemia. The normal basilar artery imaged on plain CT scans has an attenuation value not higher than that of whole blood. Therefore a CT angiography with the Siemens SOMATOM Sensation 64 CT Scanner was performed to evaluate the patient for occlusion of the basilar artery.

Discussion and Comments

The CT angiography of the neurovascular system revealed a complete occlusion of the basilar artery in the mid-basilar section. The occlusion spans a length of 9 mm. The cranial part of the basilar artery and the superior cerebellar arteries demonstrate a retrograde perfusion via the collateral circulation of the circle of Willis. The right posterior inferior cerebellar artery is perfused via an antegrade flow, while the left posterior inferior cerebellar artery and the anterior inferior cerebellar arteries appear occluded.

This case illustrates the potential of 64-slice CT angiography in the diagnostic evaluation of hind circulation ischemia. 64-slice CT angiography is now able to clearly visualize both the site and the length of the thrombotic occlusion of the basilar artery. Moreover, the extent of collateralization and the degree of retrograde perfusion of the cranial part of the basilar artery and of the cerebellar arteries can be meticulously evaluated. This enables a thorough noninvasive preinterventional workup and precise therapeutic decision making.

Examination Protocol

SCANNER	SOMATOM Sensation 64	**TABLE FEED / ROTATION**	23 mm
SCAN AREA	From base of scull to cap	**RECONSTRUCTION INCREMENT**	0.4 mm
SCAN LENGTH	15 cm	**KERNEL**	H20f
SCAN TIME	2 s	**CONTRAST**	nonionic contrast media
SCAN DIRECTION	Caudal – cranial	**VOLUME**	80 ml
KV	120 kV	**FLOW RATE**	4 ml/s
EFFECTIVE MAS	150 mAs	**START DELAY**	25 s
ROTATION TIME	0.33 s	**POSTPROCESSING**	MIP, VRT
SLICE COLLIMATION	0.6 mm		
SLICE WIDTH	0.6 mm		

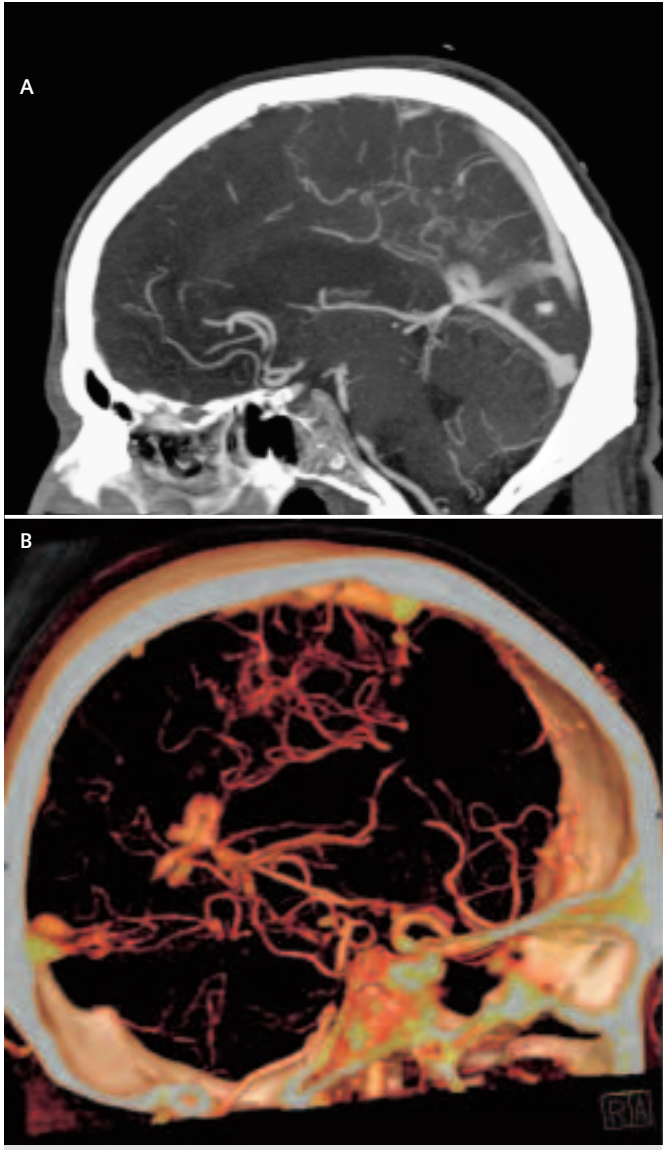

FIGURE 1 A+B:
A. Thin-sliding Maximum Intensity Projections (MIP) demonstrate an occlusion of the basilar artery in the mid-basilar section. The thrombus appears hypodense as compared to the contrast-filled lumen of the proximal basilar artery.
B. Volume Rendering Technique (VRT) again shows a complete mid-basilar occlusion. The head of the basilar artery demonstrates a retrograde perfusion.

FIGURE 2: Curved thin-sliding MIP demonstrates patent superior cerebellar arteries (long arrows) and a patent right posterior inferior cerebellar artery (short arrow).

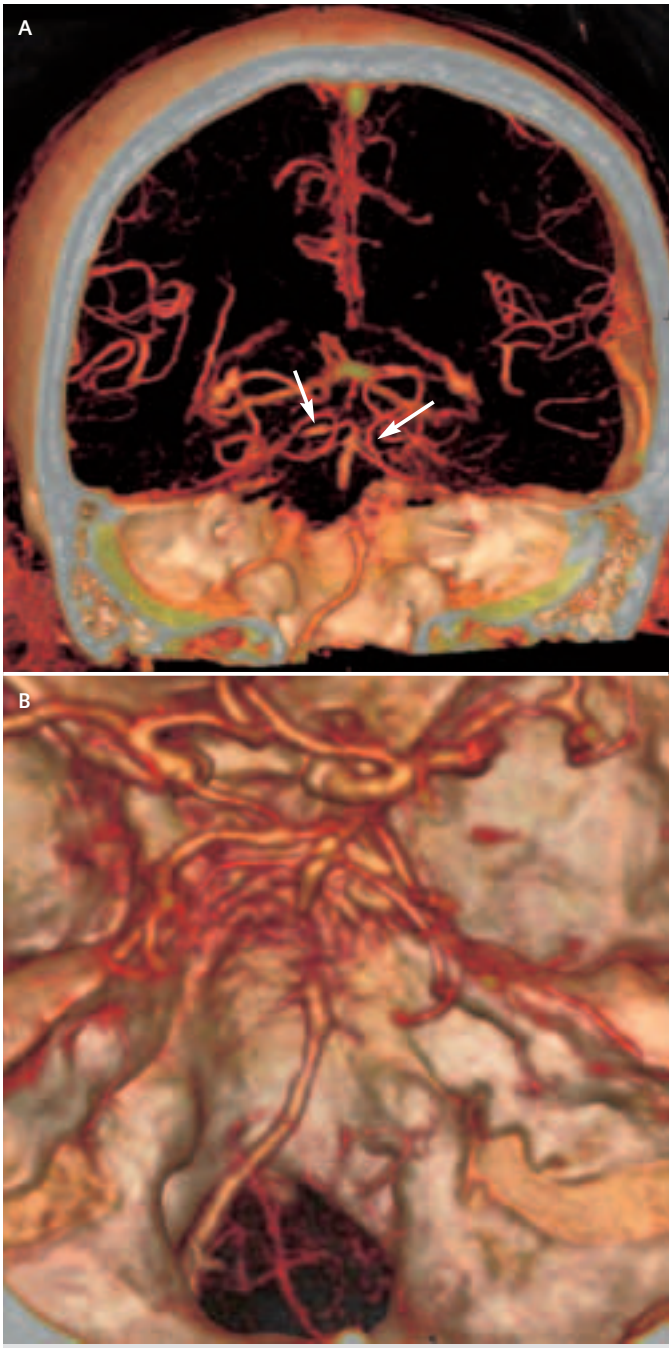

FIGURE 3 A+B:
A. VRT of the basilar artery demonstrates a retrograde perfusion of the basilar head. Both posterior cerebral arteries appear patent (arrows).
B. VRT of the basilar artery and the circle of Willis demonstrate a collateral circulation via the carotid arteries and the circle of Willis. The head of the basilar artery, both posterior cerebral arteries and the superior cerebellar arteries are perfused via the collateral circulation.