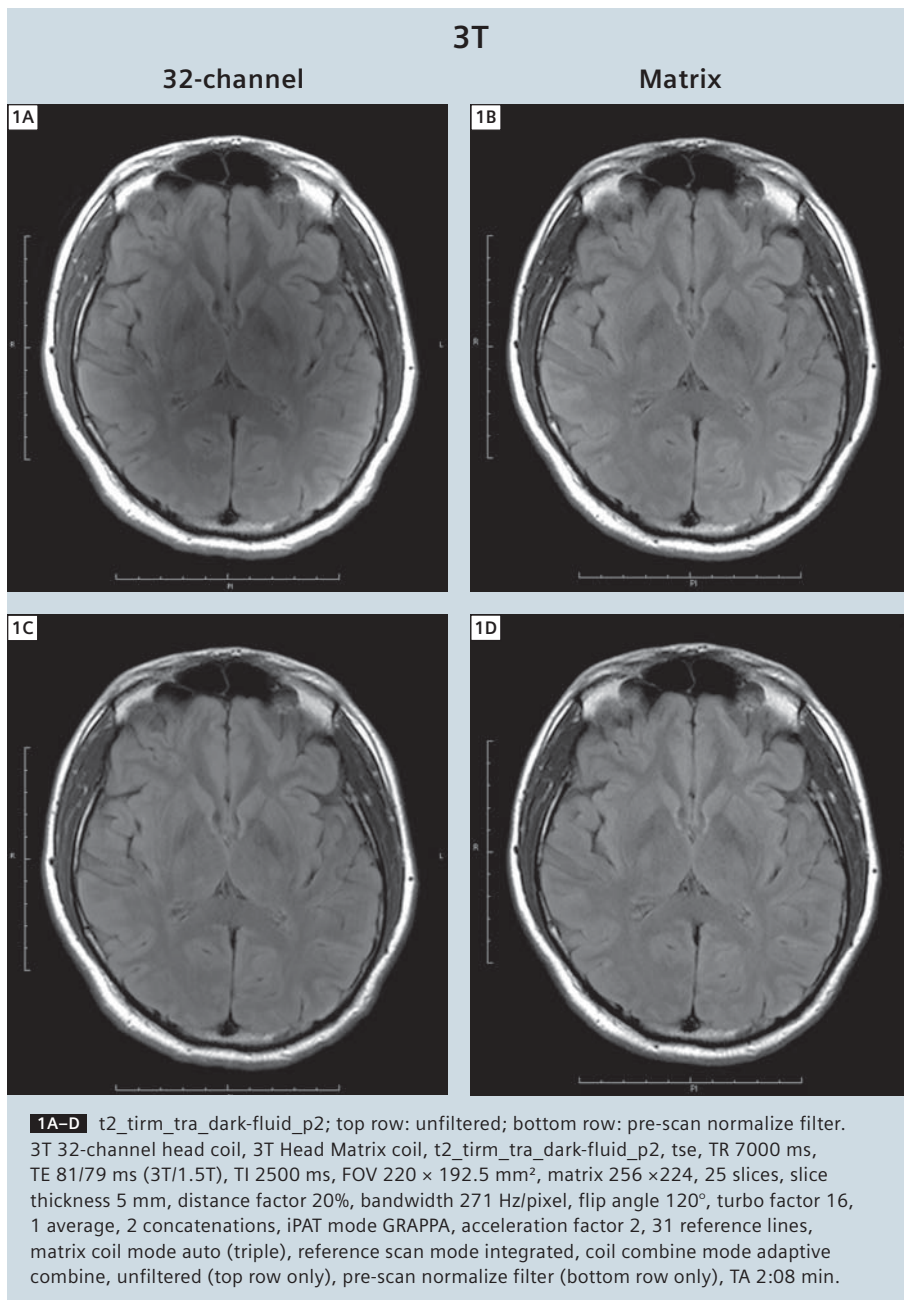


# Fast Clinical Protocols at 1.5T and 3T with Matrix and 32-Channel Head Coils

Thomas Benner

Athinoula A. Martinos Center for Biomedical Imaging, Department of Radiology, Massachusetts General Hospital and Harvard Medical School, Boston, MA, USA

In routine clinical MR imaging, short scan times are advantageous for patient compliance, patient throughput and image quality (images are less likely to be affected by motion) but can usually only be achieved at the cost of spatial resolution, coverage or image quality i.e. lower signal-to-noise ratio (SNR). The new 32-channel head coils for 1.5T and 3T provide better SNR and better parallel imaging performance compared to the standard 12-channel Head Matrix Coil [1, 2]. The use of these new coils should therefore allow very short acquisition times at higher acceleration factors at comparable image quality i.e. without loss of SNR and without increase in iPAT (integrated Parallel Acquisition Technique) related image artifacts. For this report, T1-weighted, T2-weighted, FLAIR, and diffusion tensor imaging (DTI) scans were performed at 1.5T (MAGNETOM Avanto, software version *syngo* MR B 15A SP2) and 3T (MAGNETOM Trio, A Tim System, software version *syngo* MR B15A SP2) with the Head Matrix coil and the 32-channel head coil, respectively. While not necessarily achieving optimal contrast at each field strength, the same imaging parameters were used at both field strengths and both head coils for ease of comparison. Echo-planar imaging (EPI) allows ultra-fast image acquisition and may therefore present an alternative to conventional imaging. For comparison, T1-weighted EPI, T2-weighted EPI and FLAIR EPI scans were acquired in addition to the conventional imaging scans.



Altogether, four studies were performed: one study using the Head Matrix coil and one using the 32-channel head coils on each of the two MR scanners. The same healthy appearing volunteer was scanned. AutoAlign was used to ensure closely matching slice positioning between the studies [3–5]. Each study lasted about 25 minutes.

The resulting image data was compared according to

- scan type being used i.e. conventional scans vs. EPI scans,
- acceleration factor being used i.e. PAT 2 vs. PAT 3 vs. PAT 4,
- head coil being used i.e. 32-channel head coil vs. Head Matrix coil, and
- field strength being used i.e. 3T vs. 1.5T.

The performance of the image normalization filter was examined as well.

### Signal intensity normalization

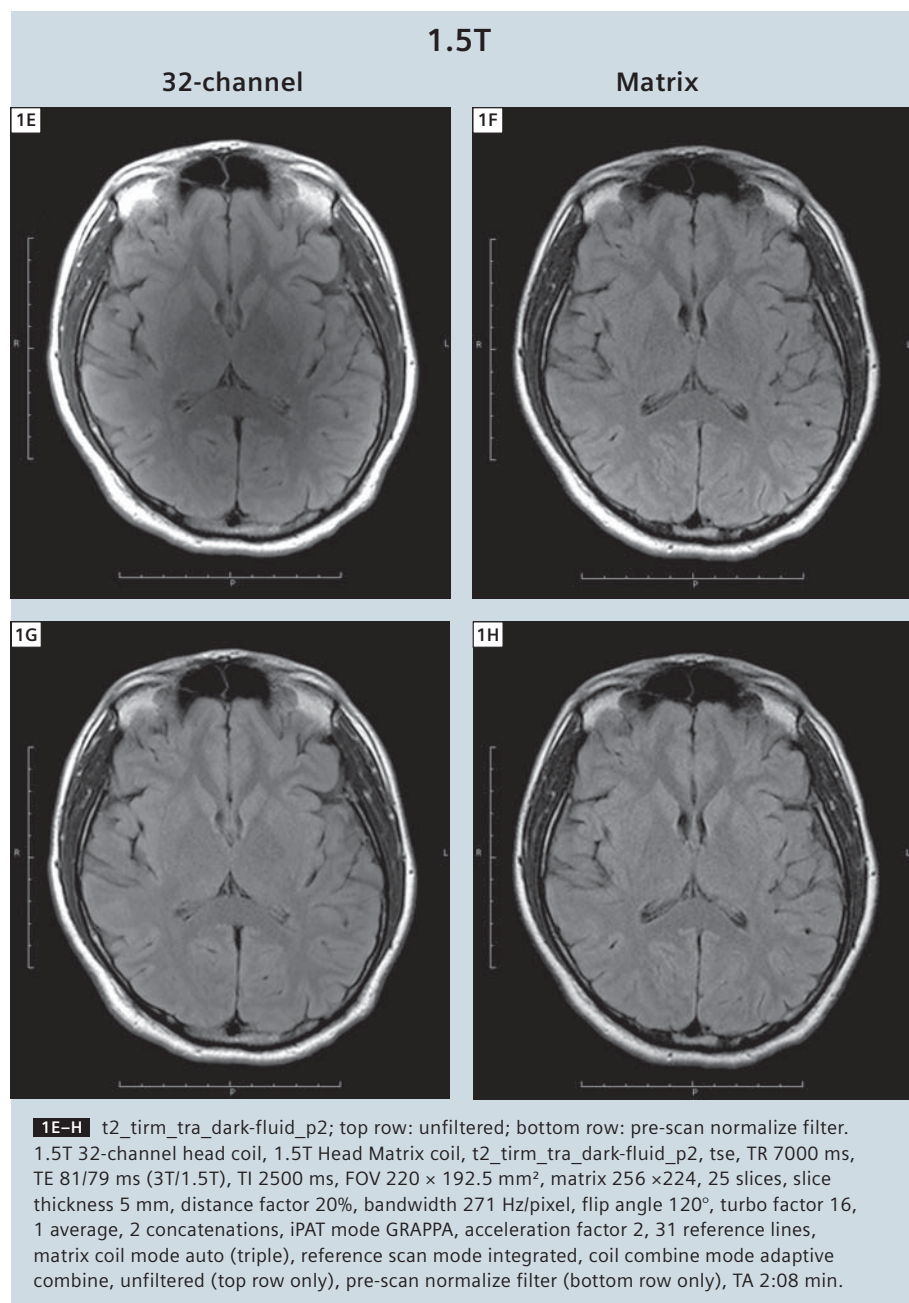
Smaller coil elements coupled with closer proximity of the head to these coil elements causes a more pronounced signal intensity as well as SNR gradient. To reduce the large signal intensity variations from periphery to the center of the brain a signal intensity normalization filter should be used. As expected, the signal intensity variations are larger on images from the 32-channel head coil compared to the more subtle effect on images from the Head Matrix coil (Fig. 1, top row). The signal intensity normalization (pre-scan normalize filter) works well at 1.5T and 3T (Fig. 1, bottom row). This not only applies to the conventional FLAIR scans but also to the T1-weighted, T2-weighted and EPI scans performed.

### EPI vs. conventional imaging

Echo-planar imaging allows very fast image acquisition in the order of 10–100's of milliseconds per slice and should therefore allow shorter scan times than conventional imaging.

However, at high spatial resolutions acceleration is essential to achieve short echo times and to reduce susceptibility induced artifacts in EPI. Parallel imaging requires the acquisition of reference

lines at the beginning of the scan, lengthening the scan times by multiple times the repetition time. Thus EPI scans become comparable in duration or even exceed the duration of conventional



scans. This is also the case if multiple averages or measurements need to be acquired e.g. for increased SNR.

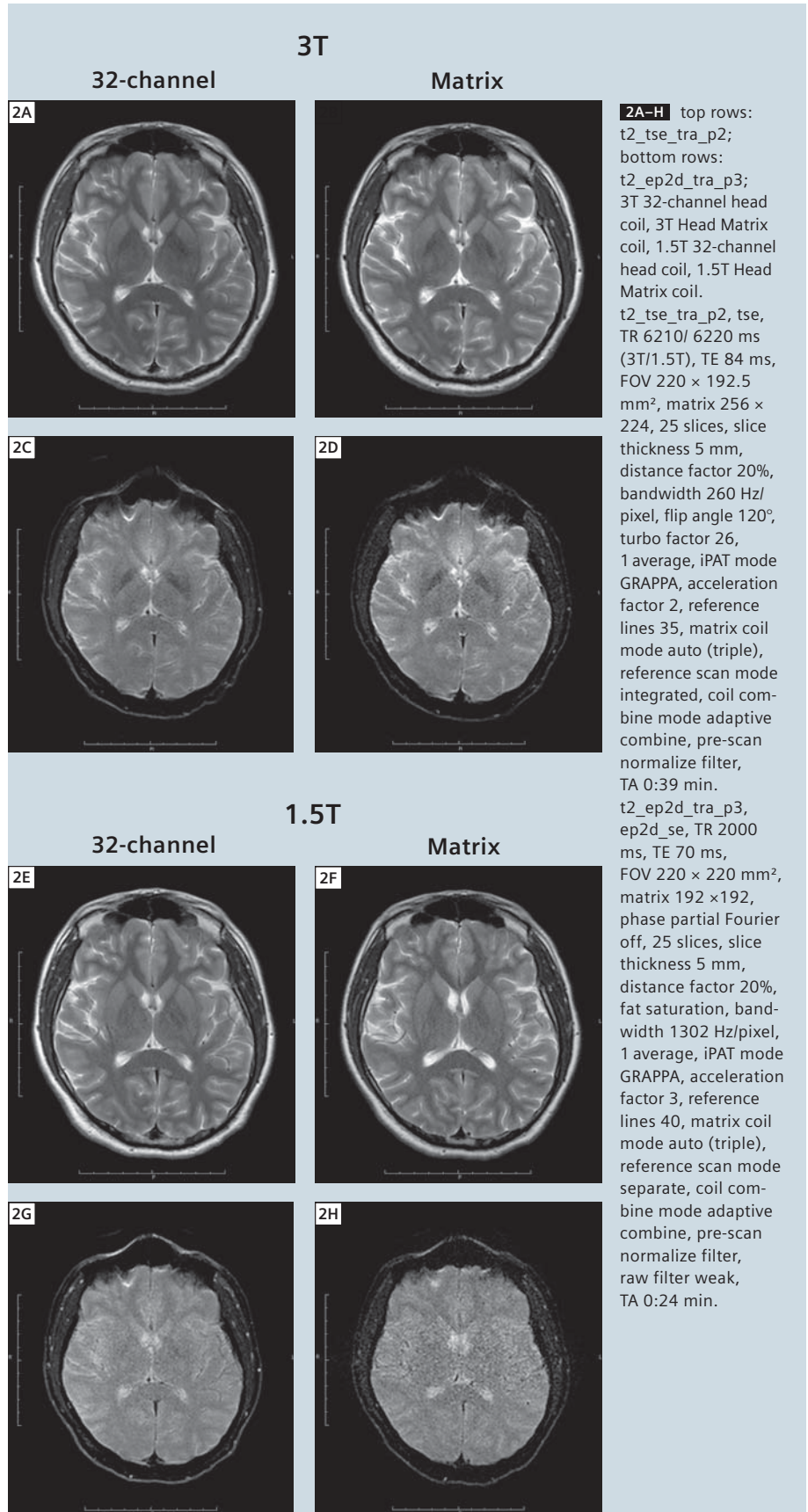
Figure 2 shows T2-weighted images acquired with a conventional TSE scan and an EPI scan. At similar scan times (t2\_tse\_tra\_p2, 0:39 min vs. t2\_ep2d\_tra\_p3, 0:24 min) the image quality of the TSE data is superior in terms of SNR, contrast, distortions and susceptibility artifacts. The same effect is shown in Figure 3 where images from conventional FLAIR scans are compared to EPI based FLAIR scans (t2\_tirm\_tra\_dark-fluid\_p3, 1:40 min vs. t2\_ep2d\_tra\_p3, 1:47 min). At comparable scan time, the image quality of the conventional scans is superior. The same was found for the T1-weighted scans (images not shown).

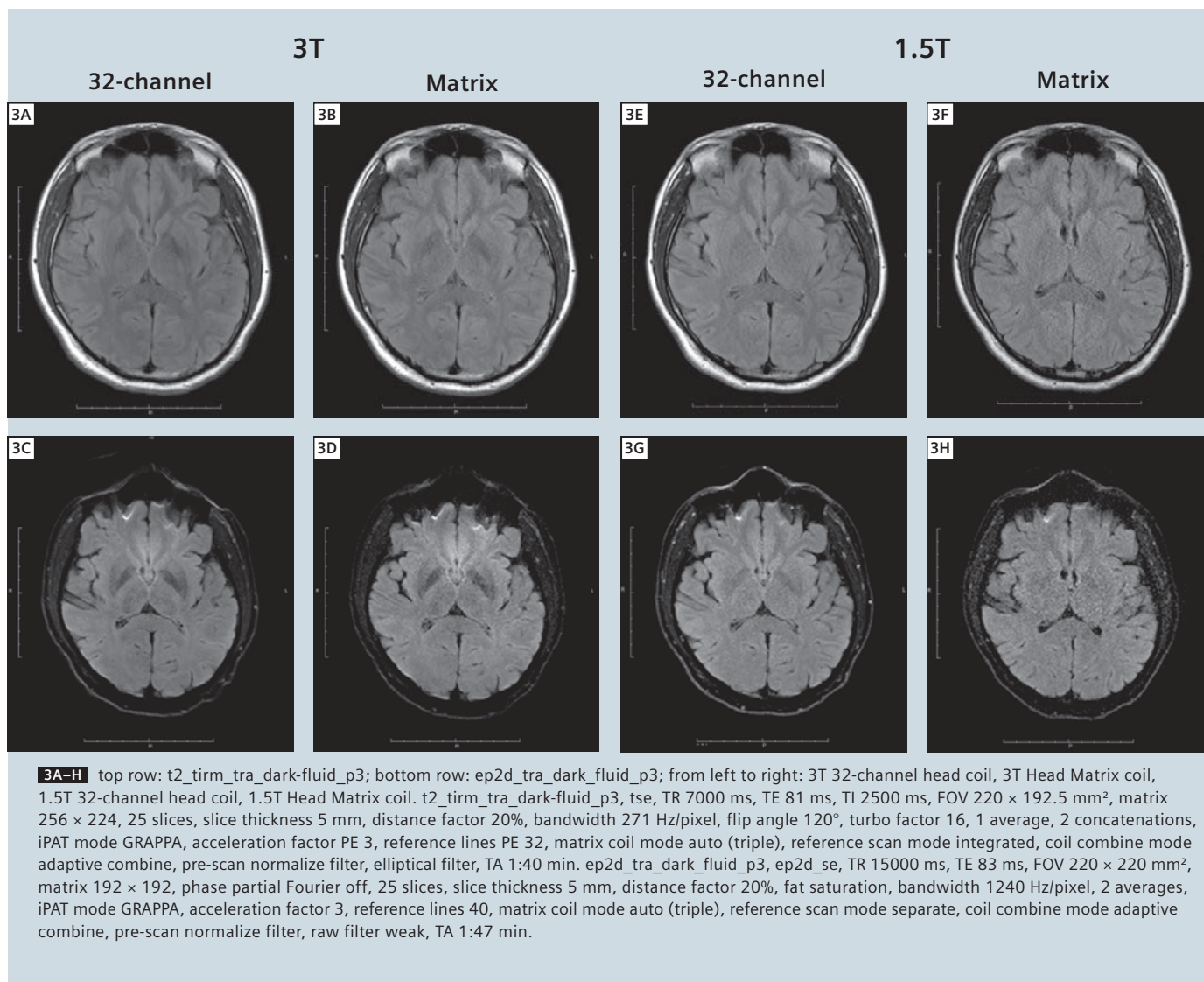
### Parallel imaging

A larger number of coil elements usually translates into better acceleration performance (improved g-factor) [2]. This is demonstrated in Figures 4 and 5.

Increasing the PAT factor from 3 to 4 for an EPI FLAIR scan (ep2d\_tra\_dark-fluid\_p3 to ep2d\_tra\_dark-fluid\_p4) causes little image degradation when using the 32-channel coil at 3T (Fig. 4 A, C). A more pronounced degradation can be found at 3T when using the Head Matrix coil and at 1.5T when using the 32-channel coil (Fig. 4B, D and E, G). An already noisy image at 1.5T with PAT factor 3 is rendered unusable when increasing PAT to a factor of 4 (Fig. 4F, H). The same effect is demonstrated for PAT factor 2 vs. 3 for a conventional T1-weighted scan (t1\_fl2d\_tra\_p2 vs. t1\_fl2d\_tra\_p3) (Fig. 5). While there is little effect at high field with the 32-channel head coil (Fig. 5A, C), a noticeable increase in noise appears at 3T with the Head Matrix coil and at 1.5T with the 32-channel head coil (Fig. 5B, D and E, G). At 1.5T with the Head Matrix coil, an iPAT related image artifact and noise dominate the picture at a PAT factor of 3 (Fig. 5F, H).

For DTI, increasing the PAT factor from 2 to 3 and to 4 leads to a reduction of distortion artifacts. However, the additional gain is diminishing beyond a PAT factor





of 2. SNR is decreasing as well as making the images unusable at 1.5T with the Head Matrix coil at a PAT factor of 3. At a PAT factor of 4 only the 32-channel head coil at 3T provides sufficient SNR for interpretable images.

### 32-channel head coil vs. Head Matrix coil

At both field strengths, 1.5T and 3T, the 32-channel head coil shows improved image quality i.e. higher SNR and better acceleration performance for all scan types performed (Fig. 6). The increased SNR is more dominant at the periphery and less at the center of the brain, which is attributable to the gradient in coil sen-

sitivity with distance from each coil element [1]. Because of the better g-factor of the 32-channel head coil fewer PAT related artifacts are visible even at higher PAT factors.

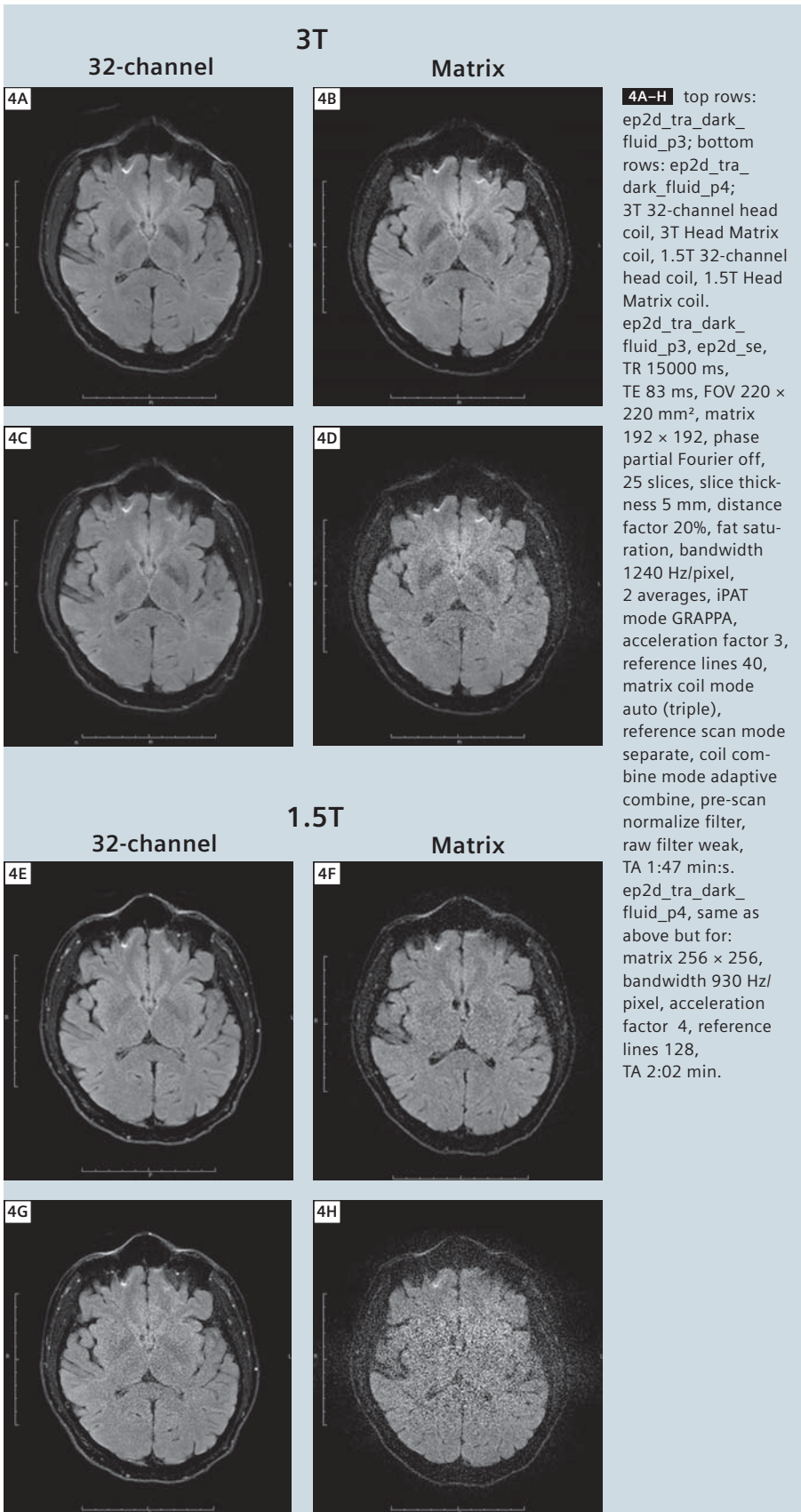
### 1.5T vs. 3T

A higher field strength (3T vs. 1.5T) translates into increased SNR when using the same head coil i.e. Head Matrix coil at 3T vs. 1.5 (Fig. 6, columns 2 vs. 4) or 32-channel head coil at 3T vs. 1.5T (Fig. 6, columns 1 vs. 3). Interestingly, the image quality (SNR) at 1.5T when using the 32-channel head coil is very comparable to the SNR when using the Head Matrix coil at 3T (Fig. 6, middle

two columns). The most dramatic differences in image quality can be seen between images acquired with the Head Matrix coil at 1.5T compared to those acquired with the 32-channel head coil at 3T (Fig. 6, columns 1 vs. 4).

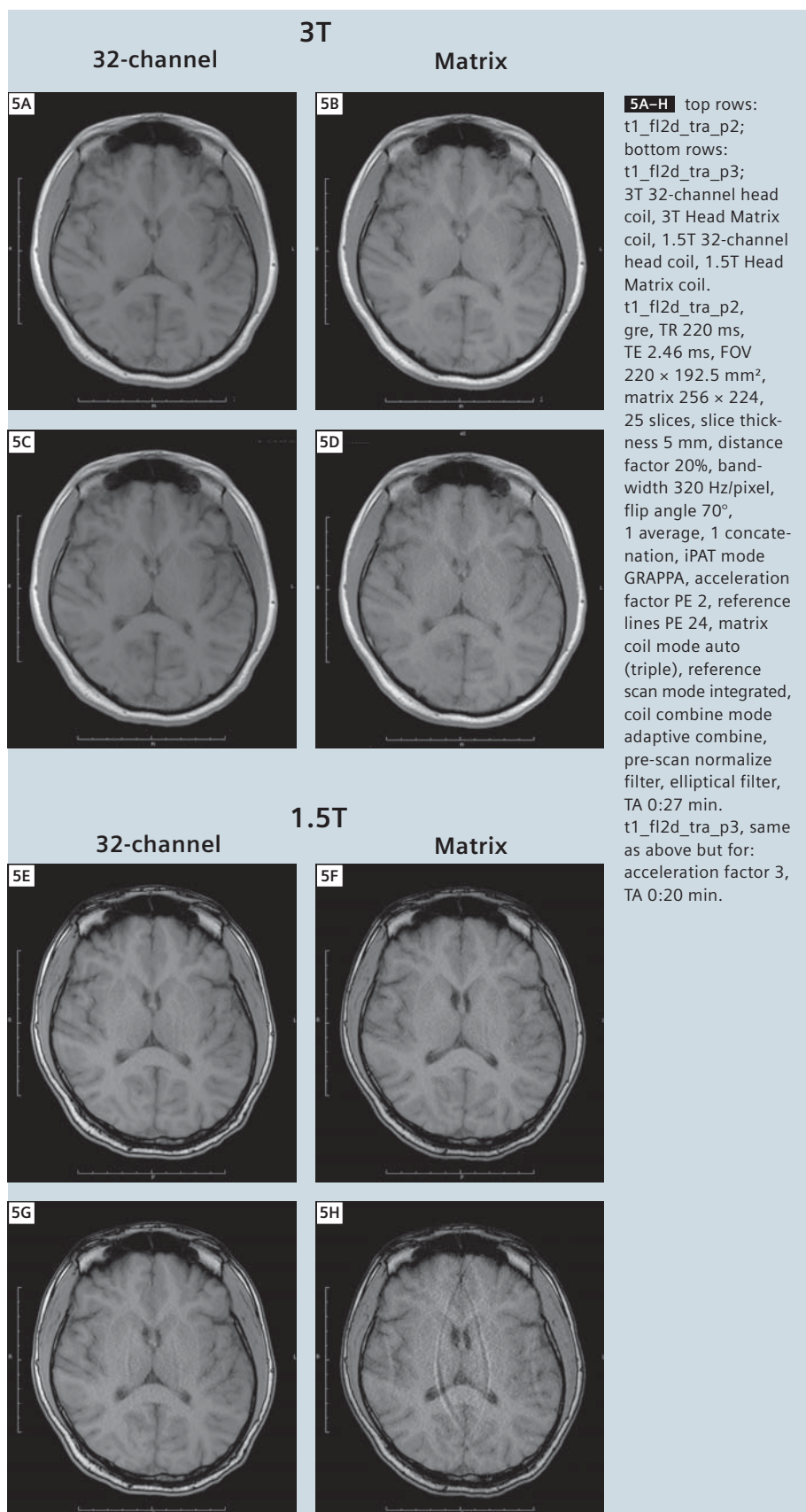
### Conclusions

At both field strengths i.e. 1.5T and 3T, the 32-channel head coils provide image quality that is superior to that from the standard Head Matrix coil. This is mostly due to the increased SNR of the 32-channel head coil compared to the 12-channel Head Matrix coil [1]. Note, though, that the 32-channel head coils exhibit a much larger gradient in SNR



**4A–H** top rows: ep2d\_tra\_dark\_fluid\_p3; bottom rows: ep2d\_tra\_dark\_fluid\_p4; 3T 32-channel head coil, 3T Head Matrix coil, 1.5T 32-channel head coil, 1.5T Head Matrix coil. ep2d\_tra\_dark\_fluid\_p3, ep2d\_se, TR 15000 ms, TE 83 ms, FOV 220 × 220 mm<sup>2</sup>, matrix 192 × 192, phase partial Fourier off, 25 slices, slice thickness 5 mm, distance factor 20%, fat saturation, bandwidth 1240 Hz/pixel, 2 averages, iPAT mode GRAPPA, acceleration factor 3, reference lines 40, matrix coil mode auto (triple), reference scan mode separate, coil combine mode adaptive combine, pre-scan normalize filter, raw filter weak, TA 1:47 min:s. ep2d\_tra\_dark\_fluid\_p4, same as above but for: matrix 256 × 256, bandwidth 930 Hz/pixel, acceleration factor 4, reference lines 128, TA 2:02 min.

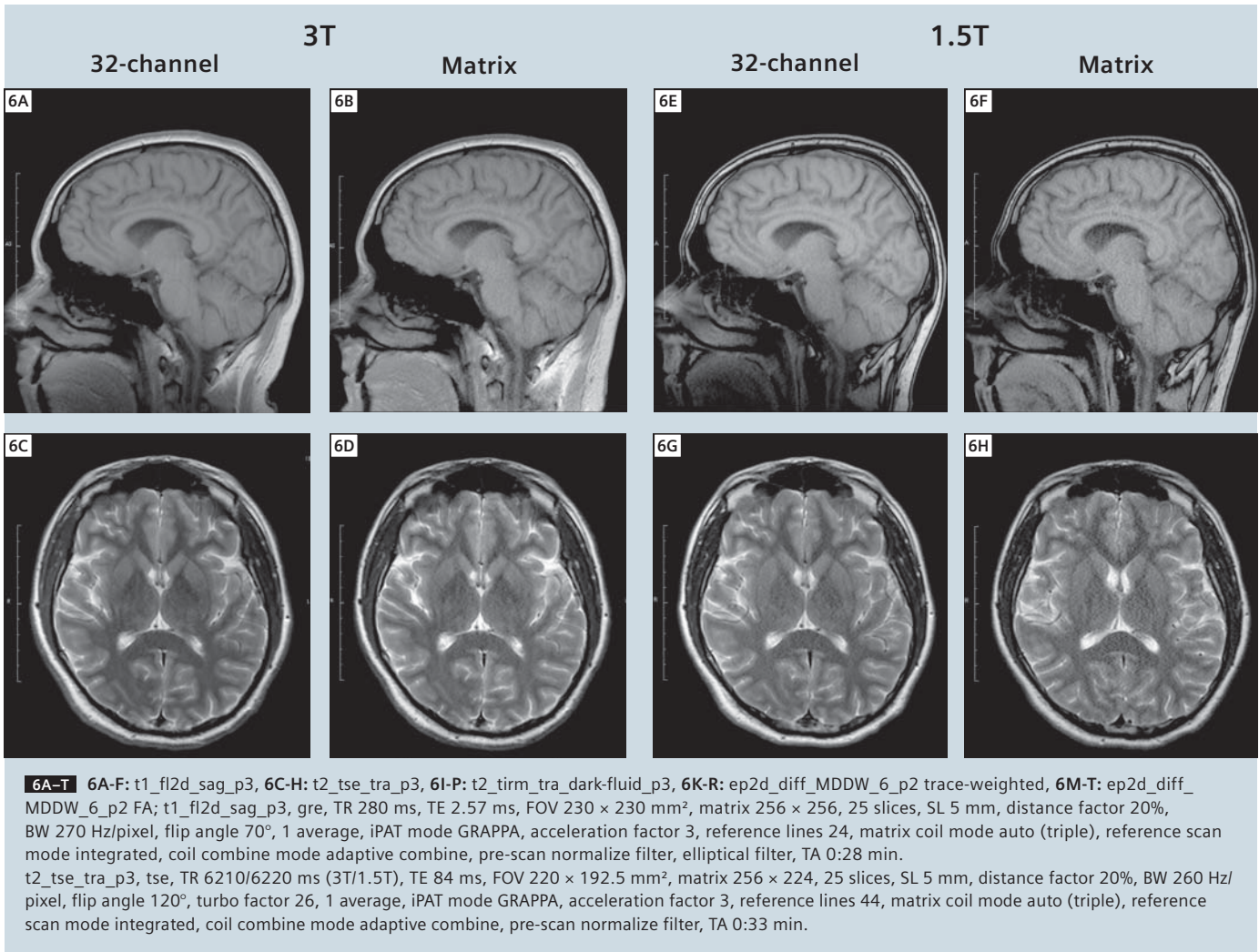
from the periphery to the center of the brain as compared to the Matrix coil, even when the latter is set to triple mode. At the center of the brain, the SNR gain was estimated at 20% compared to >100% at the cortex [1]. It was also shown that the larger number of coil elements allows higher acceleration factors to be used without significantly deteriorating image quality i.e. without causing increase in noise level and PAT related image artifacts. The pre-scan normalize filter works well for all coils at both field strengths to level the signal intensity gradient caused by close proximity to small local coils. No artifacts were seen in any of the scans that may have been caused by the application of this filter. For fast T1-weighted, T2-weighted and FLAIR clinical protocols, echo-planar imaging is no alternative to conventional imaging with respect to scan times and image quality. However, EPI is unmatched in terms of SNR and acquisition speed for DTI. Higher field strength provides the expected boost in SNR as can be appreciated in all scans performed for this study. It must be mentioned that the image quality in terms of SNR of scans performed at 1.5T with the 32-channel head coil are very comparable to the image quality of scans performed at 3T with the Head Matrix coil. In other words: for clinical head imaging the 32-channel head coil may be a worthwhile upgrade to an existing 1.5T MRI scanner. Of course, differences in image contrast between different field strengths e.g. for susceptibility-weighted imaging (SWI) [6] cannot be achieved by using the 32-channel head coil. Table 1 lists a set of recommended protocols that allows the acquisition of T1-weighted, T2-weighted, FLAIR and DTI data in less than 5 minutes while preserving good image quality when using a 32-channel head coil. These protocols apply to both, 1.5T and 3T. However, the image quality (SNR) can be



improved by switching the conventional protocols from a PAT factor of 3 to 2 at the cost of slightly increased scan times. With the use of AutoAlign, these protocols can be set up to allow a “one-click” scan session i.e. after the landmarking of the patient, a single click will load the protocols into the scan queue, perform an automatic slice prescription and acquire the scans. No further user interaction is necessary. As can be seen from the figures, the automatic slice prescription with AutoAlign results in very reproducible slice locations over the course of multiple studies even at different field strength and scanner types. Due to the large number of receive channels, image reconstruction times can be slightly increased when using the 32-channel head coil although this is barely noticeable for the scans performed in this study. A minor disadvantage is the fact that the close fitting 32-channel head coils may not be large enough for some subjects. Finally, the neck array can currently not be used in combination with the 32-channel head coils thereby requiring a coil change when head and neck scans are required. In summary, the 32-channel head coils for 1.5T and 3T provide improved image quality and allow faster image acquisition at comparable image quality when using the Head Matrix coil without significant disadvantages.

### Acknowledgements

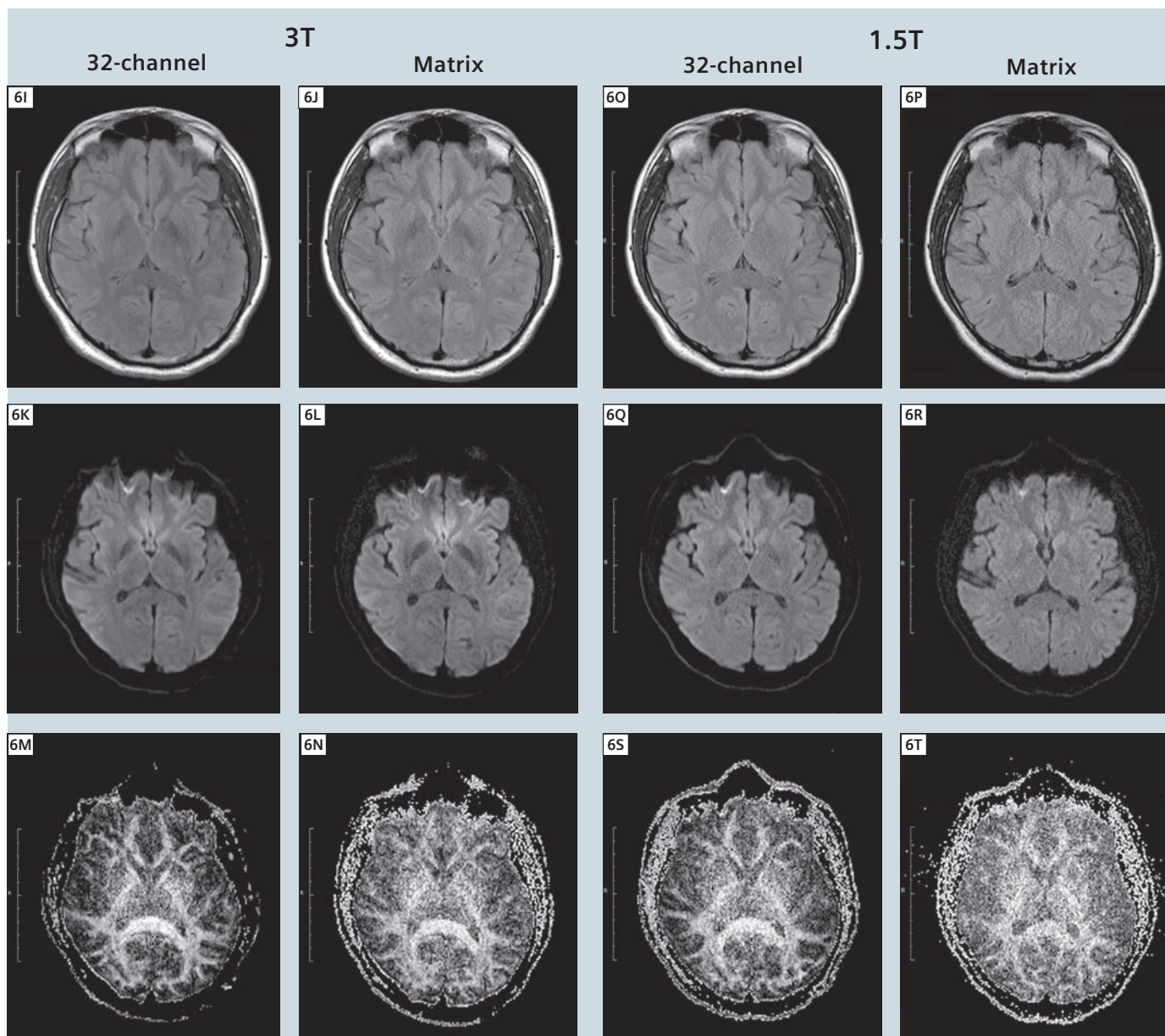
I would like to thank Michael Hamm for help with data acquisition and acknowledge support from the National Center for Research Resources (P41RR14075).



**Table 1: Listing of selected short clinical protocols with scan duration. Protocols correspond to data shown in Figure 6.**

Protocol	TR [ms]	TE [ms]	FoV [mm × mm]	Matrix	Bandwidth [Hz/pixel]
localizer					
AAScout					
t1_fl2d_sag_p3	280	2.57	230 × 230	256 × 256	270
t2_tse_tra_p3	6210/6220*	84	220 × 192.5	256 × 224	260
t2_tirm_tra_dark-fluid_p3	7000	81/79*	220 × 192.5	256 × 224	271
ep2d_diff_MDDW_6_p2	3900/4000*	94	220 × 220	192 × 192	1184

Note: total scan duration does not include time needed for scanner adjustments e.g. shimming. (\*3T/1.5T)



**6A-T** t2\_tirm\_tra\_dark-fluid\_p3, tse, TR 7000 ms, TE 81/79 ms (3T/1.5T), TI 2500 ms, FOV 220 × 192.5 mm<sup>2</sup>, matrix 256 × 224, 25 slices, SL 5 mm, distance factor 20%, BW 271 Hz/pixel, flip angle 120°, turbo factor 16, 1 average, 2 concatenations, iPAT mode GRAPPA, acceleration factor 3, reference lines 32, matrix coil mode auto (triple), reference scan mode integrated, coil combine mode adaptive combine, pre-scan normalize filter, elliptical filter, TA 1:40 min. ep2d\_diff\_MDDW\_6\_p2, ep2d\_diff, TR 3900/4000 ms (3T/1.5T), TE 94 ms, FOV 220 × 220 mm<sup>2</sup>, matrix 192 × 192, phase partial Fourier 6/8, 25 slices, SL 5 mm, distance factor 20%, fat sat, BW 1184 Hz/pixel, 1 average, 2 diffusion weightings, b1 0 s/mm<sup>2</sup>, b2 1000 s/mm<sup>2</sup>, 6 diffusion directions, iPAT mode GRAPPA, acceleration factor 2, reference lines 40, matrix coil mode auto (triple), reference scan mode separate, coil combine mode adaptive combine, pre-scan normalize filter, raw filter, TA 0:41 min.

#### References

- 1 Stapf J. 32-Channel Phased-Array Head Coil for 1.5T and 3T. *MAGNETOM Flash* 1/2008, 45.
- 2 Wald LL, Wiggins G. Highly Parallel Detection for MRI. *MAGNETOM Flash* 1/2008, 34–44.
- 3 van der Kouwe AJ, Benner T, Fischl B, Schmitt F, Salat DH, Harder M, Sorensen AG, Dale AM. Online automatic slice positioning for brain MR imaging. *Neuroimage*. 2005 Aug 1;27(1):222–230.
- 4 Benner T, Wisco JJ, van der Kouwe AJ, Fischl B, Vangel MG, Hochberg FH, Sorensen AG. Comparison of manual and automatic section positioning of brain MR images. *Radiology*. 2006 Apr;239(1):246–254.
- 5 Scott KT. Software Compensation for Patient Position Enabling Reproducible Slice Positioning – AutoAlign. *MAGNETOM Flash* 1/2006, 98–103.
- 6 Haacke EM, Xu Y, Cheng YC, Reichenbach JR. Susceptibility weighted imaging (SWI). *Magn Reson Med*. 2004 Sep;52(3):612–618.

#### Contact

Thomas Benner  
Athinoula A. Martinos Center  
for Biomedical Imaging  
Dept. of Radiology  
Massachusetts General Hospital  
and Harvard Medical School  
Boston, MA  
USA  
benner@nmr.mgh.harvard.edu