

# Surgery Opens up to New Treatment Methods

**Prof. Dr. Georg Nollert**

Article from the customer magazine AXIOM Innovations, October 2008

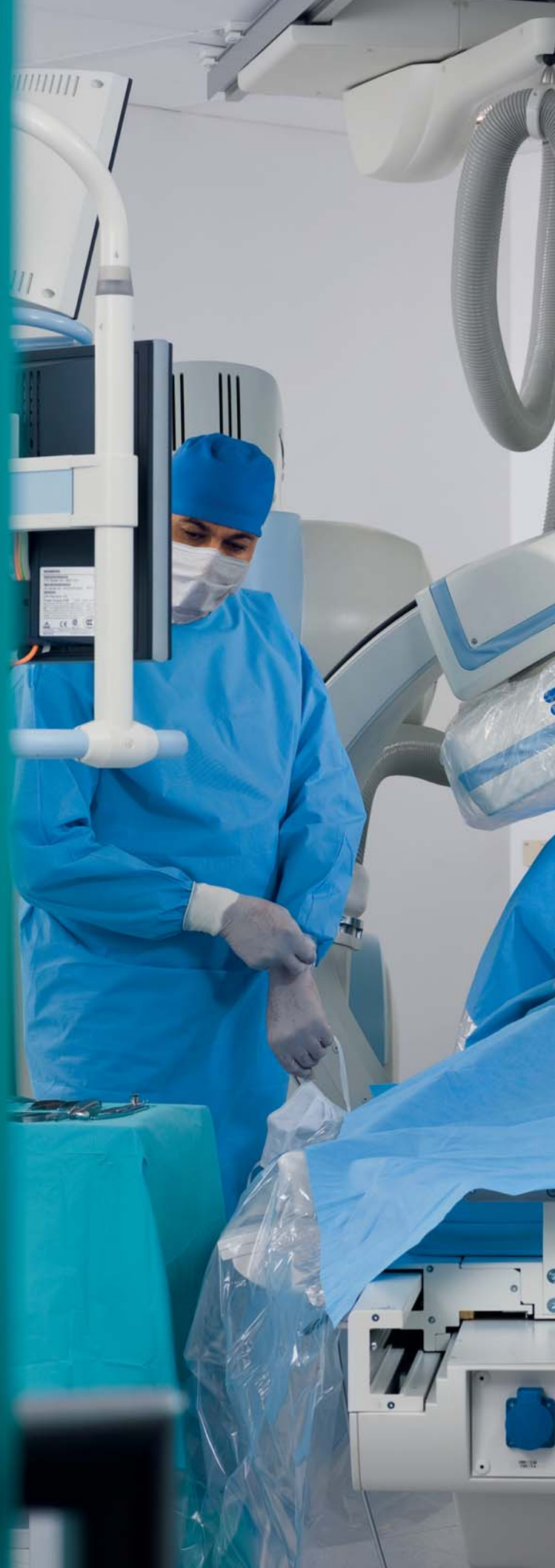[www.siemens.com/healthcare-magazine](http://www.siemens.com/healthcare-magazine)

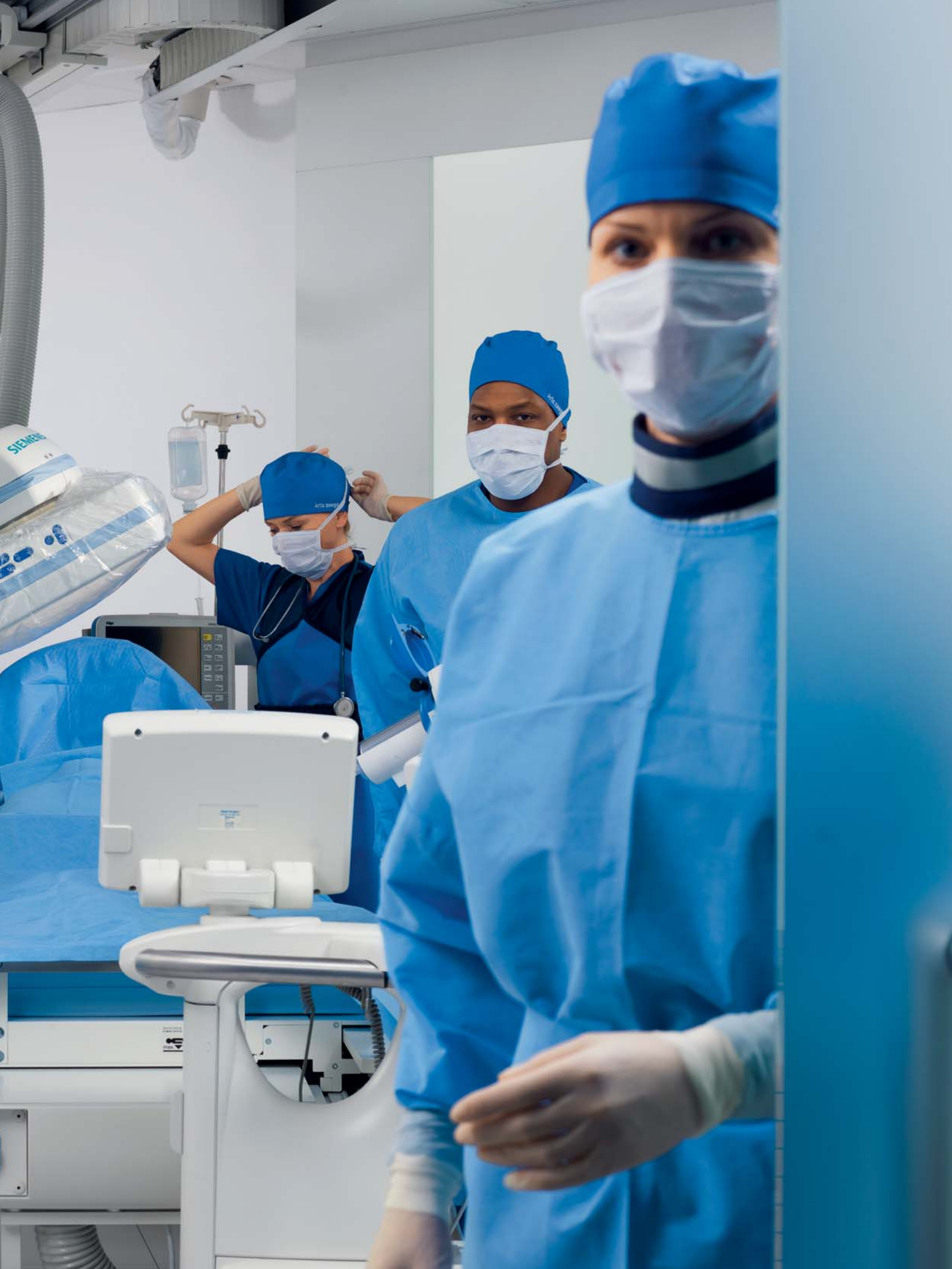**SIEMENS**

# Surgery Opens up to New Treatment Methods

Recent developments in cardiac surgery have led to new therapies integrating surgical procedures with skin incisions and interventions, e.g. transcatheter techniques with the puncture of a vessel. For these procedures, integrated operating rooms are needed. In addition to surgical equipment, these hybrid operating rooms need high-end imaging equipment equivalent to the angiography devices used in interventional radiography and cardiology.

By Prof. Dr. Georg Nollert





Imaging devices have been used in operating theaters for a long time. Mobile C-arms, ultrasound, and endoscopy are standard of care for many operations. However, complex transcatheter techniques demand high powered equipment to visualize thin guidewires, quantify small vessel diameters, and evaluate delicate anastomoses. Because of their size and complexity, these integrated endovascular suites or hybrid ORs require special consideration, planning, and design as well as new skills to be learned by the surgical team.

### Basics of the hybrid room

There is no doubt that an interdisciplinary team of surgeons, interventionalists, anesthesiologists, and other associated specialists should plan and run such a facility. Centers in close proximity to intervention rooms and ORs probably have better prerequisites than hospitals with the classic separation that placed interventional rooms in the internal medicine building and operating theaters in the surgery building. In this situation, it is recommended to install the hybrid room in the surgical wing, where all OR equipment and personnel (e.g. heart-lung machine and perfusionists), anesthesia and surgical intensive care are readily available. Reasonable proximity of the hybrid room to other imaging systems like computed tomography scanning or magnetic resonance imaging should also be taken into consideration.

A hybrid OR should be larger than a standard OR and the basic principle for planning is "the larger the better", because not only the imaging equipment needs sufficient space. Staff calculations have shown that in hybrid procedures up to 18 people need to be in the hybrid room. Experts recommend 70 m<sup>2</sup> for new ORs being built. Additional space for a control room is mandatory.

If a fixed C-arm system is being considered, 45 m<sup>2</sup> space is the lower limit. Lead shielding (2-3 mm) will need to be built into existing rooms. In some countries, special training for the use of X-ray devices may be required.

In general, all members of the team need access to all important information. Therefore, multiple moveable and flexible booms need to be installed in the operating room. If there are two booms to be installed, a boom on every side of the OR table serves the operative team. Collision of the ceiling-mounted displays with operating lights or other ceiling-mounted equipment should be avoided. A dedicated ceiling plan with all ceiling-mounted components including air conditioning should be drawn to ensure the function and usability of all devices.


### New therapies have emerged

Pediatric hybrid operations, hybrid coronary revascularization, transcatheter valve replacement and repair, or stent-graft placement in the thoracic aorta are new developments that are ideally performed in a hybrid operating room. Although hybrid therapies were first developed in a close collaboration be-

tween pediatric cardiology and pediatric cardiac surgery, currently the strongest driver for hybrid therapies is transcatheter replacement of the stenotic aortic valve.

### Trends in pediatric cardiac surgery

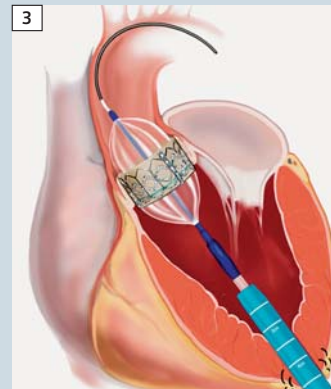
Surgery remains the treatment of choice for most congenital cardiac malformations. But interventional cardiology approaches are increasingly being used in simple and even complex lesions. The percutaneous approach can be challenging due to low patient weight or poor vascular access. The passage of large catheters through the heart in small infants may result in rhythm disturbances and hemodynamic compromise. Difficult and complex anatomy such as in double-outlet right ventricle or transposition of the great arteries, or acute turns or kinks in the pulmonary arteries in tetralogy of Fallot patients can make percutaneous procedures challenging if not impossible. Surgery also has its limitations, when it comes to operative closure of multiple apical muscular ventricular septal defects, adequate and lasting relief of peripheral pulmonic stenosis, or management of a previously implanted



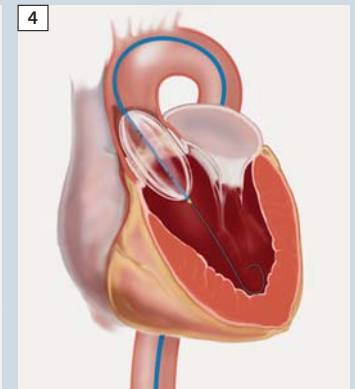
1 CoreValve



2 Edwards Sapien prostheses



3 Transapical technique



4 Transfemoral technique

stenotic stent. Furthermore, in some complex malformations, the presence of multiple ventricular septal defects increases the mortality risk, because they are difficult to access by surgery. Combining interventions and surgery into a single therapeutic procedure reduces complexity, cardiopulmonary bypass time, risk, and improved outcomes.

### New possibilities for heart patients

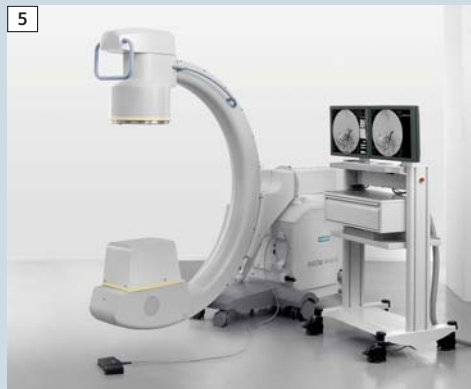Surgical and percutaneous coronary artery interventional revascularization are traditionally considered isolated options. A simultaneous hybrid approach may allow an opportunity to match the best strategy for a particular anatomic lesion. Revascularization of the left anterior descending artery with the left internal mammary artery is by far the best treatment option in terms of long-term results. Integrating this therapy with percutaneous coronary angioplasty offers multi-vessel revascularization through a mini-thoracotomy. Particularly in high risk patients, morbidity and mortality decreases compared to conventional surgery. Reasons are the avoidance of cardiopulmonary and its bypass-related morbidity, no manipula-

tion of the aorta, which reduces the chance of potentially fatal emboli, and the low surgical trauma by using minimally invasive techniques. Hybrid revascularization is currently performed only in a few centers worldwide. One reason is the real challenge regarding logistics, because an interventional and surgical team have to work together, and the environment in which to perform this therapy – a hybrid room – is scarce. But in the end, a higher number of repeat interventions compared with off-pump coronary artery bypass grafting was seen, because the stented vessels had a higher occurrence of restenoses. However, with the advent of drug-eluting stents, the reintervention rate decreased. A recent feasibility study from the University of Maryland evaluated 13 patients with multi-vessel coronary artery disease who underwent left internal mammary artery-to-LAD minimally invasive direct coronary bypass performed through a lateral thoracotomy, followed by stenting of non-LAD lesions, in a fluoroscopy-equipped operating room. These patients had a more than 40% decreased length of stay and a more than 90% decrease in intubation times. Despite aggressive anticoagulation and confirmed platelet inhibition, the patients had less blood loss and de-

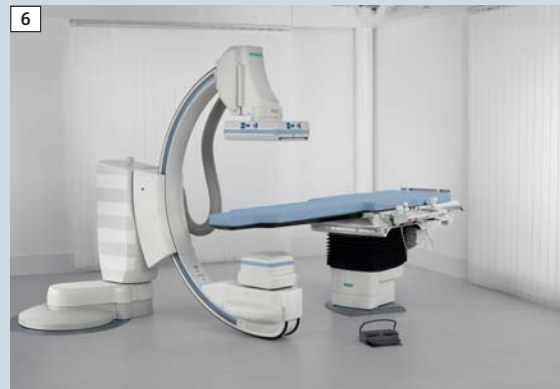creased transfusions. Six-month angiographic vessel patency and major adverse cardiac events were similar in the hybrid and off-pump coronary artery bypass groups. These clinical advantages will probably lead to a spread of hybrid revascularization techniques when hybrid rooms become more commonly available.

### Trends in transcatheter valve therapy

Transcatheter valve therapies are currently developed for the most common valve diseases: mitral valve regurgitation, aortic stenosis, and – in children – pulmonary valve disease. For repair of mitral regurgitation, more than 30 devices are currently under investigation and await market approval. Experimentally, prostheses for mitral and tricuspid valve replacement are under development and certainly will be available within the next several years. Aortic stenosis is the most frequent acquired heart valve lesion in developed countries. Conventional aortic valve replacement for aortic stenosis is based upon standardized guidelines with excellent outcomes particularly in younger patients at relatively low risk. Advanced



**5** AXIOM Artis U, the room-mobile system for small ORs.



**6** Artis zee floor-mounted system brings high-end imaging to the OR.

age and severe co-morbidities lead to an increased surgical risk. Cardiologists are reluctant to refer these patients to surgery, because they are considered to be 'too sick', although conservative treatment of aortic stenosis carries a fatal prognosis. Low-risk, minimally invasive techniques are needed to treat these very high-risk patients.

### Transcatheter aortic valve replacement (TAVR)

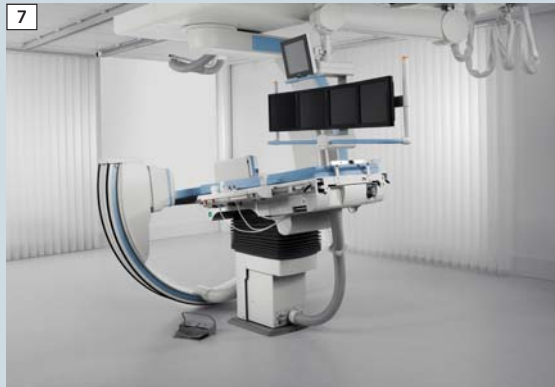In 2002, Cribier reported the first human transcatheter aortic valve replacement (TAVR) using a transfemoral, antegrade, transseptal approach. Subsequently two valves were introduced to the market, i.e., the CoreValve and the Edwards Sapien prostheses (Fig. 1 and 2)<sup>1</sup>.

Both valves have some similar fundamental design features, including xenogenic pericardial valve cusps and a compressible stent suspending these cusps allowing for transcatheter delivery. There are, however, significant differences. The CoreValve prosthesis has an approximately 50 mm long self-expanding nitinol stent, with a tubular 'hour glass' shape that can deploy in the aortic root, above the level of the coro-

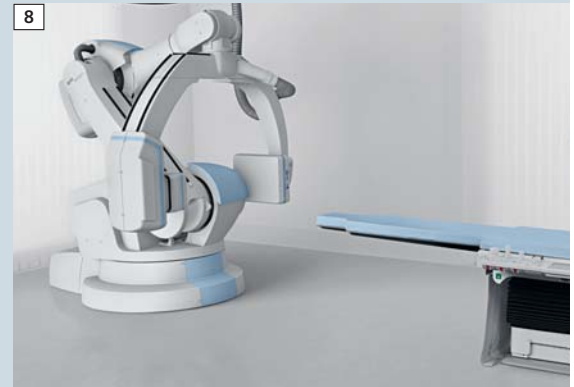
nary artery ostia, and a wide mesh allowing for unobstructed coronary flow. The Edwards Sapien prosthesis has a 14 – 16 mm balloon-expandable straight-tube steel stent, mimicking a standard stented bioprosthetic valve. It is strictly deployed within the aortic annulus and sits in a subcoronary position in vivo. With regard to the leaflet cusps, the CoreValve device is constructed of porcine pericardium, whereas the Edwards Sapien device utilizes bovine pericardium. Three generations of the CoreValve device have been implanted, the 24F, 21F, and now the 18F prostheses. Two inflow diameters, 26 and 29 mm, are available, allowing for sufficient oversizing. With the Edwards Sapien valve, diameters of 23 and 26 mm are offered. A 29 mm prosthesis is under development. Current sheath diameters for transfemoral implantation are 22F and 24F, with smaller versions on the horizon. Implantations have been performed using both the transfemoral and the transapical route with each device. Up to now, more than 1,000 patients have received a CoreValve or an Edwards Sapien prosthesis. In parallel with the development of the transfemoral technique (Fig. 3), the direct, antegrade, transapical technique was explored (Fig. 4). The first successful

transapical valve implantations using an oversizing technique were published in summer 2006. When both techniques are compared, stroke risk was demonstrated to be lower with the transapical approach, which could be related to less aortic manipulation. A second important complication of TAVR is the high incidence of AV block, which is obviously valve-dependent and reported to be higher with the CoreValve. ATS, JenaValve, Sorin, and Ventor, among other companies, are currently conducting experimental evaluations and are on the verge of clinical implantations. Further systems for TAVR including the Lotus, AorTx, the Direct Flow Medical valve and the PercValve are under development and further systems will follow.

For TAVR, valve positioning remains the most critical part of implantation with the risk of coronary artery obstruction and the risk of paravalvular leak. Exact positioning, optimal imaging during implantation and an experienced team performing the procedure are critical. TAVR requires some specific equipment. A hybrid operative theater is the ideal setting for TAVR and is recommended by the European Association for Cardio-Thoracic Surgery. The hybrid OR offers the sterile environment with emergency



**7** Flexibility and whole body coverage is provided by the Artis **zee** ceiling-mounted solution.



**8** Flexible park positions, variable iso-center and new 3D imaging capabilities are possible only with Artis **zeeo**.

back-up measures and the angiographic imaging technology needed in the catheterization laboratory. Excellent imaging capabilities are the most important criterion for exact valve positioning and thus optimal patient outcome. The overall setting of a hybrid operative theater is of specific value most importantly when emergency cardiopulmonary bypass or conversions to conventional surgery are required. This life-saving effect has certainly been demonstrated in some of the current studies. In addition to the environment, a dedicated team of cardiologists, cardiac surgeons, anesthesiologists, scrub nurses, and technicians are necessary for successful TAVR. In some centers the same integrated team performs both transfemoral and transapical approaches. TAVR is not a mature method yet; experience with it is limited and long-term results lacking. The clinical value has to be proven in a randomized, controlled trial. Without the results of such a comparison, the excellent long-term results of conventional aortic valve replacement make this therapy the gold standard. Patients with an acceptable risk profile should therefore continue to undergo the standard therapy. However, in the long run, valve therapy – for all valves - will certainly change from con-

ventional surgery with cardiopulmonary to the less invasive catheter techniques.

### A whole new spectrum of therapies

The hybrid operating room facilitates a whole new spectrum of cardiac surgical therapies and will therefore become an essential resource of every cardiac center. The trend towards hybrid techniques is more a revolution than an evolution. Stanford University is already including catheter techniques into training of cardiovascular surgeons. Within only two years the majority of all German heart centers started planning a hybrid OR. Cardiac surgeons around the world emphasize that cardiac surgery is moving rapidly towards the hybrid procedure and that the change is now, not in 5 years.

Siemens Healthcare has recognized these trends in surgery and offers a complete portfolio of high-end angiography systems for imaging in an OR environment. From a semi-mobile system for smaller ORs to the flagship of innovation Artis **zeeo**, the new angiography system based on robotic technology, Siemens delivers floor- and ceiling-mounted systems dedicated to surgery procedures. Especially Artis **zeeo** with

its flexible patient access, outstanding 3D imaging capabilities and its variable iso-center make Artis **zeeo** an ideal system for imaging in the OR.

### References

1. Walther T, Chu MW, Mohr FW. Transcatheter aortic valve implantation: time to expand? *Curr Opin Cardiol*. 2008 Mar;23(2):111-6.
2. Vahanian A, Alfieri OR, Al-Attar N, Antunes MJ, Bax J, Cormier B, Cribier A, De Jaegere P, Fournial G, Kappetein AP, Kovac J, Ludgate S, Maisano F, Moat N, Mohr FW, Nataf P, Pierard L, Pomar JL, Schofer J, Tornos P, Tuzcu M, van Hout B, von Segesser LK, Walther T. Transcatheter valve implantation for patients with aortic stenosis: a position statement from the European Association of Cardio-Thoracic Surgery (EACTS) and the European Society of Cardiology (ESC), in collaboration with the European Association of Percutaneous Cardiovascular Interventions (EAPCI). *Eur J Cardiothorac Surg*. 2008 Jul;34(1):1-8.
3. Reicher B, Poston RS, Mehra MR, Joshi A, Odonkor P, Kon Z, Reyes PA, Zimrin DA. Simultaneous "hybrid" percutaneous coronary intervention and minimally invasive surgical bypass grafting: feasibility, safety, and clinical outcomes. *Am Heart J*. 2008 Apr;155(4):661-7
4. Bacha EA, Marshall AC, McElhinney DB, del Nido PJ. Expanding the hybrid concept in congenital heart surgery. *Semin Thorac Cardiovasc Surg Pediatr Card Surg Annu*. 2007:146-50. Review.

### Contact

georg.nollert@siemens.com

