

Case Report: Astrocytoma

Laura Oleaga; Teresa Pujol
Radiology Department, Hospital Clinic, Barcelona. Spain

Patient history

43-year old male with a clinical history of seizures starting two weeks prior to admission in the hospital. No other medical or surgical relevant history. Blood test showed no abnormalities. Neurologic examination was normal, no neurological deficit was demonstrated. The patient underwent surgery. Complete tumoral resection was achieved.

Sequence details

T1W

TR: 400
TE: 2.65
FOV: 240
Thickness: 5 mm

FLAIR

TR: 9000
TE: 168
TI: 2500
FOV: 240
Thickness: 5 mm

DSWP

TR: 1550
TE: 32
FOV: 240
Thickness: 5 mm

syngo ASL

TR: 2500
TE: 11
FOV: 250
Thickness: 8 mm

Imaging findings

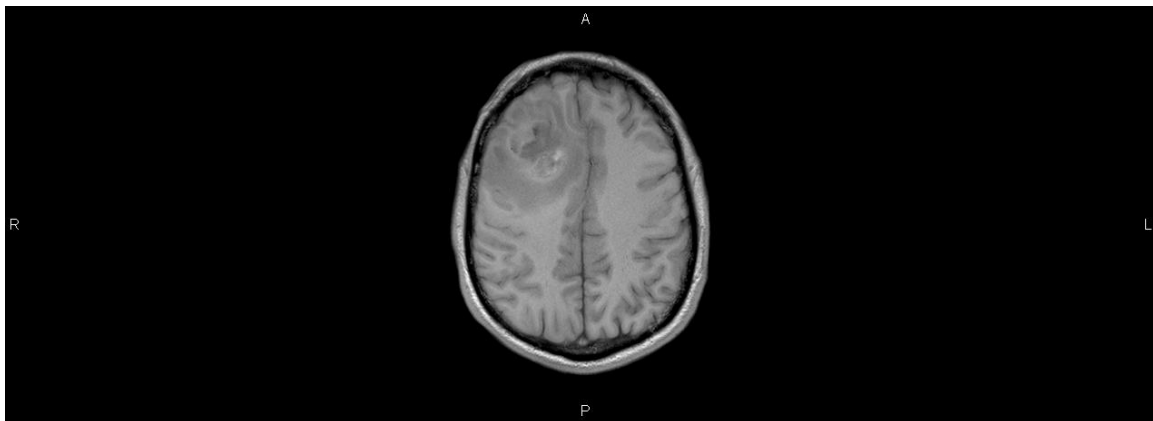


Figure 1: Axial T1W MRI. Heterogeneous mass in the right frontal lobe, demonstrating areas of high and low signal intensity and surrounding edema.

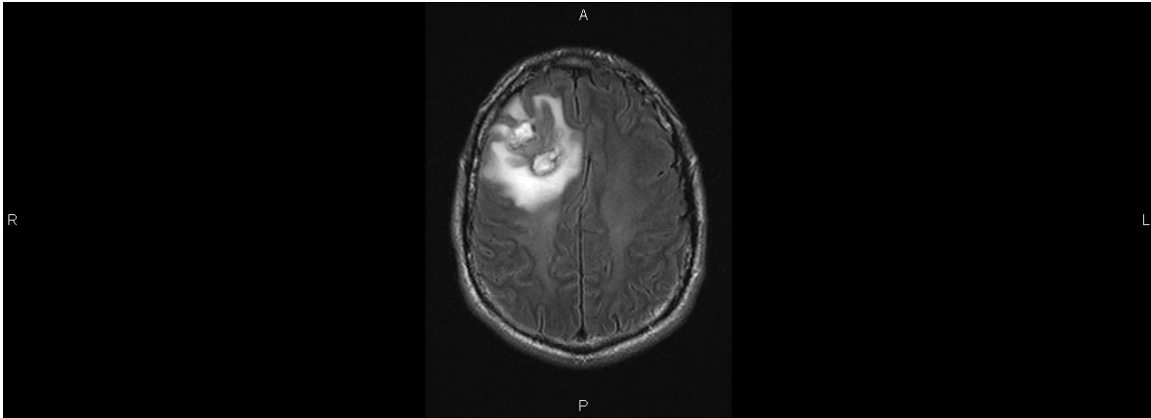


Figure 2: Axial FLAIR MRI. Frontal lobe lesion with non-homogeneous central areas and extensive peripheral high-signal intensity edema with mass effect.

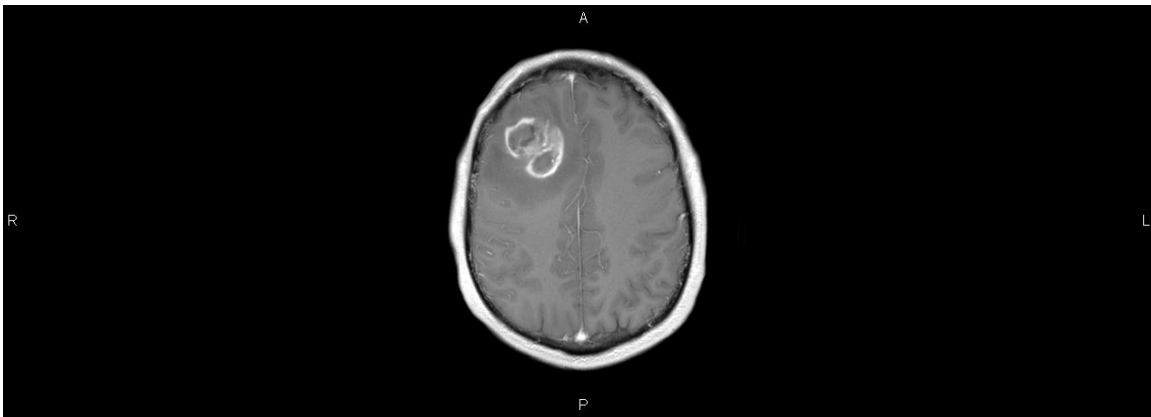


Figure 3: Axial Gadolinium enhanced T1W MRI. Frontal lobe lesion with peripheral irregularly enhancing rim.

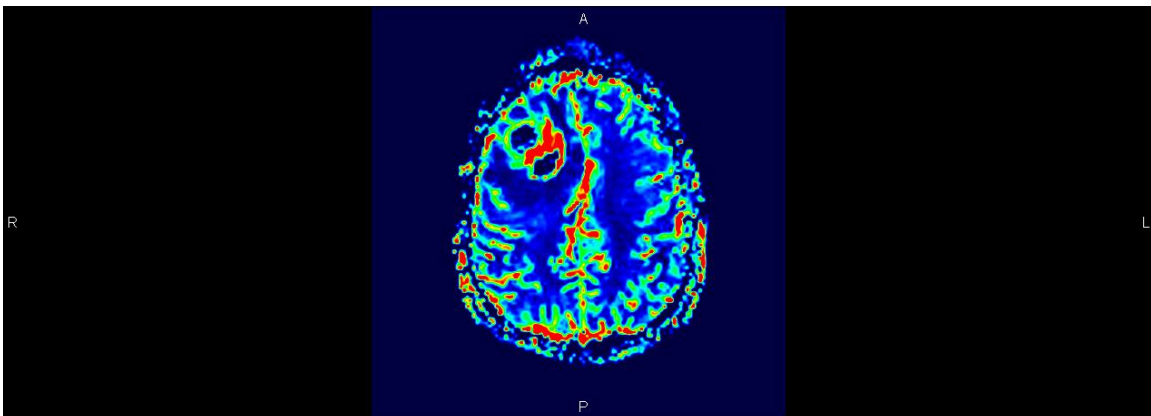


Figure 4: Axial DSWP (Dynamic Susceptibility-Weighted Perfusion) MRI. (rCBV map). Area of increasing rCBV in the periphery of the lesion corresponding to the rim of enhancement on the post-gadolinium image.

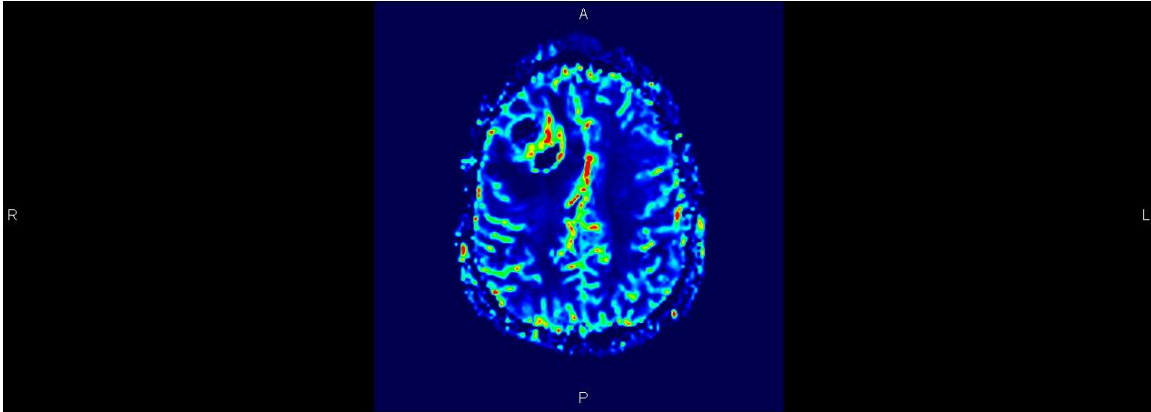


Figure 5: Axial DSWP (Dynamic Susceptibility Weighted Perfusion) MRI. (rCBF map). Increasing rCBF surrounding the tumor in the same area where the increase in rCBV was demonstrated.

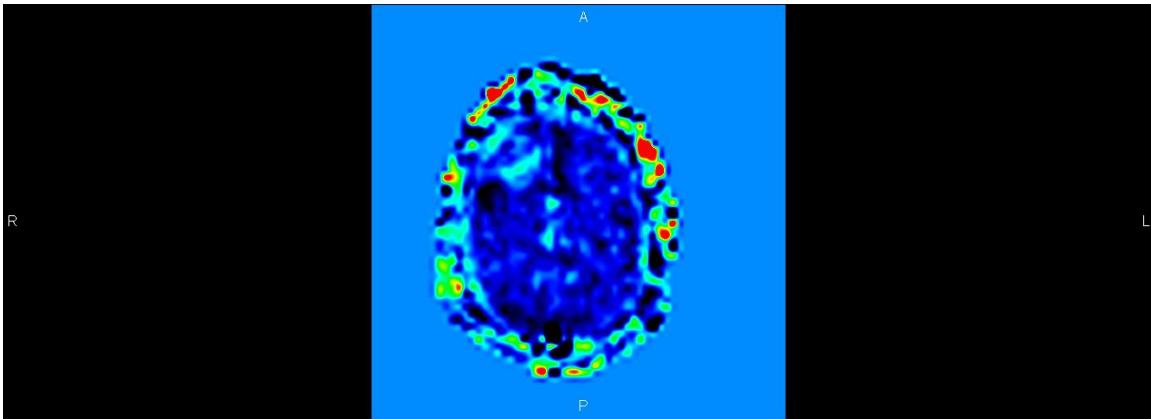


Figure 6: Axial *syngo* ASL. (rCBF map). Rim of increase in rCBF surrounding the lesion.

All images have been acquired using our 3T MAGNETOM Trio with software version *syngo* MR B15 and the 8-element head coil.

Comments and discussion

The patient underwent surgery with a complete removal of the lesion. Histopathologic analysis of the mass demonstrated an Astrocytoma Grade IV according to the OMS classification (2007).

Contact

Laura Oleaga
Radiology Department. Hospital Clinic.
C/Villarroel 170
Barcelona 08036
Spain
loleaga@clinic.ub.es