

# MRI

# Hot Topics



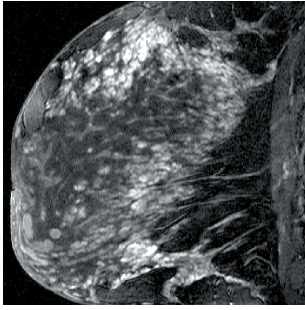
**Breast MRI**  
Improved Bilateral 3D Imaging

**SIEMENS**  
medical

# Breast MRI: Improved bilateral 3D Imaging

Helmuth Schultze-Haakh, Ph.D.

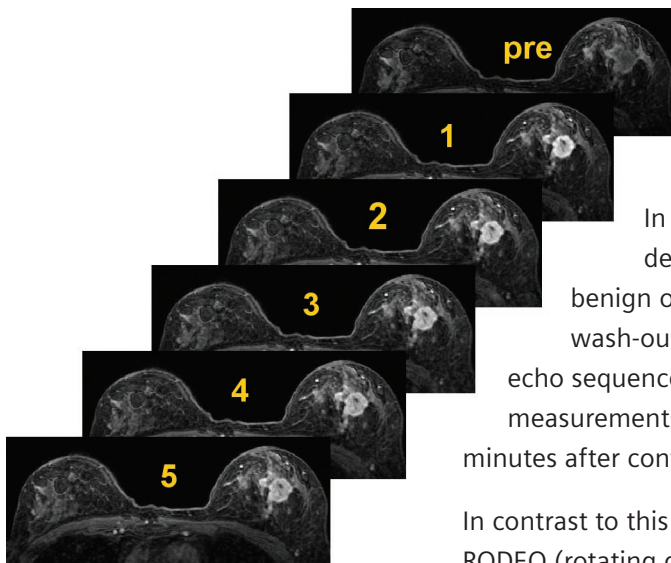
Siemens Medical Solutions USA, Inc., Iselin, NJ



**Figure 1:** Unilateral VIEWS (Sonata) post-contrast: 1.0 mm thick, 256x256 interpolated to 512, TA ca 5 minutes. Note the even fat suppression throughout the image.

## Introduction

Some types of breast cancer have a high incidence of contra-lateral occurrence. To provide the best service to the patient every breast evaluation for cancer should include not only the affected but also the contra-lateral breast. Since contrast agents (Gd) can only be administered once for the dynamic evaluation of contrast uptake, both breasts need to be scanned at the same time. The best orientation is transverse.



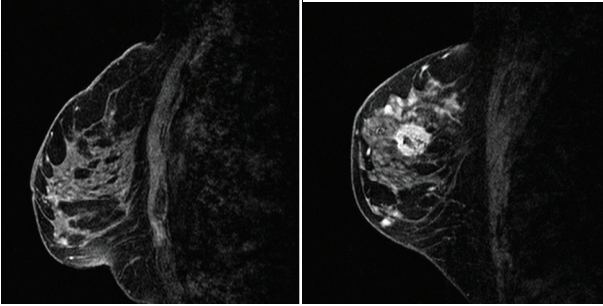
**Figure 2:** 3D dynamic bilateral fat-saturated breast MRI (Turbo Harmony): 1 pre-contrast followed by 5 post-contrast acquisitions at 1 minute increments. Note the good bilateral fat-saturation. The infiltrating ductal cancer enhances quickly (1 min) with a wash-out (signal decrease over time).

For breast MR imaging the debate in recent years has been whether to use high spatial resolution post-contrast acquisitions where the morphological structure of a lesion can be well circumscribed, or good temporal dynamic information for improved specificity of lesions.

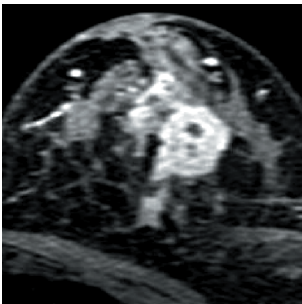
In their 1989 publication Werner Kaiser et al. [1] demonstrated a strong correlation of whether a lesion was benign or malignant by observing the contrast uptake and its wash-out behavior over time. This was done using fast 2D gradient echo sequences (2D FLASH) in a bilateral dynamic manner with multiple measurements of about 1 minute each lasting a time period of 5 to 10 minutes after contrast injection.

In contrast to this dynamic approach, Steve Harms et al. [2] introduced RODEO (rotating delivery of excitation off resonance) in 1994. This 3D technique uses a non-selective water rf-excitation (1-3-3-1 binomial) with a specialized transmit and receive coil to minimize fat signal. Due to the design of the coil it is not possible to acquire bilateral studies. Relatively high spatial resolution was obtained in a sagittal slice orientation. RODEO is a highly sensitive technique which led to an improved understanding of lesion structures. However, its specificity remained low. Figure 1 shows a unilateral acquisition in the sagittal orientation with water excitation obtained on a Magnetom Sonata. This Siemens protocol optimized for spatial resolution shows good structural detail in the breast and good fat suppression.

hot topics



**Figure 3:** Bilateral water-excitation 3D (VIEWS) sagittal acquisition (2 slabs). Same case as in Figure 2. Note: dark area in left breast lesion is from a previous needle biopsy. Approximately 8 minutes post-contrast injection (Harmony).



**Figure 4:** Coronal reconstruction of the left breast from sagittal acquisition data seen in Figure 3. Some image aliasing due to under-sampling in the partitions direction is present.

## Methods

Recently, high quality breast MR images have been acquired on various Siemens MR systems (1.0 T Magnetom Harmony, 1.5 T Magnetom Symphony and Sonata). Our primarily bilateral techniques available in the standard system configuration running syngo MR utilize both the important temporal information for greater lesion specificity and provide additionally high spatial

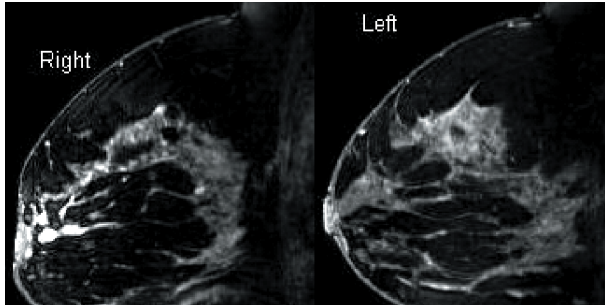
detail for lesion differentiation according to their structural differences. These techniques also use fat-suppression either with a spectral selective fat-saturation rf-pulse (3D dynamic see Figure 2) or a water-excitation binomial rf-pulse scheme (see Figures 1, 3, 5). Fat could obscure contrast-enhanced bright lesions if not suppressed. The advantage of fat-saturation in our 3D FLASH sequences for the dynamic contrast-enhance acquisition (fl3d\_ce) is that only one fat-saturation pulse is applied for each pass through the partitions loop, keeping the TR and thus the acquisition time short. This is important in order to maintain good temporal resolution (1 minute) while optimizing the spatial resolution within this time constraint. However, if many partitions are being acquired, some fat relaxation may occur. In contrast, water-excitation only stimulates the water spins and shows thus improved fat suppression effects since every rf-pulse uses a spatial-spectral selectivity by incorporating a sinc envelope into a 1:2:1 binomial excitation scheme [3]. Each binomial rf-excitation requires more time than a simple alpha sinc pulse thus extending the TR and the acquisition time. This in turn would limit the spatial resolution in a dynamic acquisition or prevent this sequence to be used as a dynamic one altogether.

## Results

The 3D dynamic contrast-enhance technique was described elsewhere (Breast MRI: Importance of Dynamic 3D). Volume Interpolated Examinations with Water-Stimulation (VIEWS), a 3D gradient echo sequence, can produce voxel sizes down to  $0.7 \times 0.7 \times 0.7 \text{ mm}^3$ . This can be applied unilaterally in a sagittal plane (Figure 1), the esthetically preferred orientation, or even bilaterally in a transverse (fl3d\_vibe) or a double slab sagittal orientation (gre) as seen in Figure 3 (Harmony) and Figure 5 (Symphony).

Multi-planar reconstruction (MPR) of this often close-to-isotropic voxel series can assist in viewing the images in other planes (Figure 4).

High quality shimming is important for good fat suppression. The air-tissue interface in a peculiar geometry (as is the case in breast imaging) becomes a challenge. However, syngo MR with its shim phase plot has solved this problem. Good bilateral fat-suppressed images have become commonplace on syngo MR systems (Figure 2).



**Figure 5:** *Bilateral VIEWS (Symphony). The sequence with an acquisition time of 5:50 minutes was run after the 3D dynamic scans (about 8 minutes post-contrast), voxel size: 0.7 x 0.7 x 0.8.*

## Conclusion

Our new VIEWS technique not only improves the fat-saturation effect but can also be applied bilaterally with even better spatial resolution (Figure 3 and 5). In a double slab approach the extended TR can improve signal-to-noise and contrast-to-noise in these T1-weighted post-contrast series (Figure 5) without an increase in time compared to a single slab technique with the same spatial resolution.

If combined with a 3D dynamic contrast-enhanced bilateral examination, a complete breast evaluation can be achieved. The delayed contrast-enhanced VIEWS technique with its high resolution and good fat-suppression can show lesions which otherwise might not become apparent, as for example ductal carcinoma in situ (DCIS).

Both the 3D dynamic fat-saturated and the 3D high resolution water-excitation techniques are standard on all syngo MR based systems with the Advanced Angio option. A bilateral circularly polarized array breast coil is essential for high signal-to-noise and contrast-to-noise acquisitions.

## Acknowledgements

Special thanks go to Dr. Bruce Porter and Dr. Michael Middleton for their educational and clinical input as well as valuable image data; to Dr. Cynthia Sherry and Todd Frederick for their comparison data and feedback; and to Dr. David Thomasson for his constant advice.

## References

1. Kaiser, WA, et al. MR imaging of the breast: fast imaging sequences with and without Gd- DTPA. Preliminary observations, Radiology 1989; 170: 681-686.
2. Harms, SE, et al. MR imaging of the breast with rotating delivery of excitation off resonance: clinical experience with pathologic correlation, Radiology 1994; 187: 493-501.
3. Pooley, RA, et al. Fat-suppressed multi-slab FLASH 3D imaging, to be published, 2002.