

High-end Imaging in Asia Pacific

Emergent Antithrombotic Therapy on MCA Stroke with syngo DynaCT

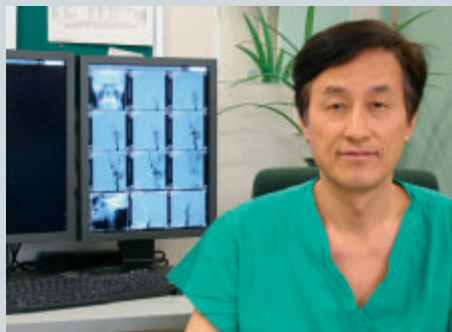
Courtesy of Dae Chul Suh, MD
Department of Radiology, Asan Medical Center, University of Ulsan, College of Medicine, Seoul, South Korea

Patient history

A 67-year-old male presented with aphasia and right-sided extremity weakness.

Diagnosis

Diffusion-weighted image [Fig. 1] showed ischemic changes in watershed area of the left deep middle cerebral artery (MCA) territory. MR perfusion dem-



onstrated a delayed blood supply in the left MCA territory [Fig. 2]. A severe symptomatic left M1 stenosis (arrow) could be revealed by a cerebral angiogram [Fig. 3].

Treatment

An angioplasty with stent placement was planned. Good patency of the stent was demonstrated by a cerebral angiogram

[Fig. 4]. Additionally, the interventional procedure was checked immediately after the treatment and no evidence of infarct or hemorrhage could be detected [Fig. 5].

Follow-up

Two days later a diffusion-weighted image showed no significant change of the ischemia [Fig. 6]. Therefore a CT perfusion was performed 3 days later and by this an image with a symmetric perfusion status in both hemispheres was obtained [Fig. 7].

Diagnosis and Treatment of an ICA Re-occlusion with syngo InSpace 3D

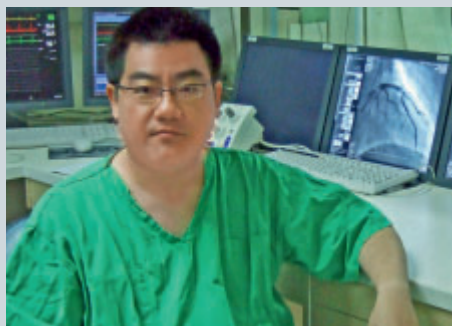Courtesy of Hsien Li Paul Kao, MD
Department of Internal Medicine, National Taiwan University Hospital, Taipei, Taiwan

Patient history

73-year-old man suffering from chronic right internal carotid artery occlusion (ICAO), detected by ultrasound 2 months prior to admission. Patient complained of transient ischemic attacks despite optimal medical management.

Diagnosis

Objective right hemisphere hypo-perfusion had been documented by perfusion CT. Endovascular re-canalization using



coronary CTO technique and device was performed with placement of a self-expanding stent in the proximal ICA. The angiographic result was good with swift anterograde flow into the right hemisphere. Immediate post-procedure ultrasound study showed normalized ophthalmic artery (OA) flow direction. One month later, however, reversal OA flow direction was noted. And perfusion CT [Fig. 1] showed recurrence of right hemisphere ischemia. In suspicion of ICA re-occlusion, the patient was re-admitted.

Treatment

The follow-up angiography revealed a patent stent at proximal ICA [Fig. 2], but an expanding pseudo-aneurysm compressing the true lumen was noticed in the distal cervical ICA [Fig. 3]. Rotational angiography with 3-dimensional reconstruction [Fig. 4] was performed to identify the narrow inlet of the aneurysmal sac. A coronary balloon-expandable stent was then implanted in the true lumen, jailing the inlet of the pseudo-aneurysm [Fig. 5]. The OA flow direction was normalized again after the second intervention. One month later a CT-scan revealed improved right hemisphere perfusion [Fig. 6]. CT angiography also demonstrated significant reduction in the size of the pseudo-aneurysm sac, with widely patent proximal and distal cervical ICA stents [Fig. 7]. The patient remained asymptomatic and well with regular out-patient clinic visits. His most recent visit was in April 2007.

These clinical case studies were conducted in two of the leading hospitals in Korea and Taiwan. Siemens constantly helps physicians around the world to treat their patients with greater care and confidence. These cases studies are proof that innovations from Siemens Healthcare are contributing to create global standards in healthcare excellence.

1 Diffusion-weighted image with watershed area along the left deep middle cerebral artery.

2 MR perfusion image visualized a delayed time to peak in the left MCA territory describing an ischemic change.

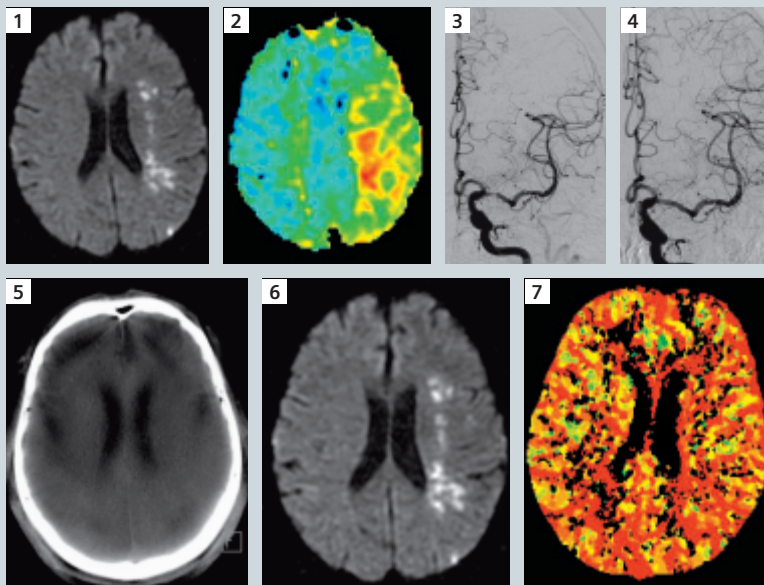
3 Obvious stroke in the middle cerebral artery.

4 The angiogram shows the stented MCA.

5 *syngo* DynaCT run to check the evidence of infarct of hemorrhage due to any trauma during the intervention.

6 The ischemia was still detectable although good patency of the stent.

7 Symmetric perfusion status in both hemispheres revealed by CT perfusion.



1 CT perfusion demonstrates a recurrence of ischemia in the right hemisphere.

2 Stented proximal ICA shows no obvious aberration with angiography.

3 Frontal angiography with a pseudo-aneurysm in the distal cervical ICA.

4 Three-dimensional demonstration of the pseudo-aneurysm with *syngo* InSpace3D.

5 Stenting of the pseudo-aneurysm controlled with angiography.

6 A second post-stenting control with a final CT perfusion.

7 The reduced size of the pseudo-aneurysm demonstrated with CT angiography in frontal view.

