

# High Spatial and Temporal Resolution MRA of the Entire Peripheral Vascular System Using a New 3D Time-Resolved MRA Technique (*syngo* TWIST)\*

F. M. Vogt<sup>1</sup>; S. Maderwald<sup>1</sup>; K. Kröger<sup>2</sup>; G. Laub<sup>3</sup>; R. Kroeker<sup>3</sup>; P. Schmitt<sup>4</sup>; H. H. Quick<sup>1</sup>; J. Barkhausen<sup>1</sup>

<sup>1</sup>Department of Diagnostic and Interventional Radiology and Neuroradiology, University Hospital Essen, Essen, Germany

<sup>2</sup>Department of Angiology, University Hospital Essen, Essen, Germany

<sup>3</sup>Siemens Medical Solutions, USA

<sup>4</sup>Siemens Medical Solutions, Erlangen, Germany

## Introduction

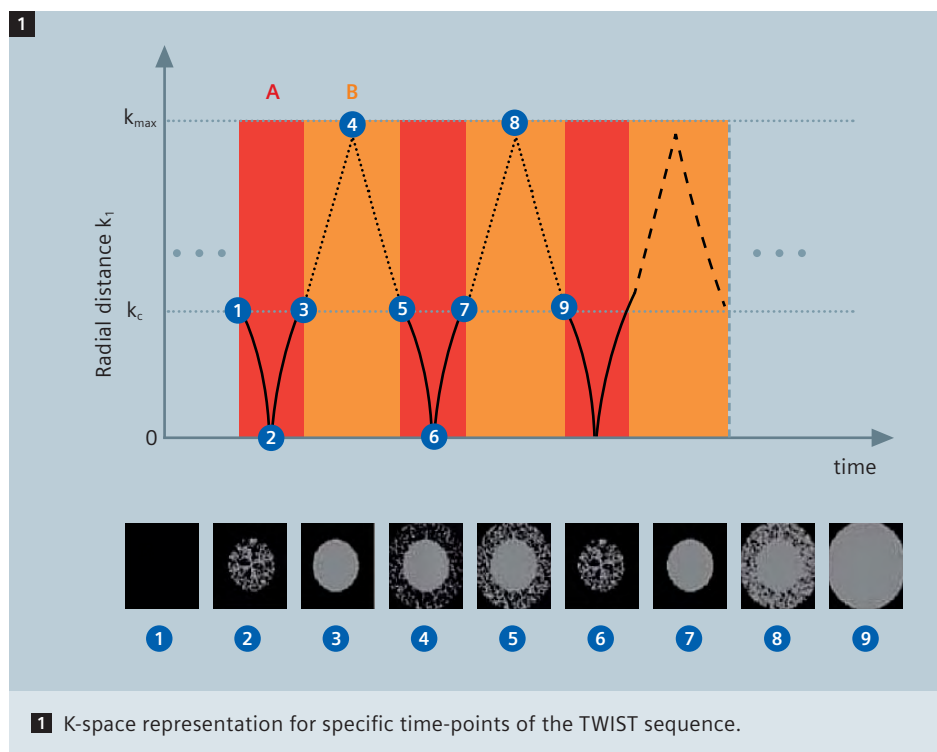
Bolus-chase magnetic resonance angiography (MRA) protocols collecting multiple high resolution data sets covering the arterial vessels from the renal arteries down to the pedal arteries must be considered as the state of the art technique and imaging modality of first choice in patients suffering from peripheral arterial

disease (PAD). Although the technique has been used in clinical routine for about 10 years, MRA of the run-off vessels remains challenging. Optimal timing of the contrast injection is still difficult but crucial because inadequate timing may result in poor arterial opacification or venous overlay. However, even if technically per-

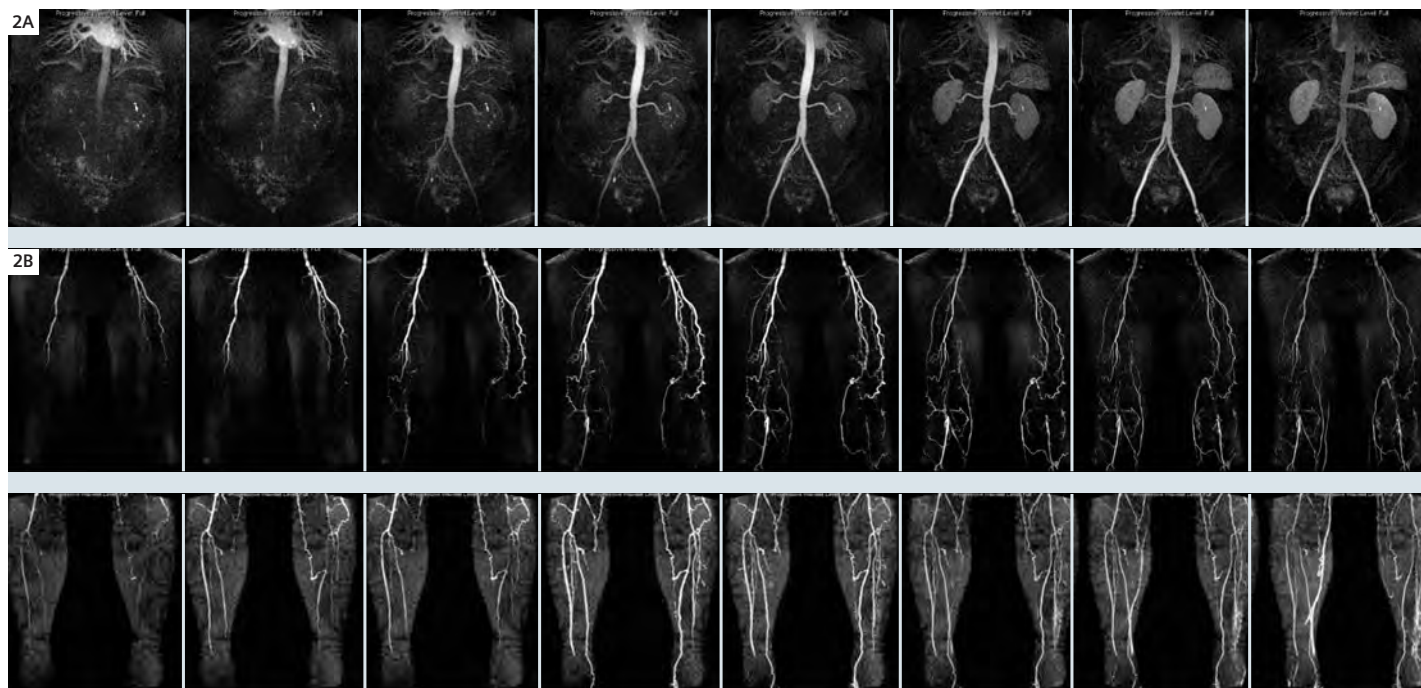
fect, standard MRA techniques only provide morphologic information whereas digital subtraction angiography as the standard of reference collects several images during the first-pass of the contrast agent providing additional information on flow. To overcome these limitations at least for the infrapopliteal arteries hybrid MRA techniques combining time-resolved MRA of the lower legs and bolus chase MRA for the pelvis and upper legs have been introduced. The results of hybrid MRA are encouraging but until now dynamic MRA requires to sacrifice spatial and dynamic information about arterial filling and venous enhancement would be desirable not only in the infrapopliteal vessels. Therefore our study aimed to develop a triple injection scan protocol for dynamic, high-resolution, isotropic MRA of the entire peripheral vascular system applying a recently developed time-resolved 3D MRA sequence (*syngo* TWIST).

## Methods

Ten patients (mean age 64) with clinically documented PAD underwent ceMRA contrast-enhanced MRA collecting dynamic 3D data sets at three consecutive, slightly overlapping stations. All imaging was per-



1 K-space representation for specific time-points of the TWIST sequence.



**2** 83-year-old male patient with PAD. Multiple stenoses and occlusions of the upper and lower limb arteries can be depicted.

formed on a 1.5 T system with Tim (Total imaging matrix) technology (MAGNETOM Avanto, Siemens, Medical Solutions, Erlangen, Germany). Two flexible phased array coils and a dedicated peripheral vasculature coil were used for signal reception. 25 consecutive T1-weighted 3D datasets were acquired in coronal planes following automatic injection of 5 cc Gadovist at 3cc/sec for each station using the TWIST sequence. The TWIST sequence divides the kspace into a central (A) and a peripheral region (B). While region A is completely sampled region B is undersampled by a factor of  $n$ . The k-space trajectory within region B follows a spiral pattern in the ky-kz plane with every trajectory in B slightly different, depending on the undersampling factor  $n$ . The individual trajectories of B are twisted into each other as shown in the snapshots of k-space filling during the execution of the TWIST sequence (Fig.1). Parallel acquisition (GRAPPA, acceleration factor 2) was applied and spatial resolution and coverage were adapted for each station: Abdominal/pelvic station: (slices 80;

spatial resolution  $1.3 \times 1.3 \times 1.3 \text{ mm}^3$ ; temporal resolution true/interpolated 4.5/2.3 s); thighs: (slices 64; spatial resolution  $1 \times 1 \times 1 \text{ mm}^3$ ; temporal resolution true/interpolated 5.1/2.6 s); lower limbs: (slices 64; spatial resolution  $1 \times 1 \times 1 \text{ mm}^3$ ; temporal resolution true/interpolated 3.9/2.0 s). Reconstruction times were evaluated for all data sets. The MRAs were evaluated by two experienced radiologist in consensus and all significant stenoses ( $> 50\%$ ) as well as all vessel occlusions were recorded. All patients underwent digital subtraction angiography of the aorto-iliac and lower extremity arteries within 24–48 hours of the MRA exam, which served as the standard of reference.

## Results

All exams could successfully be performed; no technical or reconstruction problems occurred. A total number of up-to 2000 images per station were reconstructed in about 6 minutes. Due to the dynamic data acquisition venous overlay did not hamper the assessment

of the arterial system in any station.

The number of evaluable segments on the MRA data sets was equal to DSA. Significant stenoses ( $> 50\%$ ) as well as occlusions were correctly characterized in all cases using DSA as the standard of reference.

## Discussion

The triple TWIST protocol is a robust and reliable technique for MRA of the peripheral arterial system. Compared to other MRA protocols it provides important advantages: 1. perfect arterial opacification of all vessels without any timing issues; 2. no venous overlay in the entire peripheral vascular system; 3. functional information combined with high resolution morphologic information. Hardware improvements will definitely further reduce the reconstruction time in the near future and this approach may become the state of the art imaging protocol for MRA in PAD patients.

\*Some of the concepts and information presented in this paper are based on research and are not commercially available in the U.S.