

# Improved Planning Strategies for Reduced Imaging Time

Serban Mateiescu

Grönemeyer Institute of Microtherapy, Bochum, Germany

## Introduction

Routine examinations of the brain are usually based on T1 and T2-weighted TSE measurements in all three orientations. The thickness is set to 6 mm. For certain questions, additional measurements are performed before and after contrast administration with a thinner slice thickness as well as 3D images to improve the anatomic display.

In these cases, more exact slice positioning would be advantageous. We are using (when routine sequences are insufficient) quick measurements as auxiliary tools. We would like to demonstrate this by using 2 examples, acoustic neurinoma and pituitary tumors.

## Methods

MR examinations involving above tumors are demanding. They require long measurement times (approx. 5 minutes) plus

additional contrast administration. A more detailed display of the area to be scanned improves as well as simplifies slice planning and errors are completely eliminated. Depending on the needs, several fast TrueFISP measurements are applied in the orientations required. A measurement takes approximately 10 seconds, has a slice thickness of 3.5 mm and is suitable only for planning the next sequence.

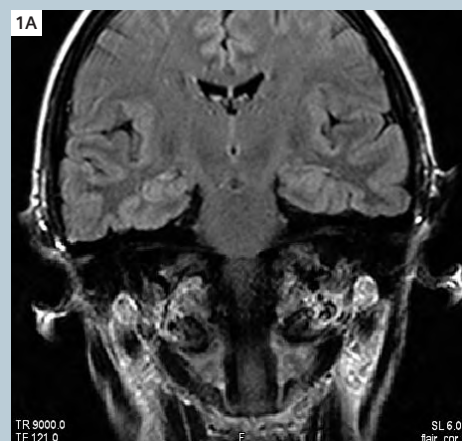## Acoustic neurinoma

In addition to standard T1 and T2-weighted TSE axial measurements, the routine for this type of examination includes a STIR sequence in coronal orientation. The next thin-slice axial or 3D sequences should be planned on the basis of these coronal images. To provide for improved slice positioning, we use a quick coronal measurement.

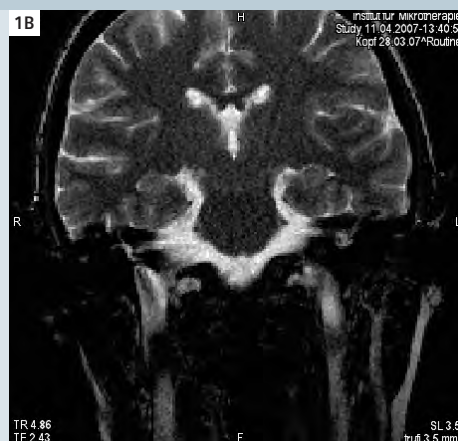As shown previously in figures 1A and B, the TrueFISP image is far superior for planning axial views. We used it to plan a 2:46 min 3D CISS (Fig. 2), 36 slices, 0.7 mm slice thickness with a basic resolution of 257 x 384.

The axial T1-weighted SE measurement after contrast administration was also planned on TrueFISP images. Axial 3D CISS images were used for coronal T1-weighted SE measurements. Both measurements used a 512 matrix with 15 slices of 2 mm each. Acquisition time was 5 minutes each which is considered standard for this type of measurement.

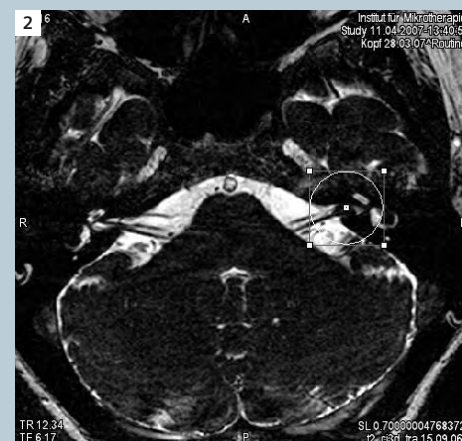
More exact planning reduced the slices for 3D CISS from 56 to 36. As a result, resolution could be increased from 256 to 384 while the slice thickness was reduced from 0.8 to 0.7. This means that we saved nearly one minute on scan time.



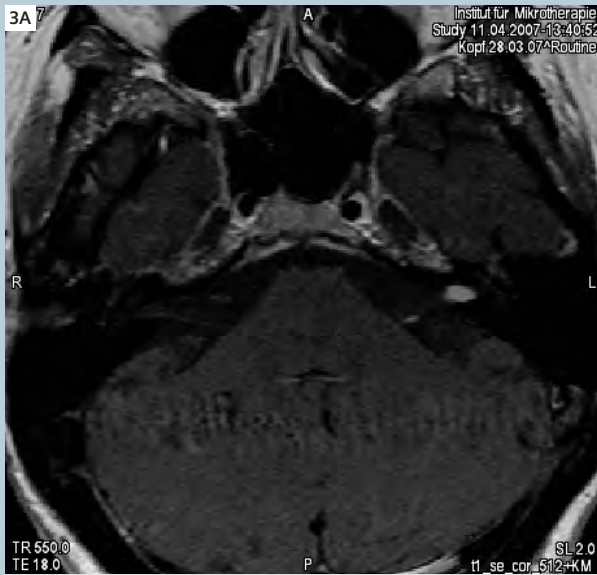**1A** 6 mm coronal FLAIR.



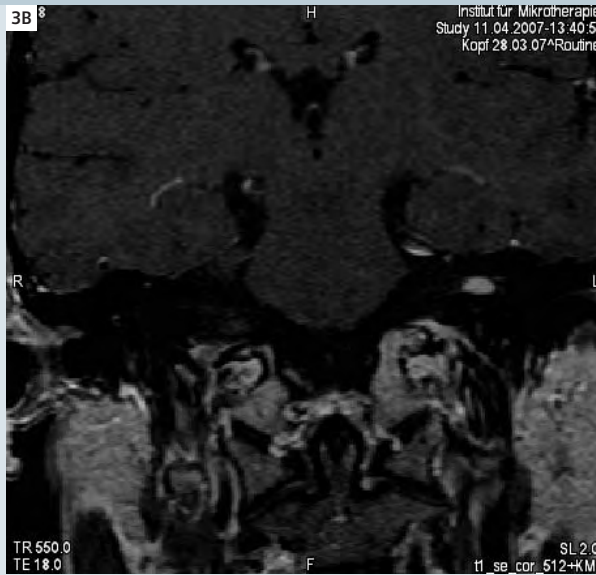**1B** 3.5 mm coronal TrueFISP.



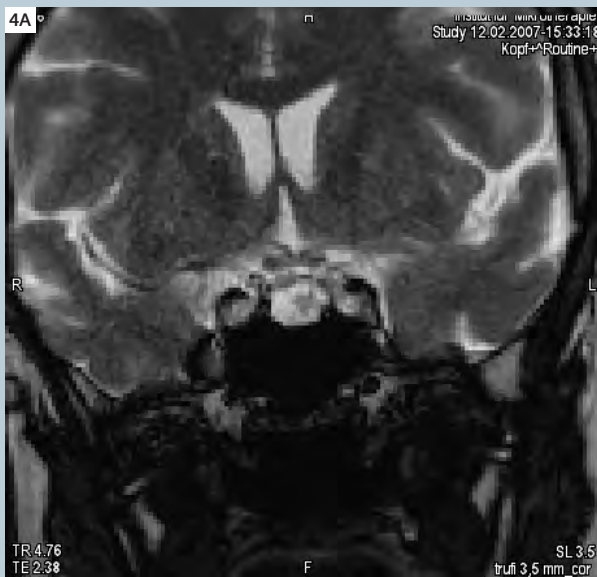**2** 3D CISS with lesion.



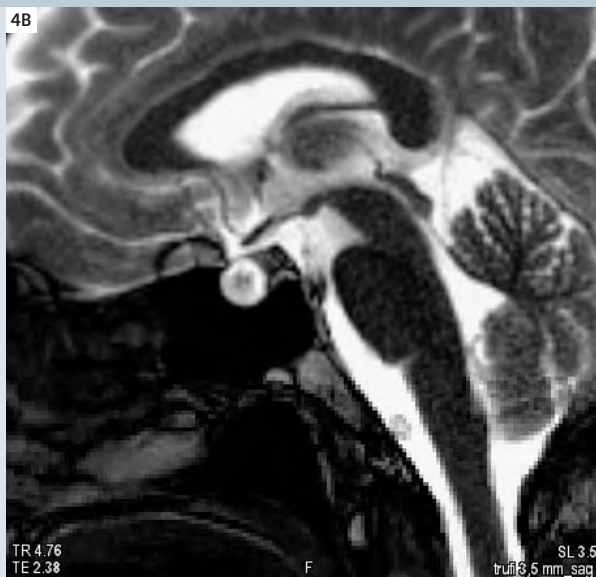**3A** Axial SE with contrast.



**3B** Coronal SE with contrast.



**4A** Coronal TrueFISP, TA = 8 s.



**4B** Sagittal TrueFISP, TA = 9 s.

For the T1-weighted measurement, we were able to reduce the slice thickness from 3 to 2 mm, increasing the image quality at the same time.

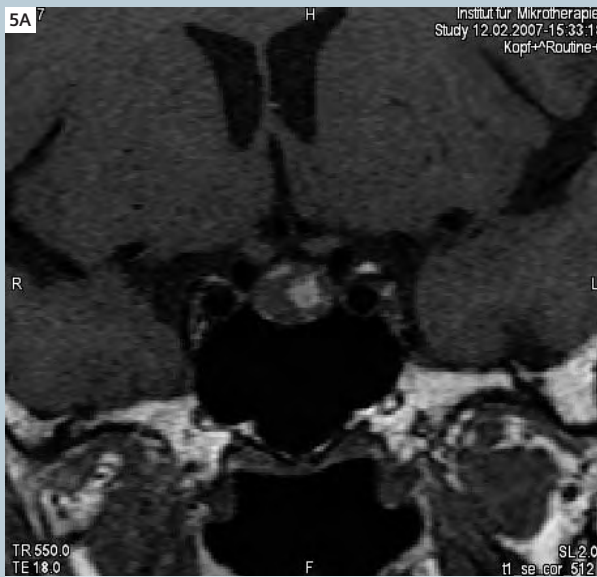
### Pituitary tumor

The same principle as described above was used. Due to 2 quick TrueFISP se-

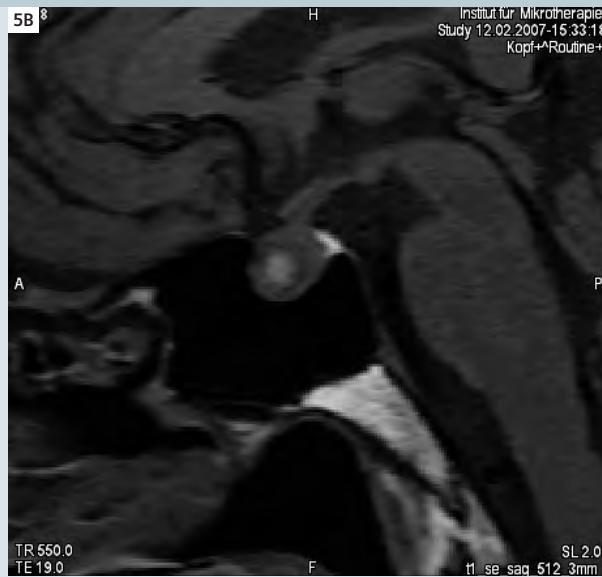quences in the sagittal and coronal orientation, we were able to improve slice positioning.

Additional, thin-sliced measurements were planned on these views. Since these examinations were just control examinations, measurements were performed without contrast administration.

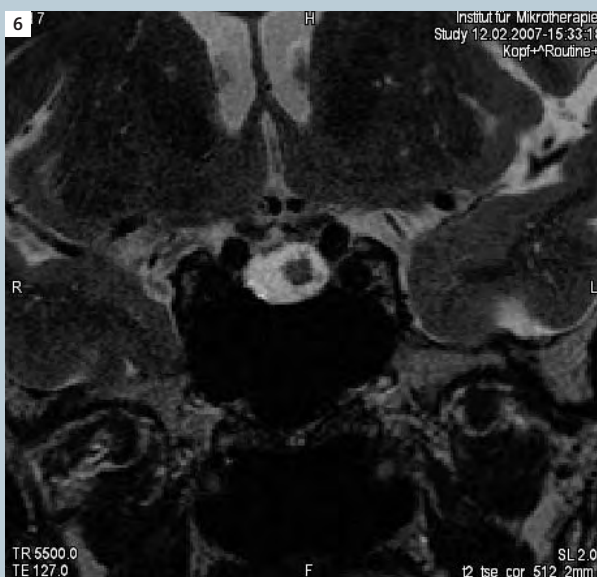In addition, a coronal T2-weighted TSE measurement was performed: thin-sliced, high resolution with iPAT (integrated Parallel Acquisition Techniques) 15 slices, 2 mm slice thickness, 4 acquisitions with a 323 x 512 image matrix.



**5A** Coronal SE, TA = 5:21 min.



**5B** Sagittal SE, TA = 5:25 min.



**6** Coronal T2-weighted TSE, TA = 3:25 min.

## Conclusion

By using fast acquisition times, it is possible to obtain useful images due to better positioning. These images allow for highly exact planning with fewer slices and reduced voxel size. This leads to an overall reduction in examination time. However, we have applied part of the time gained to image resolution in

order to increase the image quality. This method is not limited to examinations of the skull. It can be used for all types of examinations. It is desirable that the patient remains in the scanner for an additional minute. During this time, the faster sequences can be applied instead of looking at a 5-minute measurement

time and realizing that the planning was not successful which means that the measurement has to be repeated.