

Case Report: Role of MRI Imaging in a Gynecological Emergency of Ectopic Pregnancy

Dr. N. Dahmen, M.D.

Klinik St. Josef, St. Vith, Belgium

Patient history

A 16-year-old female presented in our emergency room with complaints of intermittent abdominal pain for more than one month. Biology tests revealed anemia, augmented neutrophile leucocytes and an inflammatory condition. Ultrasound examination showed a large pelvic hemoperitoneum. As the patient was in a stable condition, an MRI exam was performed.

Sequence details

1. Coronal and transverse T2-weighted Turbo Spin Echo (tse) with *syngo* BLADE to reduce respiratory motion of the pelvis. TR/TE = 4000/106, FoV of 280 mm (FoV phase 100%), 30 slices of 3.5 mm coronal, 5 mm transverse, 2 concats, base resolution 320 (phase resolution 100%), BW = 363 Hz/pixel, TF = 35, echo spacing = 5.88 ms, no fatsat, TA = 2 min 18 s
2. Transverse T1-weighted tse with fatsat, TR/TE = 434/12, FoV = 280 (FoV phase 75%), Base resolution 448 (phase resolution 75%), TF = 3, fatsat
3. Transverse T2-weighted tse with *syngo* BLADE, using fatsat

4. T1-weighted transverse VIBE in pre and post contrast in 3 planes at different injection times: TR/TE = 4.68/2.17, FoV coronal = 400 mm (FoV phase 100%), FoV transverse/sagittal = 320 (FoV phase 75%), 72 slices of 2 mm (cor) and 40 slices of 3 mm (tra/sag), flip angle 12°, base resolution 320 (phase resolution 66%, slice resolution 64%), BW = 400 Hz/pixel, fatsat, breathhold

Results

After realization of the tse_BLADE T2-weighted sequences, a hemoperitoneum and a mass – of which the 'onion-tunic' is clearly depicted – is seen in the adnexal area. After gadolinium injection, late injection phases show peripheral contrast uptake of the mass and a slow uptake of a tubular structure.

This finding was suggestive of a peritoneal abortion of an ectopic pregnancy (also called extra uterine pregnancy) with reactionary salpingitis on the right and a hemoperitoneum as result of venous rupture. The right Fallopian tube is intact without rupture.

Discussion

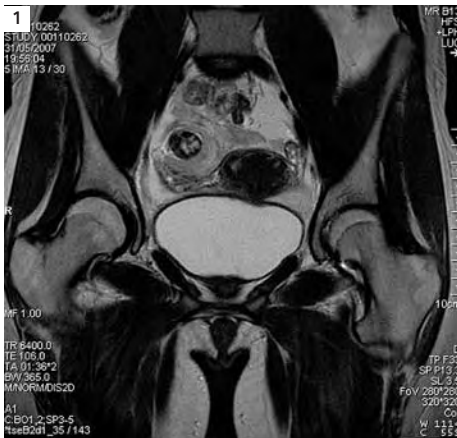Ectopic pregnancy (EP) as detected after T2 tse BLADE sequences. Application of the BLADE technique reduces artefacts, originating from peristaltic movement

and reducing respiratory movements of the frontal fat layer. Consequently, saturation bands are no longer used. BLADE sequences have a shorter acquisition time and permit a final diagnosis in a very short time. In the future, these sequences can be used as unique T2 sequence in a fast, pre operative phase, insofar as the vital condition of the patient is not in danger. The T2-weighted BLADE sequences should be completed by fast, dynamic T1-weighted VIBE sequences in search of active bleeding.

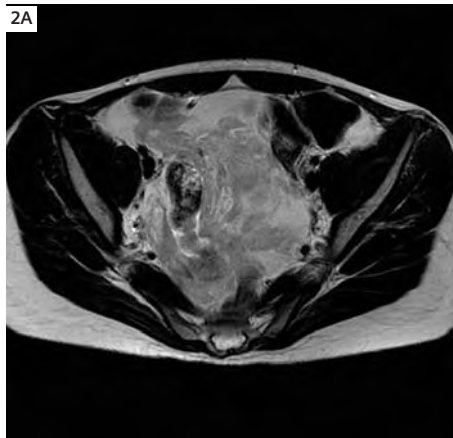
Conclusion

The abortion of ectopic pregnancy was confirmed by laboratory tests, showing a positive β -hCG (human Chorionic Gonadotropin hormone), and through Pathology. No salpingo-ophorectomy had to be performed.

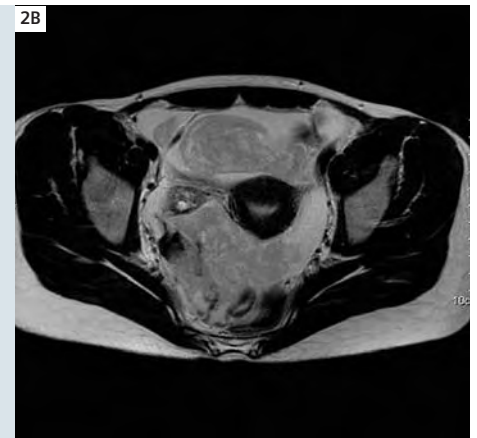The T2-weighted *syngo* BLADE sequence, in combination with T1-weighted dynamic VIBE imaging is a good emergency gynecological protocol.



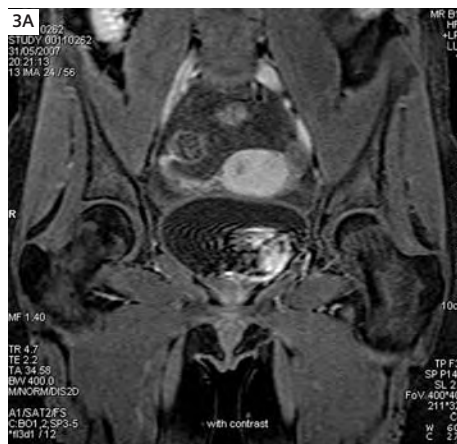1 Coronal T2-weighted TSE sequence with syngo BLADE: the fundus of the uterus, right adnexal and an ectopic pregnancy (EP) with abortion in the peritoneum.



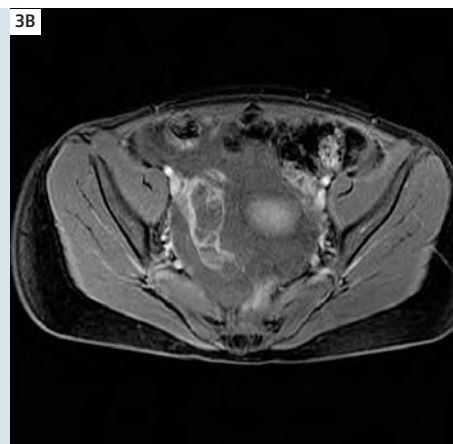2A Transverse T2-weighted Turbo Spin Echo (tse) sequence with syngo BLADE: EP with hemoperitoneum.



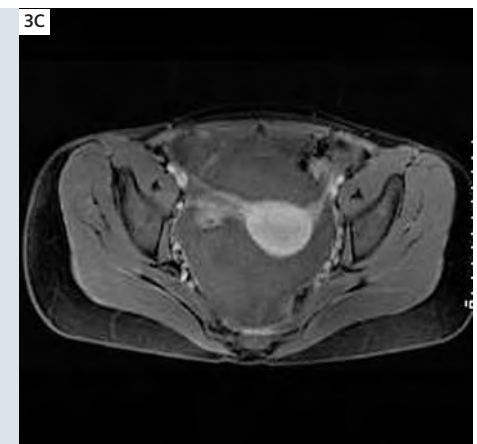2B Transverse T2-weighted tse with syngo BLADE: hemoperitoneum, right adnexal, round ligament, large ligament and posterior part of the mass.



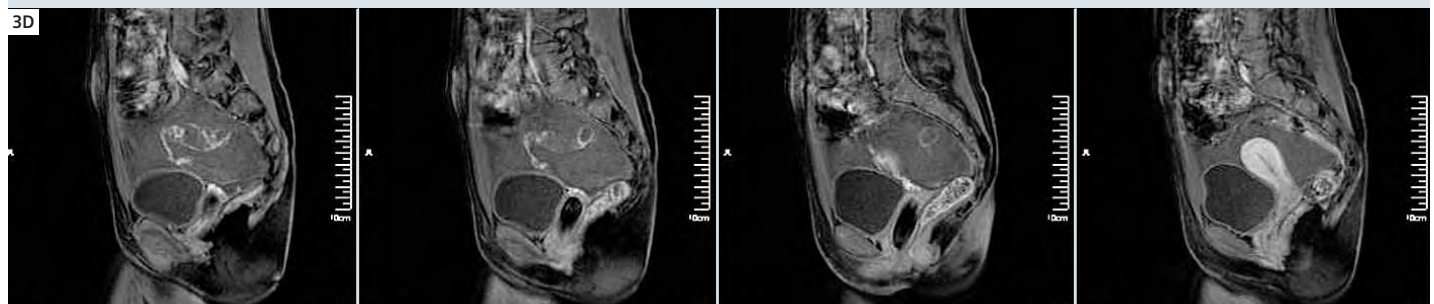
3A Coronal VIBE post contrast: contrast uptake of the right adnexal and around the expulsion material, showing a slow bleeding tubo-ovarian vasculature.



3B Transverse VIBE late post contrast: ring enhancement of the expulsion material, showing a tubo-ovarian bleeding.



3C Contrast uptake of the large ligament and of the right adnexal, in contact with peritoneal abortion of ectopic conception material.



3D Sagittal VIBE post contrast: enhancement of the right adnexal with active bleeding, causing the hemoperitoneum.