

# Dynamic VIEWS, InterVIEWS, RADIANT and Tim: Advanced MR Techniques for Breast Cancer Imaging

Bruce A. Porter, M.D., FACR<sup>1</sup>; Helmuth Schultze-Haakh, Ph.D.<sup>2</sup>

<sup>1</sup>First Hill Diagnostic Imaging – Swedish Medical Center, Seattle, Washington, USA

<sup>2</sup>Siemens Medical Solutions USA, Inc., Cypress, CA, USA

## Introduction

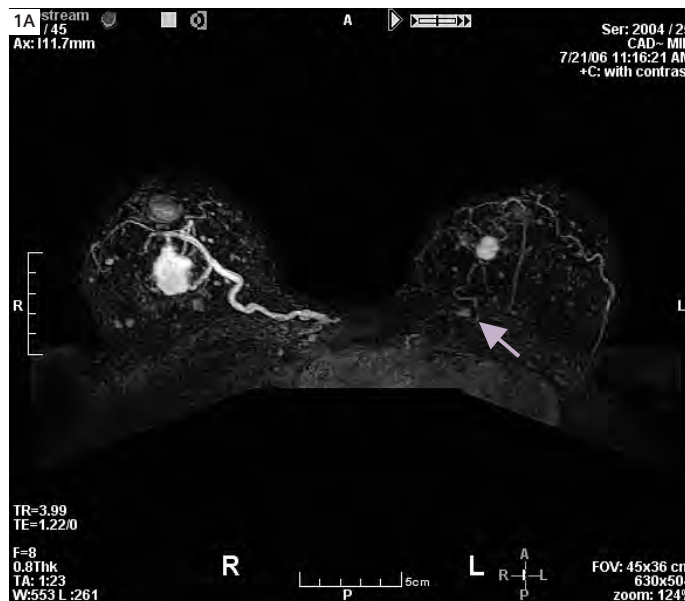In the early 1990's initial clinical applications of magnetic resonance imaging of the breast, relied either on a series of low-resolution dynamic (kinetic) images or longer, high-resolution (morphologic) images to differentiate benign from malignant processes. Current MR equipment, however, allows a hybrid technique, providing both kinetic data and high-resolution morphologic information in one exam. VIEWS: Volume Imaging

with Enhanced Water Signal, developed for Siemens MR systems, is a high-resolution 3-dimensional gradient-echo acquisition technique with fat suppression. The hybrid form combines time limited acquisitions, DynamicVIEWS, and an additional higher resolution acquisition interspersed between the DynamicVIEWS: InterVIEWS. The kinetic and morphologic approaches each have their individual strengths and limitations; however, the combination of

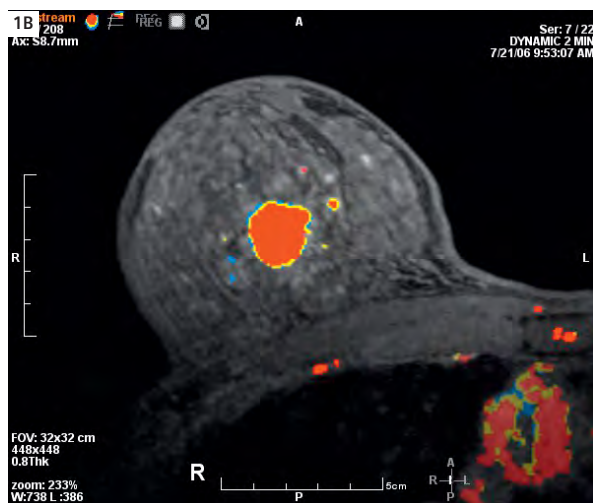
these methods provides functional information (enhancement curves) and thin section, high-resolution 3D data sets with great anatomic detail, thus improving characterization of enhancing masses. This report illustrates the complementarity of these two methods and the current status of MR breast imaging, with a focus on key situations where this unique exam impacts, often substantially, clinical care of patients with known or suspected breast cancer.

## Case 1: Multicentric and occult contralateral invasive breast cancer

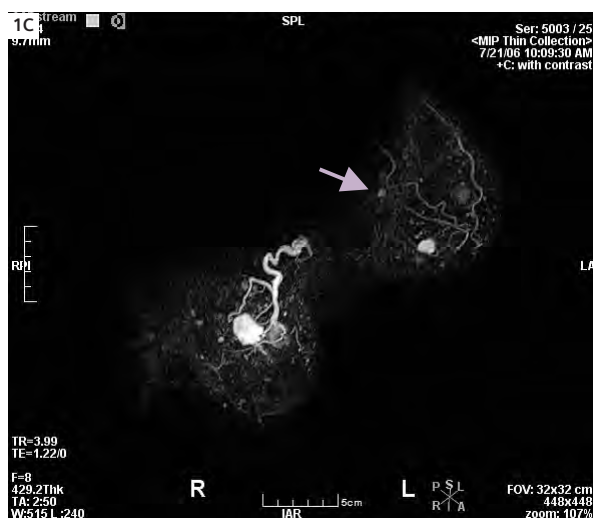This 48-year-old woman, a health care provider herself, noticed a new density in her left breast. Her mammograms were extremely dense, with no indication of cancer, asymmetrical masses, or malignant-type calcifications, even in retrospect. An ultrasound-guided biopsy of the palpable lesion revealed a high-grade infiltrating ductal carcinoma. She was referred for MR of the breasts to determine the extent of tumor and for staging. On MR, in addition to the known 1.3 cm tumor in the lower inner quadrant of the left breast (Fig. 1A), a second suspicious, spiculated 0.6 cm lesion with rapid washout kinetics was detected in the posterior upper inner quadrant; this was subsequently confirmed with ultrasound. Additionally, in the con-



**1A** Axial full maximum intensity projection (MIP) from the first post-contrast subtraction images reveals the known cancer in the medial left breast and a smaller suspicious finding posteriorly (arrow). Additionally a markedly vascular, unsuspected, contralateral (right) cancer was detected.



**1B** CAD parametric image documents in red the rapid enhancement and washout kinetics of the right breast cancer and of a small satellite lesion medially.



**1C** High quality oblique MIP image is possible from the dynamic images because of thin sections and good in-plane resolution, and the use of interpolation. The second left cancer is subtle on this image, but visible near the chest wall (arrow).

tralateral (right) breast a markedly enhancing 2 cm clinically and mammographically occult tumor was detected and confirmed at subsequent mastectomy. The DynamicVIEWS series provides not only kinetic data for parametric analysis using a CAD system (Confirma, Inc.) as seen in figure 1B, but also has resolution sufficient to produce detailed oblique Maximum Intensity Projection (MIP) images (Fig. 1C) for correlation with MLO (medial lateral oblique) mammograms.

### Comment

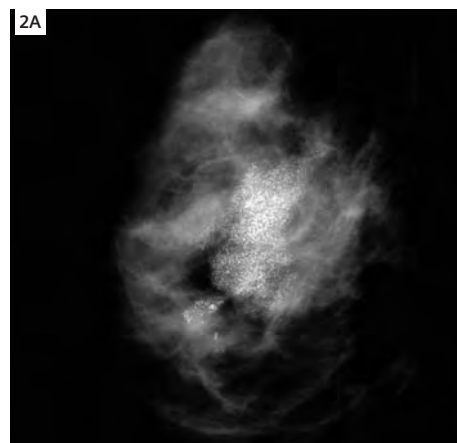
The patient elected bilateral mastectomies; the left breast cancer (known) was determined to be Stage 1, whereas several small tumor nodules were found in the sentinel lymph node on the right, resulting in a Stage 2 classification. Hence, the occult contralateral tumor was not only larger than the presenting mass, but already involved the axillary lymph nodes.

## Case 2: MR of the breasts for preoperative planning

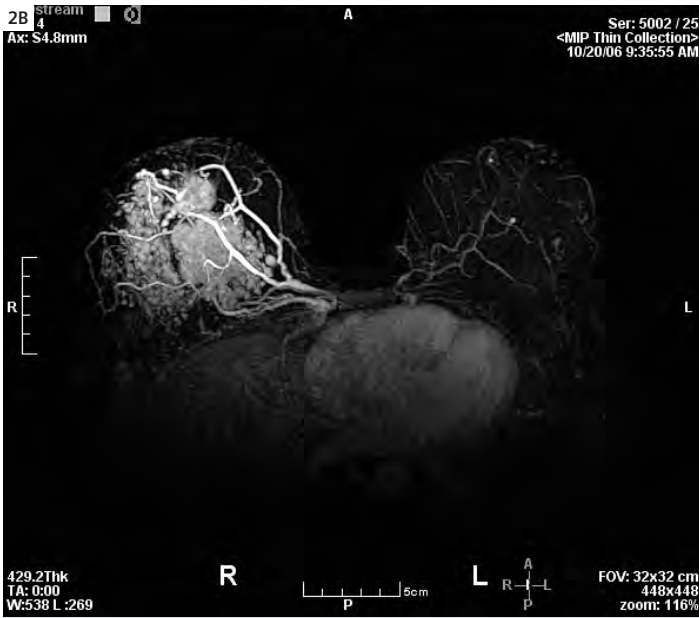A 32-year-old woman noted a firm mass, nipple retraction, and diminished milk production in her right breast during lactation. Ultrasound demonstrated a 2.2 cm solid mass, and mammography revealed micro-calcifications of the "casting-type" over 5 cm in extent (Fig. 2A). Biopsy confirmed mixed infiltrating ductal and in situ carcinoma, as suspected.

MR was requested to determine extent of the tumor, to assess the contralateral breast, and for staging. The axial maximum intensity projection (MIP) images (Fig. 2B) and corresponding parametric images (Fig. 2C) revealed a markedly vascular, irregular mass with malignant enhancement, and large draining veins involving the majority of the central right

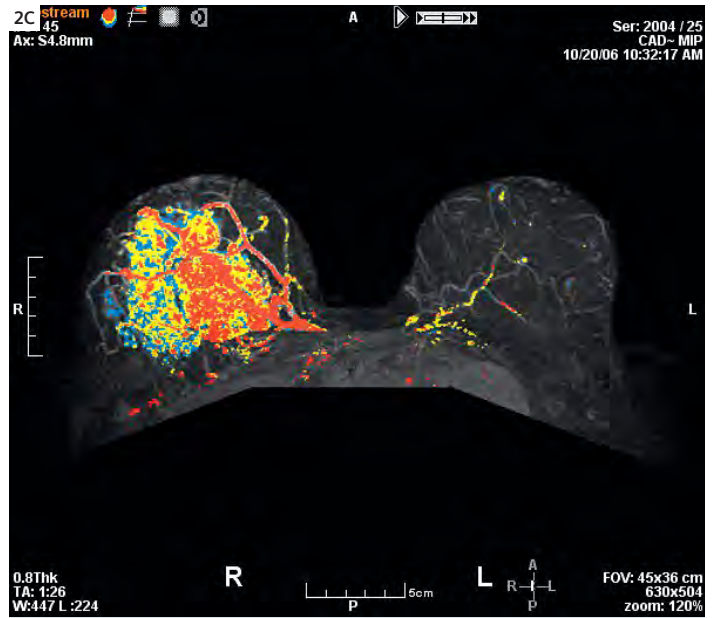
breast. High-resolution InterVIEWS images (Fig. 2D) revealed a mixed pattern, with a spiculated, solid 2.3 cm invasive mass, surrounded by a mixed solid and ductal enhancement consistent with high-grade in situ carcinoma, which was confirmed by mastectomy. The MR findings, readily understood by the patient, allowed her and her surgeon to determine together that mastectomy was clearly the appropriate surgical therapy. Pre-operative breast MR is a very helpful communication tool for the surgeon to discuss treatment options with the patient, to determine the extent of tumor, and to decrease the requirement for surgical re-excision for inadequate or positive surgical margins [Ref: Beatty and Porter].



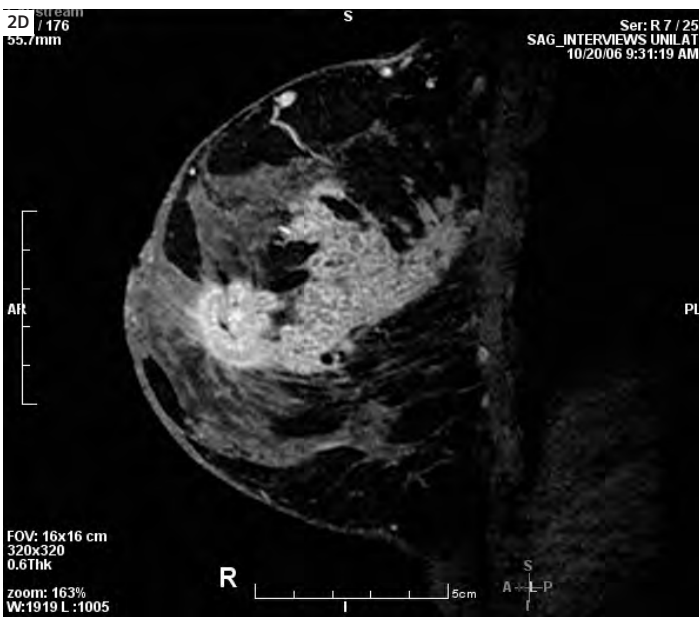
**2A** Right medial lateral oblique (MLO) mammogram shows extensive malignant calcifications in the mid breast to upper outer quadrant.



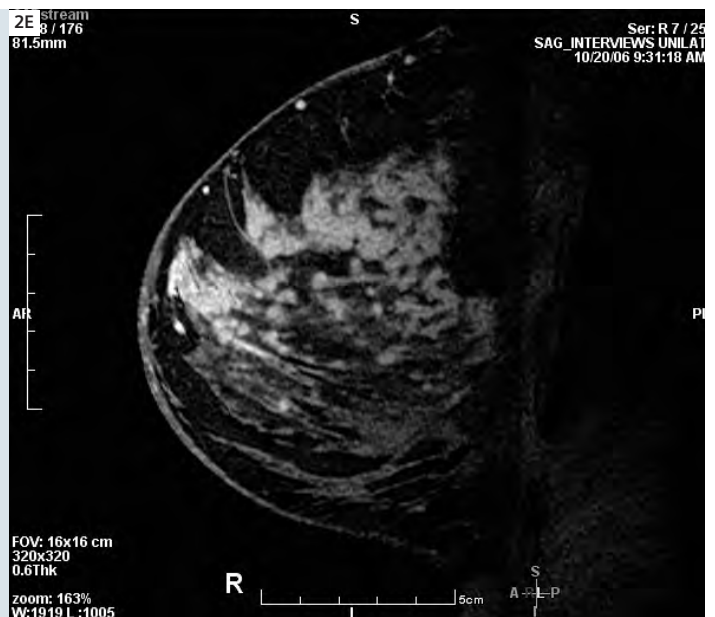**2B** The extent of tumor is even greater than suspected on the abnormal mammogram, with regional malignant enhancement and large asymmetrical veins. The left breast has a few physiological foci, but is negative for cancer.



**2C** Parametric enhancement images dramatically document the markedly abnormal vascularity that is characteristic of such high-grade and potentially lethal tumors.

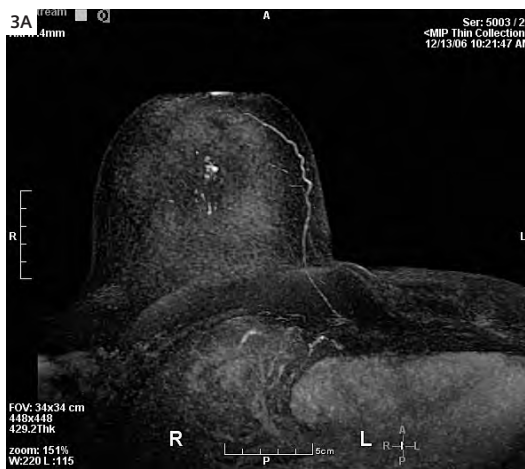

**2D,E** Right breast: two images from the same uni-lateral, sagittal InterVIEWS series at different slice locations. The invasive cancer is mass-like and more anterior, whereas the in situ tumor extends almost to the chest wall and is partly solid and partly ductal in appearance.

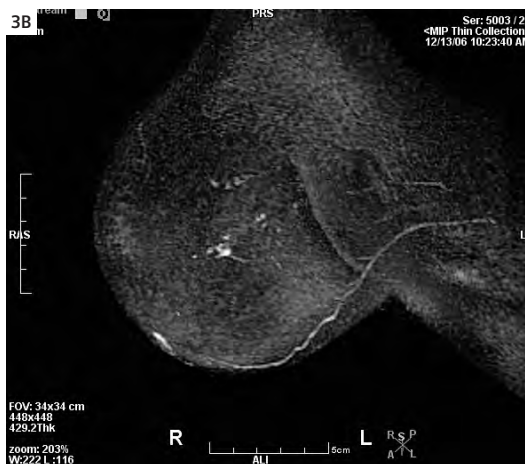

**Case 3:  
Prior history of breast cancer:  
detection of clinically and  
mammographically occult,  
early breast cancer**

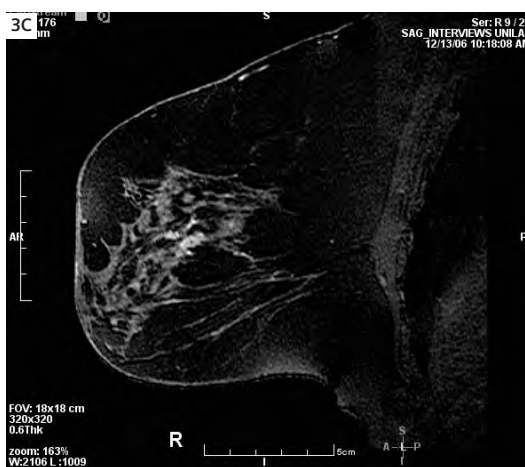A 43-year-old woman with a history of left breast carcinoma and mastectomy 5 years earlier was undergoing annual mammographic and MR surveillance for contralateral disease. She had a very strong family history of breast cancer. Recent mammograms were negative. However, a new clumped and ductal morphologic pattern of enhancement was noted on the MIP images in the axial and oblique projections (Figs. 3A, 3B). These findings were not present on a prior MR exam 2 years earlier. CAD analysis revealed a mixed pattern of persistent and plateau-type enhancement, within a small spiculated nodule and adjacent branching, ductal-type enhancement in the central right breast, also well seen on the high resolution InterVIEWS images (Fig. 3C). Due to the malignant morphologic and kinetic features, this was considered MR BIRADS (Breast Imaging Reporting and Data System) category 5 and MR-guided biopsy was undertaken, following a negative directed ultrasound of this region. The biopsy revealed high-grade in situ carcinoma. Subsequent mastectomy confirmed a small (5 mm) focus of low-grade invasive ductal cancer and surrounding in situ carcinoma, solid type with high nuclear grade. The patient elected mastectomy and had negative lymph nodes at surgery.



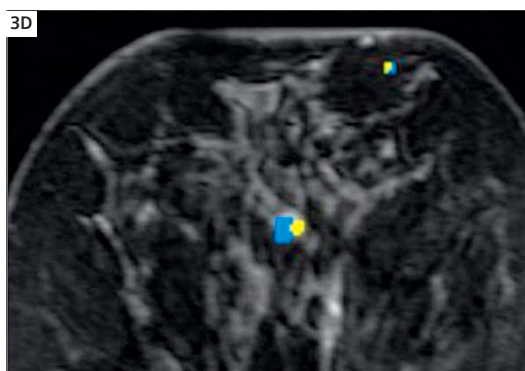
**3A** Axial 2 minute subtraction MIP of the remaining right breast shows a clumped abnormality not seen on a prior MR of 2 years earlier. Mammogram was negative in this area, as was ultrasound.



**3B** Right oblique MIP better portrays the ductal pattern and anatomic detail that leads to a diagnosis of probable malignancy.

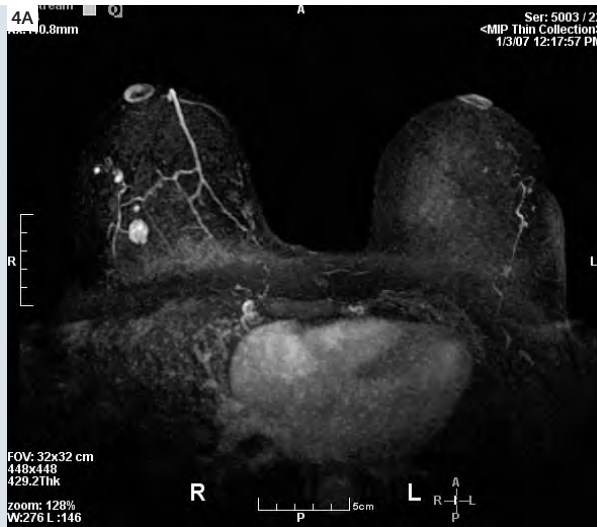


**3C** The high resolution sagittal InterVIEWS image shows a small mass with a neighboring linear enhancement with ductal distribution. Subtle spiculations can be identified, characteristic of an invasive malignancy.

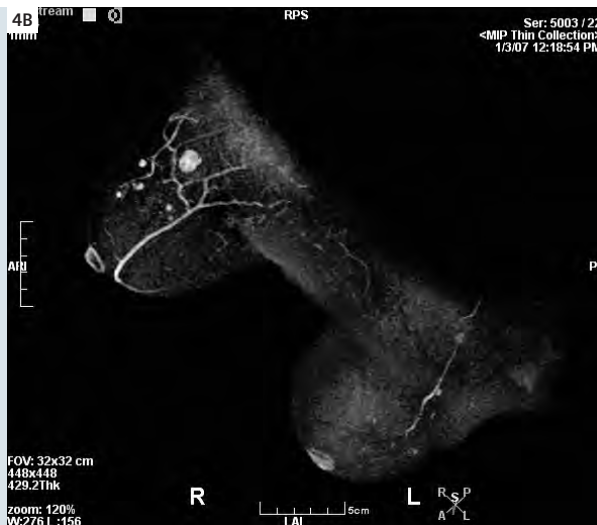

**3D** CAD image revealed mixed persistent and plateau type enhancement (blue and yellow, respectively) in the nodule in agreement with the morphologic assessment.

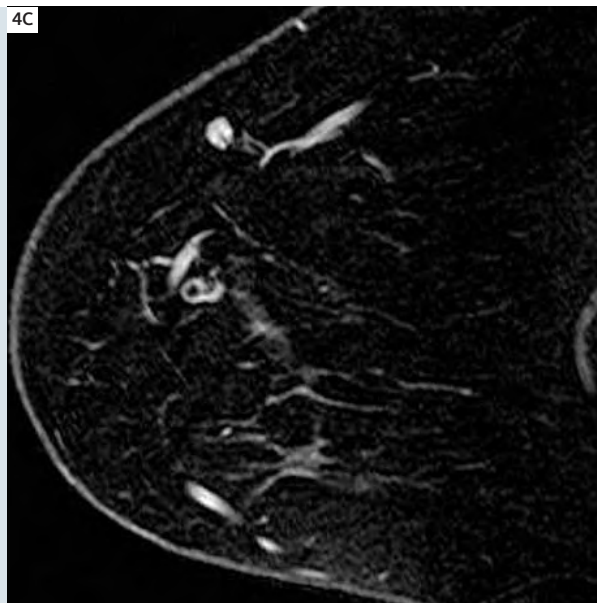
**4A** Axial MIP displays a normal left breast and multiple circumscribed nodules in the right breast.



**4B** An oblique MIP reveals and better shows that there are 4 small masses and one larger nodule.



**4C** Sagittal 0.64 mm thick InterVIEWS image has sufficiently high resolution to diagnose these as benign intramammary lymph nodes.

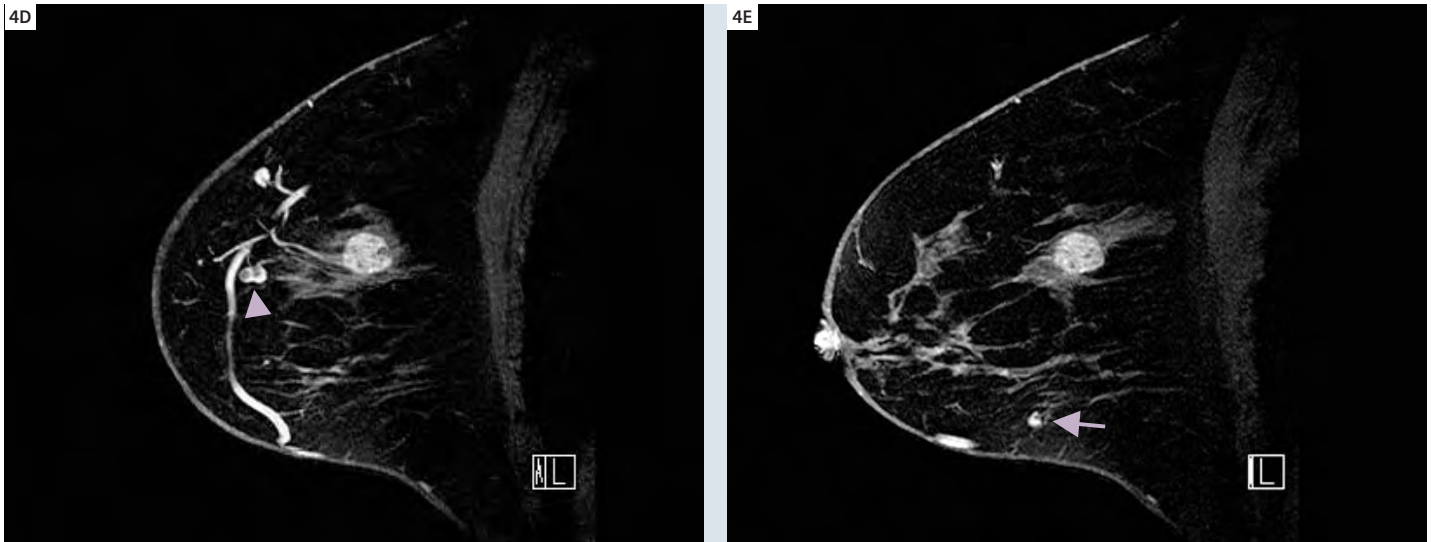


### Case 4: Very high resolution, 3-dimensional imaging improves characterization of benign enhancing breast masses

A 52-year-old woman with heterogeneously dense breasts, and who had a sister with breast cancer, had increasingly prominent nodular densities in the right breast on mammography, with no clear ultrasound correlate; she was then referred for MR due to her history and a problematic mammogram. MIP subtraction images (Figs. 4A, 4B) showed four small (4–8 mm) well-circumscribed, reniform masses with clearly visualized fatty hila and benign type kinetics: characteristics of benign intramammary lymph nodes. The near isotropic voxels (0.64 x 0.5 x 0.5 mm) and consequent very high resolution of the InterVIEWS images (Fig. 4C) allows detailed radial (RADIANT = RADial Imaging Around Nipple or Tumor) reconstructions at 1.5 degree intervals (Fig. 4D); this technique provided even greater diagnostic confidence. A classification of MR BIRADS category 2, benign, was given for the nodes.

The extremely thin slice thickness is also key to high quality multiplanar and radial images. This allows delineation of the full and complete surface margin and internal architecture of an adjacent fibroadenoma (Fig. 4E), using 1.5 mm RADIANT reconstructions at 1.5 degree intervals. There was very clear delineation of typical non-enhancing internal septations. Radial imaging, with the axis on the center of the lesion, allows assessment of the entire surface, to demonstrate that it is smooth, without angular, spiculated, or irregular margins; this supports the conclusion that this mass is benign, and biopsy confirmed a fibroadenoma.

The resolution on this exam is so extremely fine that the capillaries and venules feeding and draining the lymph nodes are readily appreciated on both source images and especially well on cine review of the



**4D,E** Oblique sagittal RADIANT images with a thin-MIP thickness of 1.5 mm better delineates the vascular structures, hilar fat of the nodes (arrow head, dark section is fat), and the larger mass posteriorly. Note the extremely fine anatomic detail from this reconstructed image. The non-enhancing internal septations of the biopsy proven fibroadenoma are clearly seen. The fourth node is very small but is well seen inferiorly in 4E (arrow).

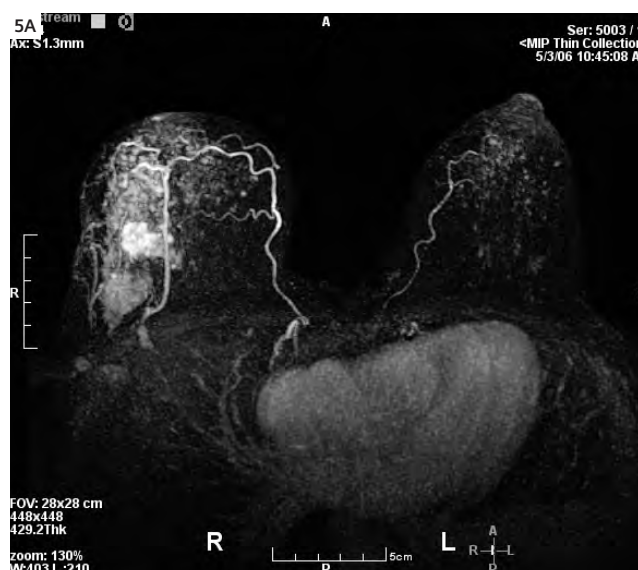
RADIANT image set. In breast imaging, proper characterization of a lesion based upon morphology requires detailed visualization of the entire surface of any suspected mass, lest a small area of irregularity, possibly indicating malignancy, be missed. The InterVIEWS technique, with

image acquisition at the time of maximal cancer enhancement and minimal background enhancement, improves lesion characterization, based upon morphologic features. When combined with benign enhancement kinetics, greater diagnostic confidence is achieved. If histologic con-

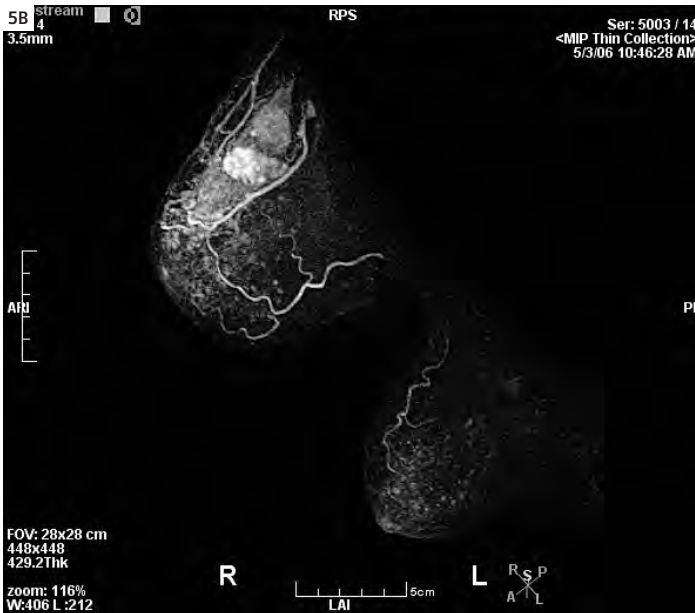
firmation is required (as was suggested for the larger lesion), ultrasound or MR-guided biopsy can be performed, but the number of MR biopsies can be reduced with such high-resolution, detailed imaging.

### Case 5: Tumor, node, metastases (TNM) staging with MR: breast and body imaging

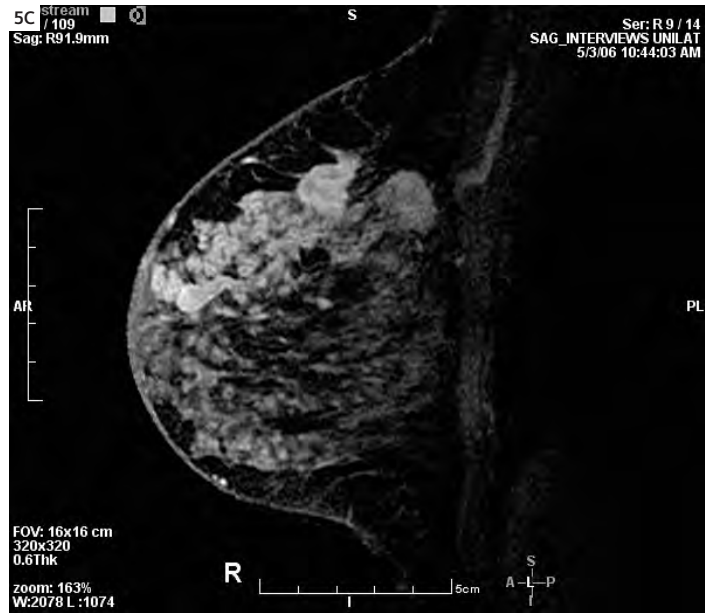A palpable firmness in the upper outer right breast brought a 58-year-old woman to medical attention; mammograms were very dense, interpreted as negative, and an ultrasound showed a 1.2 x 1.1 cm hypoechoic mass that on biopsy was an intermediate grade infiltrating ductal cancer. MR of the breast and a whole body staging study were requested. The breast exam revealed extensive infiltration of virtually the entire right upper outer quadrant with mixed invasive and intraductal carcinoma (Figs. 5A, B, C). Additionally, abnormal axillary lymph nodes were detected from level I to level III (Fig. 5D) with no internal mammary, supraclavicular, or cervical adenopathy.



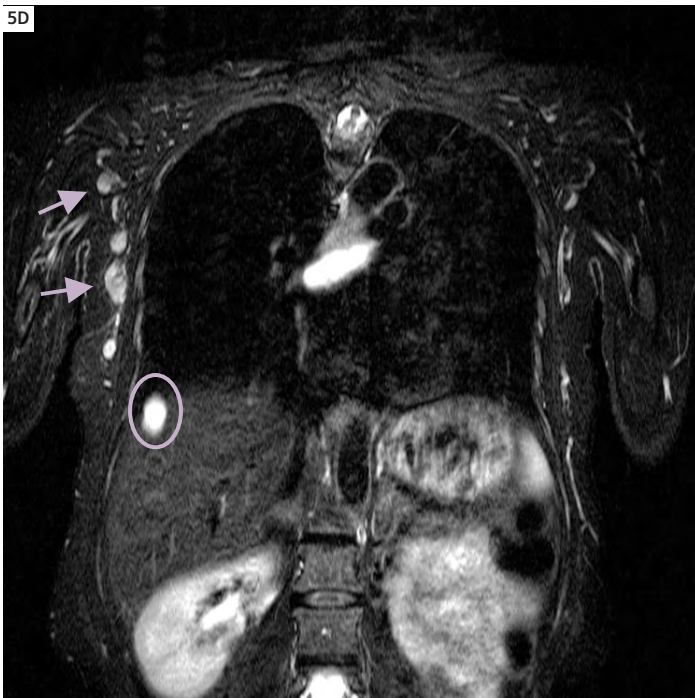
**5A** Extensive malignancy with nodular, mass-like and diffuse enhancement is seen to involve much of the lateral right breast on this axial MIP; the left breast is negative for tumor.



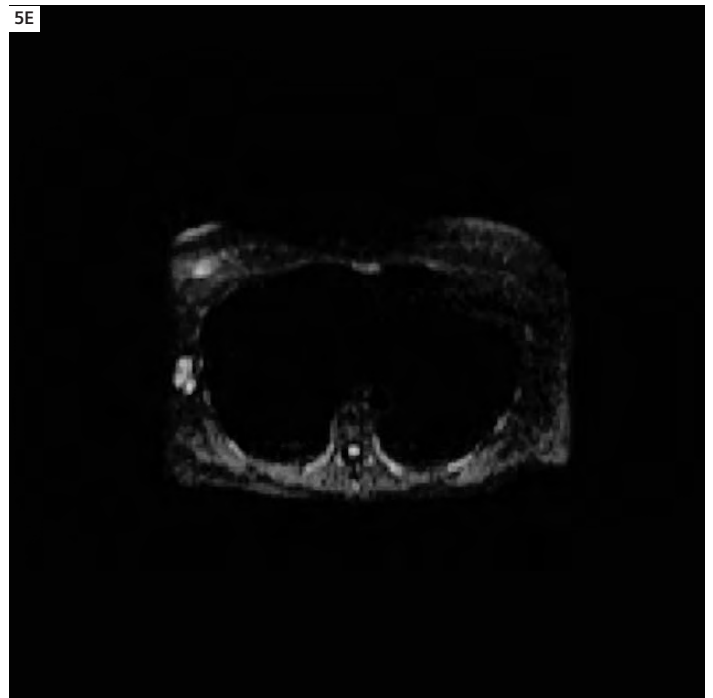
**5B** Again, the availability of high quality oblique images, similar to mammographic MLO projections, complements the CC-like axial MIP images for localization of the cancer and estimation of its extent.



**5C** Sagittal InterViews at 2.5 minutes post-injection produces high contrast between the cancer and the normal background dense parenchyma. Precise timing is critical to regularly achieve such detailed tumor visualization in dense breasts.



**5D** "Whole body" coronal imaging with STIR detects suspicious lymph nodes in the right axilla in levels 1 and 2 on this image (arrows); more extensive nodal disease was noted on other images. A fluid-containing cyst is seen in the liver (orange outline) and another in the mediastinum (center).



**5E** Axial diffusion image, with B value of 250, detects suspicious signal in the confirmed malignant axillary nodes. Diffusion images are sensitive to pathology, but lower in resolution.

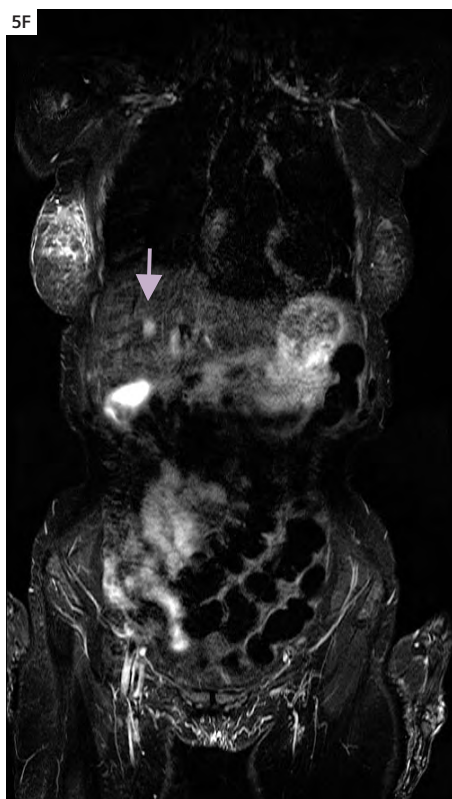
Ultrasound-guided fine-needle aspiration (FNA) of a selected axillary node, with abnormal signal on diffusion imaging (Fig. 5E) confirmed malignancy. A high signal, sharply demarcated hepatic cyst and a gallstone were seen in the liver, and in addition a 1.5 cm solitary metastasis to the anterior right lobe of the liver on whole body imaging (Fig. 5F); this was confirmed on PET-CT and by follow-up studies showing progression. As suspected, despite intensive chemotherapy, the tumor has progressed and this patient has not done well.

## Comments

Marked improvement in software, gradient amplifiers, and coils now allows a clinically effective hybrid breast MR technique that combines the strengths of the dynamic/kinetic approach and morphologic imaging in one examination. The extent of invasive and in situ carcinomas is readily appreciated, improving preoperative planning and diminishing the need for reoperation, and improving staging as well [Beatty and Porter]. The addition of "whole-body" MR adds further to the clinical value and effectiveness of MR as a breast cancer staging tool for not only the size of the tumor within the breast (T-classification), but also for detection of nodal and extra-nodal metastatic disease (N and M classifications).

There has been much recent emphasis on the great sensitivity of MR imaging for surveillance of high-risk patients such as breast cancer gene carriers, or women with a greater than 20–25% lifetime risk of developing breast cancer (ACS Guidelines). High-risk patients are effectively monitored with this technique, and small tumors with a better prognosis can be diagnosed early.

Additionally, MR detection of contralateral tumors markedly affects patient morbidity, management\* and surgical decision-making, and decreases the cost of patient care and the potential risk from an occult cancer undetected by conventional meth-



**5F** Coronal body staging STIR study detected a lesion in the mid liver (arrow) of lower signal than the cyst seen in 5E, but abnormal and confirmed as an early hepatic metastasis. Note the edema (high signal) in the edematous right breast tissue and skin in a tumor that had lympho-vascular invasion on pathology.

ods. Recent publications indicate that MR detects occult contralateral cancers in at least 3% of cases [Lehman]. This, by itself, is a major reason why MR of the breast should be considered in any woman with a newly diagnosed breast carcinoma, particularly if breast conservation is considered. Other higher-risk patient groups are being identified, for which MR may play a crucial role in early detection of small cancers, as seen in Case 3. Recent reports show great improvements in detection of in situ cancers with better technology as well [Kuhl, Lancet]. Though the current capabilities of contrast-enhanced breast MR and body imaging are certainly very impressive, hard-

ware and software advances in MR are continuing and improvements in exam methodology, CAD assessment and interpretation can also be expected. This examination is technically and interpretatively challenging, and therefore the training of radiologists and technologists in this vitally important procedure, with its unique clinical capability, is required and ongoing.

## References

- 1 Beatty J, Porter B. Contrast-enhanced breast magnetic resonance imaging: the surgical perspective. *Am J Surg* 193;5:600-605.
- 2 Kuhl CK, Schrading S, Bieling HB, Wardelmann E, et al. MRI for diagnosis of pure ductal carcinoma in situ: a prospective observational study. *Lancet* 2007;370:485-92.
- 3 Lehman CD, Gatsonis C, Kuhl CK, Hendrick RE, et al. MRI evaluation of the contralateral breast in women with recently diagnosed breast cancer. *N Engl J Med* 356;13:1295-1303, March 29, 2007.
- 4 Saslow D, Boetes C, Burke W, Harms S, et al. American Cancer Society Guidelines for Breast Screening with MRI as an Adjunct to Mammography. *CA Cancer J Clin* 2007;57:75-89.

\*Works in progress (WIP). The information about this product is preliminary. The product is under development and not commercially available in the U.S., and its future availability cannot be ensured.