MR Imaging in the Electrophysiology (EP) Laboratory

A Novel Method to Facilitate Treatment of Atrial Fibrillation

Robert S. Oakes[1],M.D.; Rob S. MacLeod[2,3]; Christopher J. McGann[1]; Eugene G. Kholmovski[4]; Edward V. R. Di Bella[4]; Nassir F. Marrouche[1], M.D.

[1]*Division of Cardiology, Internal Medicine, University of Utah School of Medicine, Salt Lake City, Utah, USA*
[2]*Scientific Computing and Imaging Institute, School of Engineering, University of Utah, Salt Lake City, Utah, USA*
[3]*Nora Eccles Harrison Cardiovascular Research and Training Institute, University of Utah, Salt Lake City, Utah, USA*
[4]*Utah Center for Advanced Imaging Research, University of Utah, Salt Lake City, Utah, USA*

Background

Since the pulmonary veins were identified as one of the primary sources of atrial fibrillation (AF), a variety of treatment strategies have been developed to minimize the electrical effects of the pulmonary veins in AF [1]. These procedures often utilize a mapping catheter under fluoroscopic guidance to electrically isolate the pulmonary veins (PV) from the rest of the left atrium (LA). One technique in particular, Circumferential Pulmonary Vein Isolation (CPVI), has been reported to be highly effective for both the paroxysmal and persistent forms of AF [2–6]. CPVI has been reported to help return the majority of patients to normal sinus rhythm independent of the effects of antiarrhythmic-drug therapy, cardioversion or both [7]. There are other positive effects from successful CVPI including decreased size of the LA and improvement of left ventricular ejection fraction (LVEF) in patients who remain in sinus rhythm following the procedure [8].

However, despite the success of the CVPI procedure, the overall curative rate and complication rate for AF treatment is the same as it was at the turn of the millennium, despite years of investment and extensive study. Current challenges include efforts to maximize efficacy and safety, improve operator skills, better characterize left atrial anatomy and improve navigation within the cardiac chambers. In moving forward, integrating three-dimensional (3D) imaging along with other accepted modalities shows promise in improving both the overall curative rate and for decreasing the complication rate.

Of all the imaging modalities, MRI offers the most detailed anatomic and physiologic information about normal and damaged myocardial tissue. It has vastly superior soft tissue contrast when compared to fluoroscopy and CAT scans and does not expose the patient to ionizing radiation. In current practice, MRI has several important roles in patient screening and procedure planning, improved navigation in procedures requiring substrate based ablation, and important roles in follow-up and localizing causes of post-procedural complications.

CMR offers the most detailed anatomic and physiologic information about normal and damaged myocardial tissue.

MRI and treatment of atrial fibrillation – pre-procedure

Visualization of thrombus

Identification of left atrial thrombi is a critical component in preparing patients for a successful RF procedure. In AF, there is a very high age-dependent incidence of left atrial thrombus which may range between 3% and 21% [9]. One primary location for thrombus formation is within the left atrial appendage due to altered blood flow when the arrhythmia is present [10]. The current accepted clinical diagnostic test of choice to screen

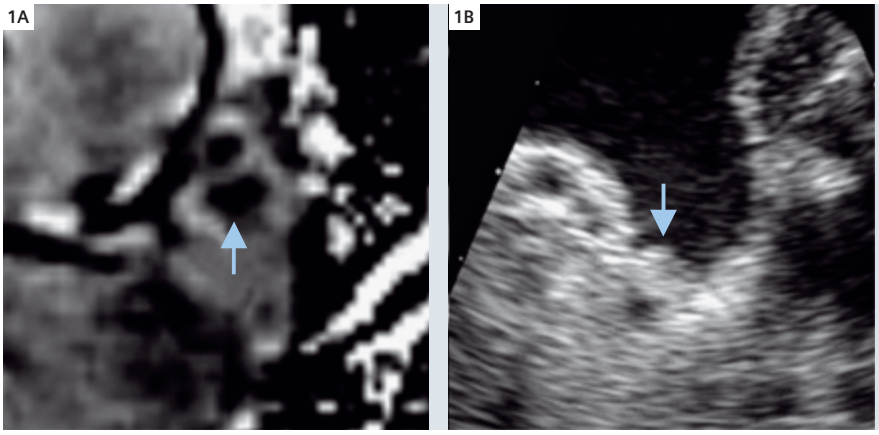

1 Left Atrial Appendage thrombus on MRI axial view (left, PSIR) and transesophageal echocardiogram (TEE) on the long axis view (right). Thrombus imaging using PSIR can be done without TI adjustment.

for left atrial thrombi is transesophageal echocardiogram (TEE) [11, 12]. Firstly, despite very high accuracy, TEE is still semi-invasive which may lead some patients to forego the procedure. Secondly, the complex morphology of the left atrial appendage may make estimation/localization of a thrombus difficult and may result in underestimation of the thrombus [13]. In contrast, cardiac MRI allows for a convenient and useful alternative to TEE. It is non-invasive, allows evaluation of cardiac morphology without any assumptions in regard to cardiac geometry, and can be taken at the same time as other studies that are necessary for planning of the RF ablation procedure.

In recent studies, MRI successfully detected thrombus with 100% sensitivity (verified utilizing TEE) [14, 15]. The thrombus was imaged utilizing a delayed contrast-enhanced T1-weighted inversion (IR) recovery sequence timed to null thrombus. The images were acquired in axial and longitudinal planes through the left atrium with additional TrueFISP cine imaging in matched slices (Figure 1). By imaging the thrombus using multiple adjacent slices it is possible to provide a better estimation of its overall size and volume. Successful localization of the thrombus prior to ablative procedures allows for aggressive anti-coagulative therapy to be pursued which has been shown to be very effective in resolving the clot [14]. MRI shows promise as a future alternative to TEE for the detection of thrombus.

Segmentation and anatomy posterior to the left atrium

Radiofrequency ablation in the LA has the potential to damage adjacent structures with potentially deadly side effects. For this reason, MRI serves an essential point in the planning of the procedure. In patients with permanent atrial fibrillation, the left atrium often dilates. This may result in changes to the morphology of the structures posterior to the left atrium. In one study of 42 patients about to undergo catheter treatment in the LA for AF, the larger LA size resulted in the spine and aorta impressing on the LA frequently. The esophagus was also a persistent feature running directly posterior to the LA and contacting it in all of the patients imaged. These findings are important as the topology of the posterior wall of the LA may be altered by the presence of the aorta or the spine [16]. There have also been reports of the LA wall and the pulmonary veins being compressed by the aorta. This has resulted in narrowing of the pulmonary veins and increased concern for aortic injury. Segmentation and volume rendering of structures and their relationship to the LA anatomy allows the physician performing the procedure to take care when performing ablation in points of concern.

Cardiac MRI is a convenient and useful alternative to TEE for left atrial thrombus detection.

MRI utilization in the cath lab – periprocedure

Merged image navigation – MRI and electroanatomic mapping systems (CARTOMERGE)

Electroanatomic mapping systems which allow for high-resolution MRI images to be merged with electrophysiological data acquired during the ablation procedure help to alleviate some of the potential complications (Figure 2). The electroanatomic model also helps the physician performing the procedure to guide the catheter manipulation near pulmonary vein ostia and other complex structures while helping to ascertain complications which may involve other structures of concern such as the esophagus or aorta (Figure 3).

Inspace EP® facilitates merging of MRI and electroanatomic mapping data.

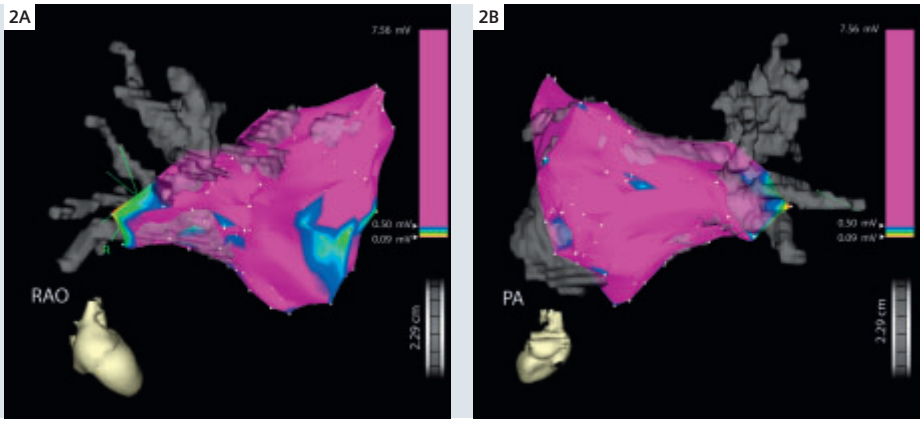

2 3D computed tomographic reconstruction of the left atrium (LA) aligned with 3D LA voltage map (solid contour map). The 3D images are acquired from high resolution MRI contrast scans obtained after injecting the patient with gadolinium. Purple areas represent normal myocardium with green and blue spots corresponding to areas of low voltage/fibrotic tissue.

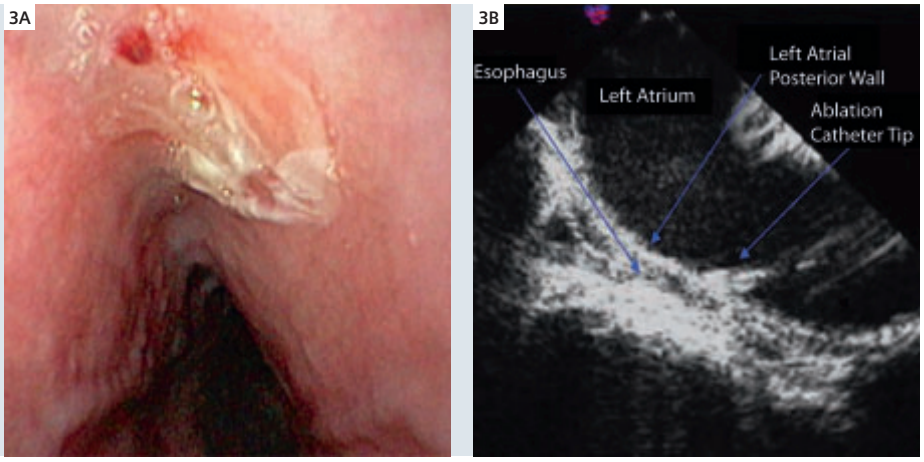

3 **(A)** Necrotic and ulcer changes within the anterior aspect of the esophagus. These changes were seen in the esophageal wall in close proximity to the left atrial posterior walls. The image shown was taken 24 hours after circumferential pulmonary vein isolation (CVPI) utilizing RF energy.
(B) Intracardiac echocardiogram image demonstrating radiofrequency lesion delivery at the left atrial posterior wall (LA). The esophagus is often within close proximity of the posterior wall of the LA making it a likely candidate for injury.

Although merging with MRI data allows for navigation models to be substantially refined, the overall accuracy of the model still remains controversial [17, 18]. Image integration may be affected by a variety of factors including differences in the heart size because of changes in rhythm and rate, contractility or fluid status. In various studies, operators utilizing other real-time imaging modalities (e.g. fluoroscopy and intracardiac echocardiography [ICE]) were blinded to merged electroanatomic/MRI images created utilizing a CARTOMERGE® system (BioSense Webster; Denver, Colorado, USA). Despite careful attempts to optimize registration, the CARTOMERGE guided catheter positioning was subject to spatial errors in all studies from 0.5 to 1.0 cm when compared to mapping of the positions in ICE [17–19]. Such a misregistration is of significant clinical importance as it casts serious doubt on the location of lesion formation. This may result in complications such as the inappropriate ablation of the pulmonary veins resulting in PV stenosis. Accuracy can be improved through the addition of an appropriate two-dimensional image modality including fluoroscopy or ICE though these solutions are imperfect. As real-time 3D MRI becomes available, it will become more important in providing real-time information regarding structure and function during RF procedures.

RF energy delivery and posterior mediastinal injury

An additional component of successful pulmonary vein isolation involves delivering an effective amount of energy for an appropriate duration. Both the choice of catheter and the mode of energy titration during RF ablation are likely to have important influences on the operator's success in accomplishing permanent changes to the electrical signal propagation within the LA. This is particularly important regarding the recognition of left atrial-esophageal fistula as a potentially fatal complication of the AF ablation procedure [20]. Striking a balance between effective lesion formation in the LA and preventing damage to the adjacent structures can be difficult. In one recent study comparing catheter types and imaging modalities,

esophageal wall changes (including edema/erythema and necrosis) were seen in 35.7% of the patients which were ablated using an open irrigation tip catheter and changes were seen in 57.1% of patients where power delivery was monitored using ICE (Figure 4) [21]. The high rate of injury highlights the need to effectively titrate and monitor tissue response to RF energy. MRI scans which utilize techniques such as delayed enhancement will play an important role in helping to determine appropriate power delivery settings which result in effect lesion formation without causing unnecessary damage to other structures.

MRI use in post-procedure care and follow-up

Delayed Enhancement MRI imaging – imaging RF ablation scar

Given concerns about energy delivery and potential injury to other structures, MRI provides a powerful tool for investigation into the injury of tissues near the posterior LA wall. Delayed enhancement cardiovascular magnetic resonance imaging (DE-MRI) is an established clinical method for visualizing tissue necrosis in a variety of cardiac disease processes. These include visualizing myocardial infarction and injury due to myocarditis. This imaging method also has uses in determining the health of atrial tissue following ablation. Contrast enhancement in injured tissue observed by MRI occurs due to altered washout kinetics of gadolinium relative to the normal surrounding tissue. RF injury to the right ventricle has been shown on MRI using an intrathoracic high resolution coil [22]. Visualization of RF ablation lesions within the LA using MRI have also recently been reported and imaging modalities developed so that these scans may be run on clinical scanners [23, 24]. The typical imaging protocol includes contrast enhanced pulmonary vein angiography, 2D cine imaging and delayed enhancement imaging. Pulmonary vein MR angiography is acquired during injection of gadolinium-based contrast agent (0.2 mmol/kg).
20 minutes following the injection, an additional three dimensional (3D) DE-MRI scan of the atria and PVs is acquired with navigator tracking during free breathing [23, 25, 26].
Figure 4 shows typical images acquired using 3D DE-MRI sequence prior to the ablation procedure, 24 hours after the procedure and a follow-up scan at 3 months. Delayed enhancement is readily seen in both the 24 hour and 3 month follow-up images near the pulmonary vein ostia and along the posterior wall in all patients for whom imaging data was taken [23, 24]. In addition to the delayed enhancement seen at the site of the LA posterior wall, septum and roof of the LA it is possible to see significant enhancement in por-

With delayed enhancement (DE) imaging, CMR provides a powerful tool for investigation into the injury of tissues after RF ablation.

A typical imaging protocol for post-procedure care includes contrast enhanced PV angiography, 2D cine and DE imaging.

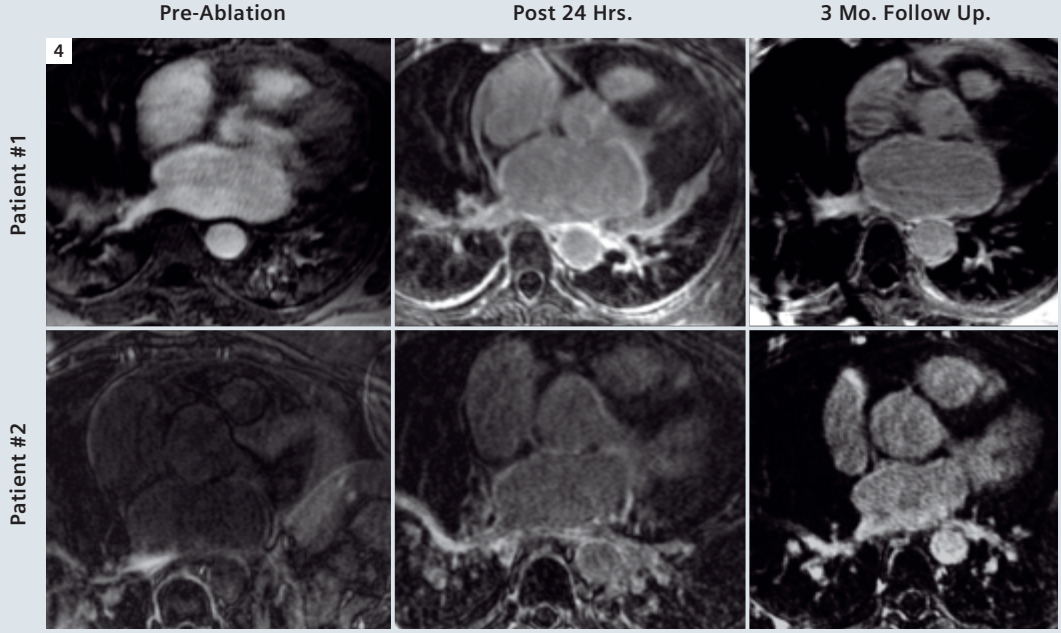

4 Matched axial slices from pre-ablation, 24 hours post ablation and a 3 month follow-up scan for two patients. Gadolinium contrast delayed enhancement is seen in both the 24 hour and three month scans. There is some apparent recovery (as noted by the less intense image) though scarring is still quite extensive in patients even after 3 months follow-up.

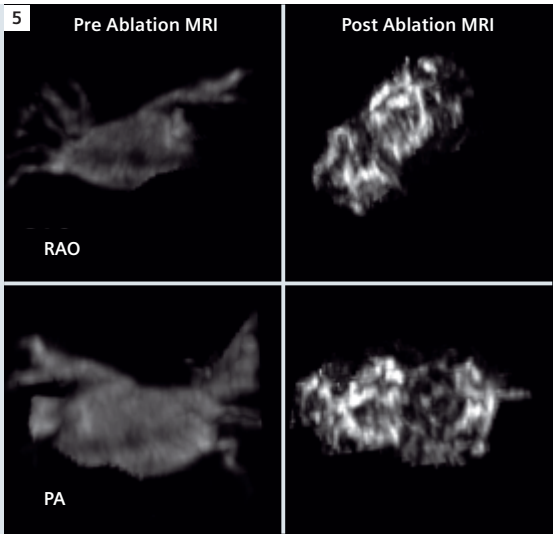

5 Maximal Intensity Projection (MIP) of 3D reconstruction of Delayed Enhancement MRI (DE-MRI) images and scar formation as a result from RF ablation in a single patient.

2D and 3D PSIR and TurboFLASH/TrueFISP IR sequences are provided for delayed enhancement imaging in the Advanced Cardiac Package.

CMR is a highly valuable tool in preparation, performing and follow-up of RF ablation procedures in cardiac electrophysiology.

tions of the aorta and the pulmonary tree. It is probable that while some enhancement is due to injury and inflammation, it is also likely that some delayed enhancement in the aorta is also due to the increased fibrous nature of the tissue in this location. 3D visualization and segmentation of the image volume acquired by the DE-MRI sequence allow for the overall extent of scarring to be evaluated (Figure 5). This image analysis offers evidence of the extent of atrial scarring and its relationship to the original ablation scar created during the RF procedure (CARTOMERGE model). The DE-MRI scan may be used to analyze patients with post-procedural complications and determine how they might be related to initial RF procedure or other factors related to their inpatient-hospital care. This new imaging method also allows patient outcome studies to be performed which might assess how atrial scarring is connected to the recurrence of AF.

Future work: MRI guided ablation procedures

One of the great advantages of MRI guidance for electrophysiology procedures is the excellent soft tissue contrast and adequate spatial resolution available without the need to expose a patient to ionizing radiation. Research groups have reported success in guiding the RF ablation catheter to the atrial wall and the right ventricle apex. By using low-pass RF filters, image acquisition was possible even during RF energy applications. Studies in animal models have also have also reported success in imaging lesion formation by T2-weighted FSE imaging and T1-weighted contrast enhanced-gradient echo imaging [27]. Using pulse sequences such as the delayed enhancement sequence discussed and other novel imaging sequences, it may be possible to develop technology which allows for the imaging of scar formation in real-time. As MRI techniques for scar imaging become available, MRI will be an indispensable tool within the cath lab itself. Within a single display, it will become possible to show lesion size and location and how that relates to existing abnormal tissue. This is likely to greatly improve the success rate in complex patients.

Conclusion

MRI is an extremely important modality for the treatment of atrial fibrillation. It currently has important implications in preparing patients for the initial treatment by helping to localize left atrial thrombus and defining anatomy of pulmonary veins, left atria, and the surrounding structures. During the ablation procedure, MR angiograms help to improve anatomical maps which are used in conjunction with other imaging modalities to determine appropriate sites for ablation. MRI also has very important roles in post-procedural assessment and follow-up. Using delayed enhancement MRI, it is possible to visualize the scar utilizing clinical scanners. This will likely prove valuable in diagnosing post-procedural complications and determining how they may be related to the RF parameters. Additional research regarding patient outcome and its relation to the type and extent of post-procedure scar should be pursued. As interventional MRI scanners become available, MRI will become even more important than it now is in the treatment of atrial fibrillation patients. By building on the success of other groups which have successfully applied MRI technology to interventional procedures targeting the ventricle; it will be possible to assess lesion size and change in tissue pathology in real-time. These steps will serve to greatly increase the curative rate for AF while simultaneously decreasing the complication rate.

Acknowledgements

The authors gratefully acknowledge the assistance of Joshua E. Blauer, Troy J. Badger, and Eric Fish in the preparation and editing of this manuscript.

Contact
Nassir F. Marrouche, M.D.
Director, Cardiac Electrophysiology Laboratories
Director, Atrial Fibrillation Program
Division of Cardiology
University of Utah Health Sciences Center
30 North 1900 East
Room 4A100
Salt Lake City, Utah 84132-2400
USA
Nassir.Marrouche@hsc.utah.edu
Phone: +1-801-581-2572
Fax: +1-801-581-7735

References and recommended reading

1 Haissaguerre M, Jais P, Shah DC, et al. Spontaneous initiation of atrial fibrillation by ectopic beats originating in the pulmonary veins. The New England Journal of Medicine. 1998;339(10):659–66.
2 Kottkamp H, Tanner H, Kobza R,et al. Time courses and quantitative analysis of atrial fibrillation episode number and duration after circular plus linear left atrial lesions: trigger elimination or substrate modification: early or delayed cure? Journal of the American College of Cardiology. 2004;44(4):869–77.
3 Oral H, Scharf C, Chugh A, et al. Catheter ablation for paroxysmal atrial fibrillation: segmental pulmonary vein ostial ablation versus left atrial ablation. Circulation. 2003;108(19):2355–60.
4 Pappone C, Manguso F, Vicedomini G, et al. Prevention of iatrogenic atrial tachycardia after ablation of atrial fibrillation: a prospective randomized study comparing circumferential pulmonary vein ablation with a modified approach. Circulation. 2004;110(19):3036–42.
5 Pappone C, Oreto G, Rosanio S, et al. Atrial electroanatomic remodeling after circumferential radiofrequency pulmonary vein ablation: efficacy of an anatomic approach in a large cohort of patients with atrial fibrillation. Circulation. 2001;104(21):2539–44.
6 Pappone C, Rosanio S, Augello G, et al. Mortality, morbidity, and quality of life after circumferential pulmonary vein ablation for atrial fibrillation: outcomes from a controlled nonrandomized long-term study. Journal of the American College of Cardiology. 2003;42(2):185–97.
7 Oral H, Pappone C, Chugh A, et al. Circumferential pulmonary-vein ablation for chronic atrial fibrillation. The New England Journal of Medicine. 2006;354(9):934–41.
8 Lemola K, Desjardins B, Sneider M, et al. Effect of left atrial circumferential ablation for atrial fibrillation on left atrial transport function. Heart Rhythm. 2005;2(9):923–8.
9 Stollberger C, Chnupa P, Kronik G, et al. Transesophageal echocardiography to assess embolic risk in patients with atrial fibrillation. ELAT Study Group. Embolism in Left Atrial Thrombi. Ann Intern Med. 1998;128(8):630–8.
10 Narumiya T, Sakamaki T, Sato Y, et al. Relationship between left atrial appendage function and left atrial thrombus in patients with nonvalvular chronic atrial fibrillation and atrial flutter. Circ J. 2003;67:68–72.
11 Daniel WG, Mugge A. Transesophageal echocardiography. The New England Journal of Medicine. 1995;332(19):1268–79.
12 Manning WJ, Weintraub RM, Waksmonski CA, et al. Accuracy of transesophageal echocardiography for identifying left atrial thrombi. A prospective, intraoperative study. Ann Intern Med. 1995;123(11):817–22.
13 Stollberger C, Ernst G, Bonner E, et al. Left atrial appendage morphology: comparison of transesophageal images and postmortem casts. Z Kardiol. 2003;92(4):303–8.
14 McGann C, Di Bella EVR, Wilson B, et al. MRI to Detect and Follow Regression of Left Atrial Appendage Thrombus. Paper presented at: Scientific Sessions - AHA 2007, 2007.
15 Mohrs OK, Nowak B, Petersen SE, et al. Thrombus detection in the left atrial appendage using contrast-enhanced MRI: a pilot study. Am J Roentgenol. 2006;186(1):198–205.
16 Hoffmeister PS, Chaudhry GM, Mendel J, et al. Evaluation of left atrial and posterior mediastinal anatomy by multidetector helical computed tomography imaging: Relevance to ablation. J Interv Card Electrophysiol. 2007;18(3):217–23.
17 Zhong H, Lacomis JM, Schwartzman D. On the accuracy of CartoMerge for guiding posterior left atrial ablation in man. Heart Rhythm. 2007;4(5):595–602.
18 Malchano ZJ, Neuzil P, Cury RC, et al. Integration of cardiac CT/MR imaging with three-dimensional electroanatomical mapping to guide catheter manipulation in the left atrium: implications for catheter ablation of atrial fibrillation. Journal of Cardiovascular Electrophysiology. 2006;17(11):1221–9.
19 Daccarett M, Segerson NM, Gunther J, et al. Blinded Correlation Study of Three-Dimensional Electroanatomical Image Integration and Phased Array Intra-cardiac Echocardiography for Left Atrial Mapping. University of Utah 2007.
20 Paponne C, Oral H, Santinelli V, et al. Atrio-esophageal fistula as a complication of percutaneous transcatheter ablation of atrial fibrulation. Circulation. 2004;109:2724–6.
21 Marrouche NF, Guenther J, Segerson NM, et al. Randomized comparison between open irrigation technology and intra-cardiac-echo-guided energy delivery for pulmonary vein antrum isolation: procedural parameters, outcomes, and the effect on esophageal injury. Journal of Cardiovascular Electrophysiology. 2007;18(6):583–8.
22 Dickfeld T, Kato R, Zviman M, et al. Characterization of radiofrequency ablation lesions with gadolinium-enhanced cardiovascular magnetic resonance imaging. Journal of the American College of Cardiology. 2006;47(2):370–8.
23 Peters DC, Wylie JV, Hauser TH, et al. Detection of pulmonary vein and left atrial scar after catheter ablation with three-dimensional navigator-gated delayed enhancement MR imaging: initial experience. Radiology. 2007;243(3):690–5.
24 McGann C, Kholmovski EG, Oakes RS, et al. Magnetic Resonance Imaging Detects Chronic Left Atrial Wall Injury Post Ablation of Atrial Fibrillation. 2007, Scientific Sessions – AHA 2007, Orlando.
25 Stuber M, Botnar RM, Danias PG, et al. Contrast agent-enhanced, free-breathing, three-dimensional coronary magnetic resonance angiography. J Magn Reson Imaging. 1999;10(5):790–9.
26 Saranathan M, Rochitte CE, Foo TK. Fast, three-dimensional free-breathing MR imaging of myocardial infarction: a feasibility study. Magn Reson Med. 2004;51(5):1055–60.
27 Lardo AC, McVeigh ER, Jumrussirikul P, et al. Visualization and temporal/spatial characterization of cardiac radiofrequency ablation lesions using magnetic resonance imaging. Circulation. 2000;102(6):698–705.