Flow Measurements: Basics and the Application to the Main Pulmonary Artery

Nasreddin Abolmaali, M.D.

OncoRay – Center for Radiation Research in Oncology, Medical Faculty Carl Gustav Carus, TU Dresden, Germany

Introduction

In 1959, Jerome „Jay" R. Singer published his fundamental work on the quantification of macroscopic flow and microscopic motion (diffusion) using magnetic resonance (MR) [1]. The introduction of MR flow measurements with velocity encoding to the clinical application in the mid-1980s made a new field of functional diagnosis accessible to radiologists [2]. Within the past 20 years, velocity encoded MR has been continuously improved [3] including correction for Maxwell terms [4]. The effective reduction of eddy current effects on flow quantification was established with recent scanners. Further developments include parallel imaging techniques in space and time [5, 6], but these techniques are not widely available. Among others [7], generally accepted clinical applications today include measurement of the cardiac output especially after cardiac surgery [8], quantification of shunt volumes in congenital heart disease [9], and evaluation of valvular anomalies after inconclusive echocardiography [10].

1 For flow measurements in the large vessels of adults, ventral and dorsal body coils are recommended. Small children may be investigated by a combination of the head coil and the large flex coil.

2 Infants are preferably examined in the knee coil.

Technical Requirements

Over the last years, most research on and clinical application of flow measurements utilized 1.5 Tesla scanners. But as with other sequence techniques, 3 Tesla will provide a marked increase in signal-to-noise ratio, which was shown to be of up to 79% in MR flow measurements [11].
In every flow measurement, Maxwell-terms and eddy currents may degrade the quantitative results. Therefore it is highly advisable to perform accurate positioning of the target vessel in the center of the main field (B_0), especially along the z-axis. For quantification of vascular flow an appropriate ECG-triggering is mandatory. Triggering may be done prospectively, if high temporal resolution is required, or retrospectively, in the case of most clinical examinations. Triggering should be done without any time delay, which is unavoidable if certain devices are used – some devices cause a delay of up to 40 ms! With prospective triggering, for example, 40 ms delay results in data loss of the first parts of systole.
All vendors supplied their scanners with flow measurement sequences, which are often referred to as phase contrast mapping measurements that

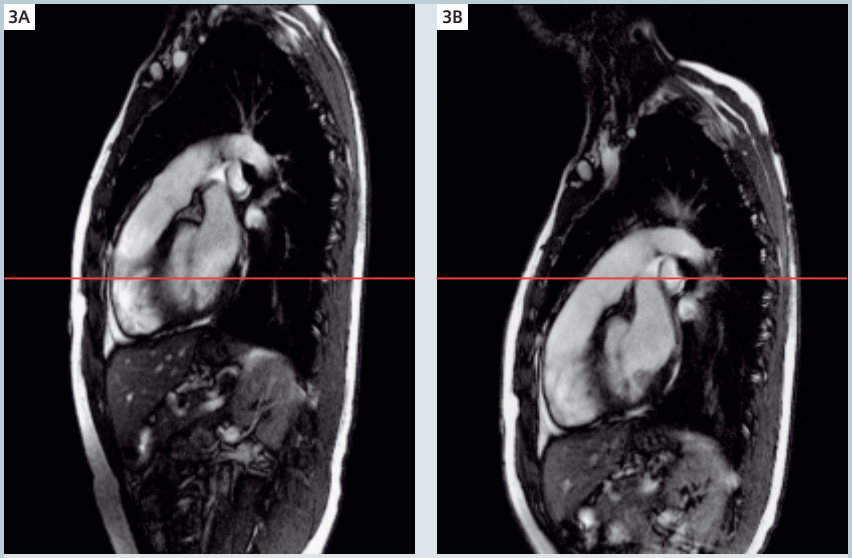

3 When the heart is centered in the B_0 field (red line in Fig. 3A) the main pulmonary artery (MPA) will be a few cm above the B_0 center. The next scout image at the isocenter verifies the centered position of the MPA (Fig. 3B) resulting in the highest accuracy for flow measurements in this vessel.

utilize simple gradient echo techniques. But new sequence designs for flow measurements receive increasing attention.

For flow measurements in the large vessels of adults, ventral and dorsal body coils are recommended. Small children may be investigated by a combination of the head coil and the large flex coil (Fig. 1). Infants are preferably examined in the knee coil (Fig. 2)! The temporal resolution of MR flow measurements cannot compete with echocardiography. Without application of parallel imaging techniques all available scanners should provide a best temporal resolution of about 10 ms with prospective triggering. But for most clinical applications in large vessels (e.g. main pulmonary artery [MPA]) 30 ms may be sufficient.

As a rule of thumb, the selected spatial resolution should at least provide four flow pixels within the acquired vessel to generate reliable flow quantification, but: the more, the better. While the large vessels and the renal arteries may be sufficiently analyzed [12], the flow quantification of the coronary arteries is challenging [13].

The size of the velocity encoding gradients has to be defined before image acquisition. This is usually done with the so-called VENC, which may be set to 150 cm/s in the ascending aorta and 130 cm/s in the main pulmonary artery. For flow data acquisition near valves it is mandatory not to include any parts of the leaflets into the quantification region of interest (ROI) during any part of the cardiac cycle. Therefore, the acquisition plane should be about 1–2 cm above the valves in diastole (cardiac contraction during systole will displace the valves caudally).

The last major prerequisite is sufficient flow analysis. Basic algorithms are provided by the vendors, but more comprehensive and comfortable software is available.

Optimized planning of the acquisition plane in the MPA

To optimize the accuracy of MR flow data, the analysis area ROI in the MPA should be centered in the B_0-field, especially in the z-axis. For cardiac MR examinations, the technologist usually centers the heart in the B_0-field. The resulting sagittal scout image (axial images are not useful) at the isocenter (red line in Fig. 3) shows the MPA approximately 5 cm above the B_0 center (Fig. 3A). Using the coordinate display available on the scout images loaded to the EXAM-card, the required repositioning distance (direction out with respect to standard cardiac examinations) of the scanner table can be measured. The correct acquisition position can be adjusted at any time point of any cardiac examination without repositioning the patient on the scanner table. The next scout image at the isocenter verifies the centered position of the MPA (Fig. 3B) resulting in the highest accuracy for flow measurements in this vessel. Subsequently, several axial images from the upper part of the left pulmonary artery down to the right ventricle clarify the double-oblique course of the MPA (Fig. 4).

The following oblique-sagittal image preferably is planned using the three-point-method (represented with red circles) at the following positions: (1) in the center of the right ventricular outflow tract (RVOT) just below the pulmonary valve (Fig. 4C), (2) in the center of the left pulmonary artery just downstream from the MPA bifurcation at its highest point (Fig. 4A), and (3) in the center of the lower left pulmonary artery (Fig. 4B). The resulting image (Fig. 5A) nicely displays the MPA from the pulmonary valve to the bifurcation and is used to generate an oblique coronal image (Fig. 5B) using the perpendicular tool (right mouse click). To perform flow quantification of the MPA, orthogonal "through plane" measurements are required.

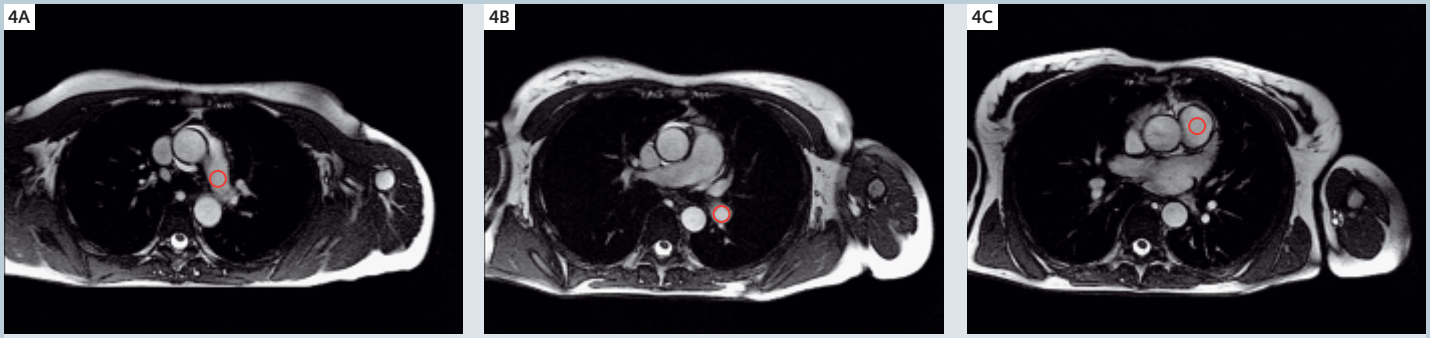

4 The planning of the oblique-sagittal image (Fig. 5A) is preferably planned using the three-point method (represented with red circles) at the following positions: in the center of the left pulmonary artery just downstream from the MPA bifurcation at its highest point (Fig. 4A), in the center of the lower left pulmonary artery (Fig. 4B), and in the center of the right ventricular outflow tract (RVOT) just below the pulmonary valve (Fig. 4C).

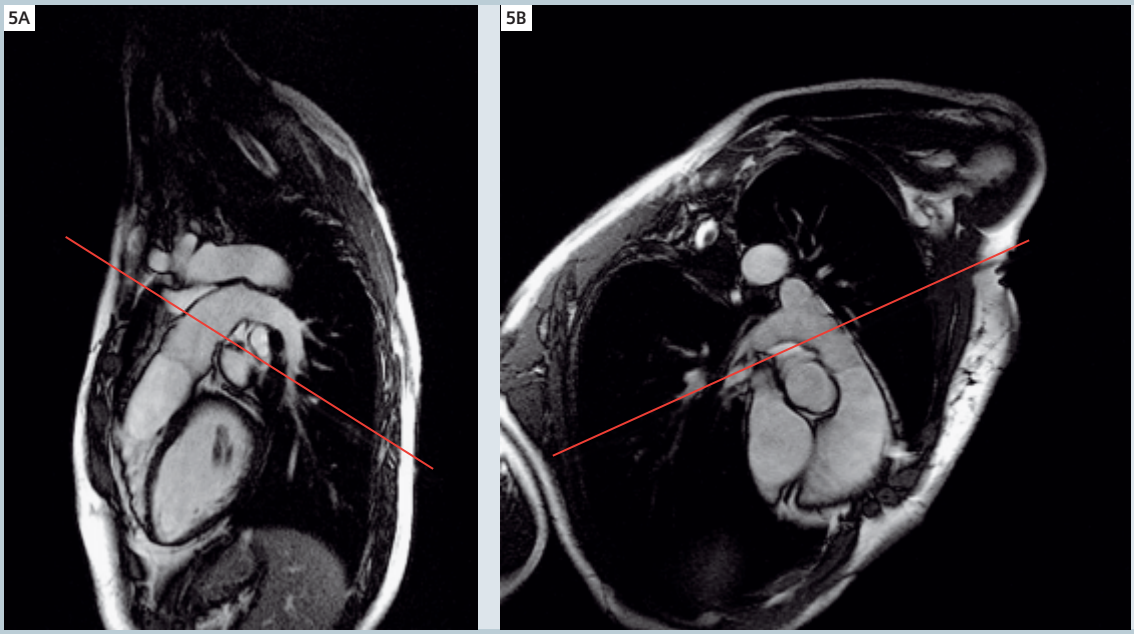

5 Figure 5A nicely displays the MPA from the pulmonary valve to the bifurcation and is used to generate an oblique coronal image (Fig. 5B) using the perpendicular tool (right mouse click). The desired acquisition plane for through-plane flow measurements in the MPA is delineated (red line) and must be perpendicular to both double-oblique scout images.

The desired acquisition plane for flow measurements in the MPA is delineated in Figure 5 (red line) and must be perpendicular to both double-oblique scout images. For highest accuracy, the flow acquisition should not deviate more than 15° from perpendicular to the flow in the MPA. Comprehensive reports on basic MR flow measurement techniques [14] and of MR flow measurements in the MPA have been published [15].

Data acquisition

To determine the true physiological situation of the patient lying in the scanner in supine position, flow measurements should be performed under free-breathing conditions. Scanning in inspiration will significantly reduce the true cardiac output [16] and expiratory breath-holding might not be reproducible. Detectable breathing related motion artifacts are excluded by the use of long term averaging (sequence tab). Furthermore, three averages should be acquired. The resulting scanning time will be dependent from the number of cardiac cycles needed to acquire the data at a given temporal and spatial resolution. A further advantage of the longer acquisition time is the increase of averaging over the cardiac cycle during different breathing positions. Slice thickness is 5 mm in adults, 4 mm in children and 3 mm in infants.
For many clinical applications, retrospective gating is favorable (fl_fq_retro). Using fast HF- and gradient settings, two segments and a bandwidth of 369 Hz/Px, a TE of 3 ms and a TR of 27 ms are possible. Arrhythmia-detection may be used for arrhythmic patients and children, but is not manda-

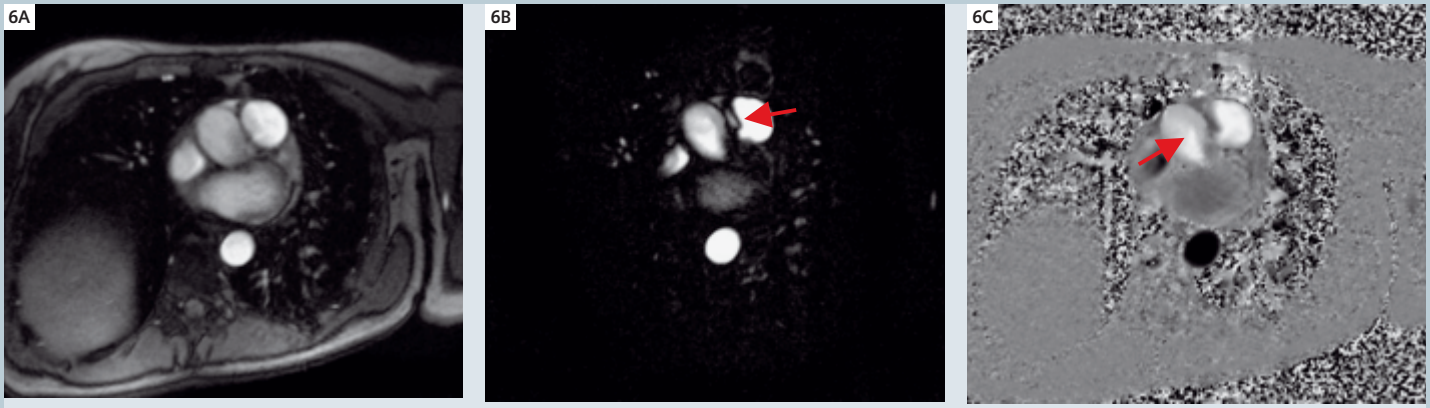

6 Images generated by the flow measurement: rephased (= anatomical; Fig. 6A), magnitude (motion is bright and no velocity information for quality control; Fig. 6B), and phase images (velocity information for quantification; Fig. 6C). All of them are visualized using the Siemens Argus Flow® software. Figure shows systolic images revealing the maximum flow; note that even during systole, some parts of the vessel lumen show very low flow (red arrows).

tory in most of the patients. In adults, the field of view is 320 mm, matrix is 256, phase resolution is 100% and FoV-phase is 87.5%. For optimized flow quantification, up to 40 phases along the cardiac cycle should be reconstructed.

For selected patients, prospective triggering may be favorable (fl_fq). Using fast HF- and gradient settings, one segment and a bandwidth of 1395 Hz/Px, a TE of 2.6 ms and a TR of 9.8 ms (equaling the true temporal resolution of this sequence) are possible. The acquisition window is set to 90% of the average cardiac cycle. In arrhythmic patients and children (respiratory arrhythmia) sometimes only 85% of the cardiac cycle is measurable. The disadvantage is small, since only small amounts of blood are moved through the MPA during late diastole. The major advantage is the possibility to acquire flow data from every 10 ms in the cardiac cycle, especially in early systole. In adults, the field of view is 320 mm, matrix is 256, phase resolution is 93% and FoV-phase is 75%.

It is recommended to reconstruct all available images generated by the flow measurement sequences, i.e. rephased (= anatomical; Fig. 6A), magnitude (motion is bright and no velocity information for quality control; Fig. 6B), and phase images (velocity information for quantification; Fig. 6C). All of them are visualized using the Siemens Argus Flow® software. The rephased images are used to draw the analysis ROI, quantification will be calculated by the phase images. In Figure 6, systolic images revealing the maximum flow are displayed. Note that even during systole, some parts of the vessel lumen show very low flow (red arrows)!

Clinical application

Normal values of the pulmonary circulation in children [17] and adults [18] have been published. The major indication for pulmonary flow measurements in infants and children is the quantification of shunt volumes in ventricular septal defects [19], which is not accurately possible using other non-invasive methods. Furthermore, MR flow measurements can provide important information in many congenital cardiac anomalies [20]. Developing pulmonary arterial hypertension (PAH) in children and adults suffering from cystic fibrosis has been detected with MR flow measurements [21] and an experimental model for the quantification of PAH has been published [22]. In adults, the quantification of PAH using MR flow measurements has been investigated by several groups [23–33] and MRI with combined morphological and functional techniques has been developed to a major diagnostic tool in chronic thrombembolic pulmonary hypertension [34].

Conclusion

The expansion of morphological findings by functional data made achievable with flow measurements of the MPA adds valuable information to the clinical diagnostic algorithm in several cardiopulmonary diseases.

Contact
PD Dr. med. habil. Nasreddin D. Abolmaali
OncoRay – Center for Radiation Research in Oncology
Medical Faculty Carl Gustav Carus, TU Dresden
Fetscherstrasse 74, Haus 31, Pf 86
01307 Dresden
Germany
Phone: +49 351 458 7414
Fax: +49 351 458 7311
Website: www.oncoray.de

References

1 Singer JR. Blood flow rates by nuclear magnetic resonance measurements. Science 1959;130:1652–3.
2 Nayler GL, Firmin DN, Longmore DB. Blood flow imaging by cine magnetic resonance. J Comput Assist Tomogr 1986;10:715–22.
3 Gatehouse PD, Keegan J, Crowe LA, et al. Applications of phase-contrast flow and velocity imaging in cardiovascular MRI. Eur Radiol 2005;15:2172–84.
4 Bernstein MA, Zhou XJ, Polzin JA, King KF, et al. Concomitant gradient terms in phase contrast MR: analysis and correction. Magn Reson Med 1998;39:300–8.
5 Tsao J, Boesiger P, Pruessmann KP. k-t BLAST and k-t SENSE: dynamic MRI with high frame rate exploiting spatiotemporal correlations. Magn Reson Med 2003;50:1031–42.
6 Tsao J, Kozerke S, Boesiger P, et al. Optimizing spatiotemporal sampling for k-t BLAST and k-t SENSE: application to high-resolution real-time cardiac steady-state free precession. Magn Reson Med 2005 53:1372–82.
7 Glockner JF, Johnston DL, McGee KP. Evaluation of cardiac valvular disease with MR imaging: qualitative and quantitative techniques. Radiographics 2003;23:e9.
8 van Straten A, Vliegen HW, Hazekamp MG, et al. Right ventricular function after pulmonary valve replacement in patients with tetralogy of Fallot. Radiology 2004;233:824–9
9 Rees S, Firmin D, Mohiaddin R, et al. Application of flow measurements by magnetic resonance velocity mapping to congenital heart disease. Am J Cardiol 1989;64:953–56.
10 Kroft LJ, Simons P, van Laar JM, et al. Patients with pulmonary fibrosis: cardiac function assessed with MR imaging. Radiology 2000;216:464–71.
11 Gutberlet M, Noeske R, Schwinge K, et al. Comprehensive cardiac magnetic resonance imaging at 3.0 Tesla: feasibility and implications for clinical applications. Invest Radiol 2006;41:154–67.
12 Bax L, Bakker CJ, Klein WM, et al. Renal blood flow measurements with use of phase-contrast magnetic resonance imaging: normal values and reproducibility. J Vasc Interv Radiol 2005;16:807–14.
13 Schiemann M, Bakhtiary F, Hietschold V, et al. MR-based coronary artery blood velocity measurements in patients without coronary artery disease. Eur Radiol 2006;16:1124–30.
14 Lotz J, Meier C, Leppert A, et al. Cardiovascular flow measurement with phase-contrast MR imaging: basic facts and implementation. Radiographics 2002;22:651–71.
15 Abolmaali N. [Funktionelle Magnetresonanztomographie des Truncus pulmonalis], 1 edn. Lehmanns Media-Lob.de, Berlin 2006.
16 Sakuma H, Kawada N, Kubo H, et al. Effect of breath holding on blood flow measurement using fast velocity encoded cine MRI. Magn Reson Med 2001;45:346–8.
17 Abolmaali ND, Esmaeili A, Feist P, et al. [Reference values of MRI flow measurements of the pulmonary outflow tract in healthy children]. Rofo 2004;176:837–45.
18 Ley S, Mereles D, Puderbach M, et al. Value of MR phase-contrast flow measurements for functional assessment of pulmonary arterial hypertension. Eur Radiol 2007;17:1892–7.
19 Esmaeili A, Hohn R, Koch A, et al. Assessment of shunt volumes in children with ventricular septal defects: comparative quantification of MR flow measurements and invasive oximetry. Clin Res Cardiol 2006;95:523–30.
20 Varaprasathan GA, Araoz PA, Higgins CB, et al. Quantification of flow dynamics in congenital heart disease: applications of velocity-encoded cine MR imaging. Radiographics 2002;22:895–905.
21 Abolmaali ND, Smaczny C, Posselt HG, et al. Flow measurements in the main pulmonary artery of patients with cystic fibrosis (CF) using magnetic resonance imaging (MRI). Journal of Cystic Fibrosis 2003;2:50.
22 Abolmaali ND, Seitz U, Kock M, et al. Assessment of an experimentally induced pulmonary hypertension using high-resolution MR flow measurements in pigs. Proc Intl Soc Mag Reson Med 2003;11:407.
23 von Schulthess GK, Fisher MR, Higgins CB. Pathologic blood flow in pulmonary vascular disease as shown by gated magnetic resonance imaging. Ann Intern Med 1985;103:317–323.
24 Roeleveld RJ, Marcus JT, Boonstra A, et al. A comparison of noninvasive MRI-based methods of estimating pulmonary artery pressure in pulmonary hypertension. J Magn Reson Imaging 2005;22:67–72.
25 Murray TI, Boxt LM, Katz J, et al. Estimation of pulmonary artery pressure in patients with primary pulmonary hypertension by quantitative analysis of magnetic resonance images. J Thorac Imaging 1994;9:198–204.
26 Bouchard A, Higgins CB, Byrd BF, et al. Magnetic resonance imaging in pulmonary arterial hypertension. Am J Cardiol 1985;56:938–42.
27 Kondo C, Caputo GR, Masui T, et al. Pulmonary hypertension: pulmonary flow quantification and flow profile analysis with velocity-encoded cine MR imaging. Radiology 1992;183:751–8.
28 Bogren HG, Klipstein RH, Mohiaddin RH, et al. Pulmonary artery distensibility and blood flow patterns: a magnetic resonance study of normal subjects and of patients with pulmonary arterial hypertension. Am Heart J 1989;118:990–9.
29 Mohiaddin RH, Paz R, Theodoropoulos S, Firmin DN, et al. Magnetic resonance characterization of pulmonary arterial blood flow after single lung transplantation [see comments]. J Thorac Cardiovasc Surg 1991;101:1016–23.
30 Mousseaux E, Tasu JP, Jolivet O, et al. Pulmonary arterial resistance: noninvasive measurement with indexes of pulmonary flow estimated at velocity-encoded MR imaging-preliminary experience. Radiology 1999;212:896–902.
31 Henk CB, Schlechta B, Grampp S, et al. Pulmonary and aortic blood flow measurements in normal subjects and patients after single lung transplantation at 0.5 T using velocity encoded cine MRI. Chest 1998;114:771–9.
32 Paz R, Mohiaddin RH, Longmore DB. Magnetic resonance assessment of the pulmonary arterial trunk anatomy, flow, pulsatility and distensibility. Eur Heart J 1993;14:1524–30.
33 Tardivon AA, Mousseaux E, Brenot F, et al. Quantification of hemodynamics in primary pulmonary hypertension with magnetic resonance imaging. Am J Respir Crit Care Med 1994;150:1075–80.
34 Kreitner KF, Kunz RP, Ley S, et al. Chronic thromboembolic pulmonary hypertension – assessment by magnetic resonance imaging. Eur Radiol 2007;17:11–21.