

Hepatic Arterial Chemoembolization Supported by syngo DynaCT

Courtesy of Thomas J. Vogl, M.D.

Diagnostic and Interventional Radiology, Johann Wolfgang Goethe University, Frankfurt/M, Germany

Patient history

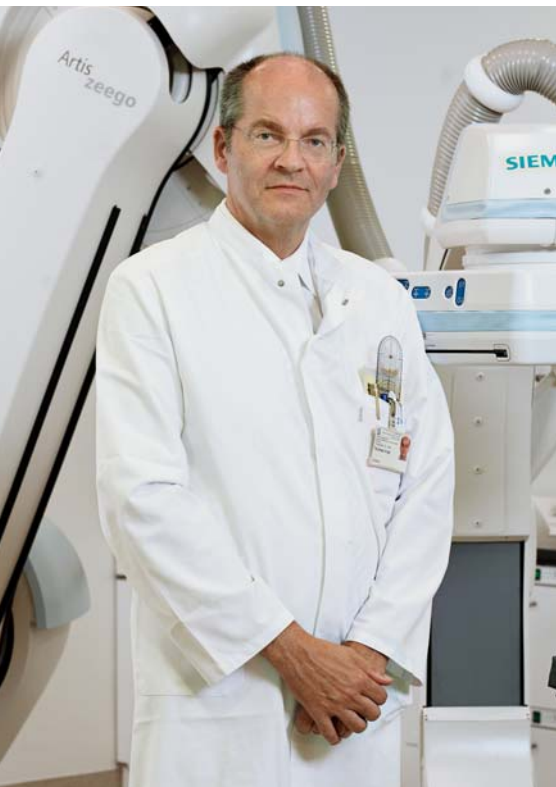A 67-year-old male

Diagnosis

Liver tumor metastasis

Treatment

The tumor metastasis already measured 5 x 5 cm in the right lobe of the liver and originated from colorectal carcinoma. A decision was made for chemoembolization. Therefore a 5 French sidewinder catheter was positioned in the celiac trunk and a 3 French microcatheter was selected for the right hepatic artery.



Prof. T. Vogl, M.D. and the newly installed Artis zeego at Johann Wolfgang Goethe University, Frankfurt/M, Germany

Examination protocol

Primary reconstruction

Mode	DynaCT Full HU Normal
Matrix	512 x 512

Contrast medium injection parameters

Quantity	57 cc
% Contrast (dilution with saline)	33 %
Injection rate	3 cc/sec.
Injection duration	19 sec.
X-ray delay	3 sec.
Catheter type / size	5F Sidewinder / 3F Microcatheter
Injection site	right hepatic artery
Iodine concentration	320 mg / cc

Viewing and post-processing

VRT	yes
MPR	yes
Slice thickness	0.7 mm
Window levels	W231 / C55

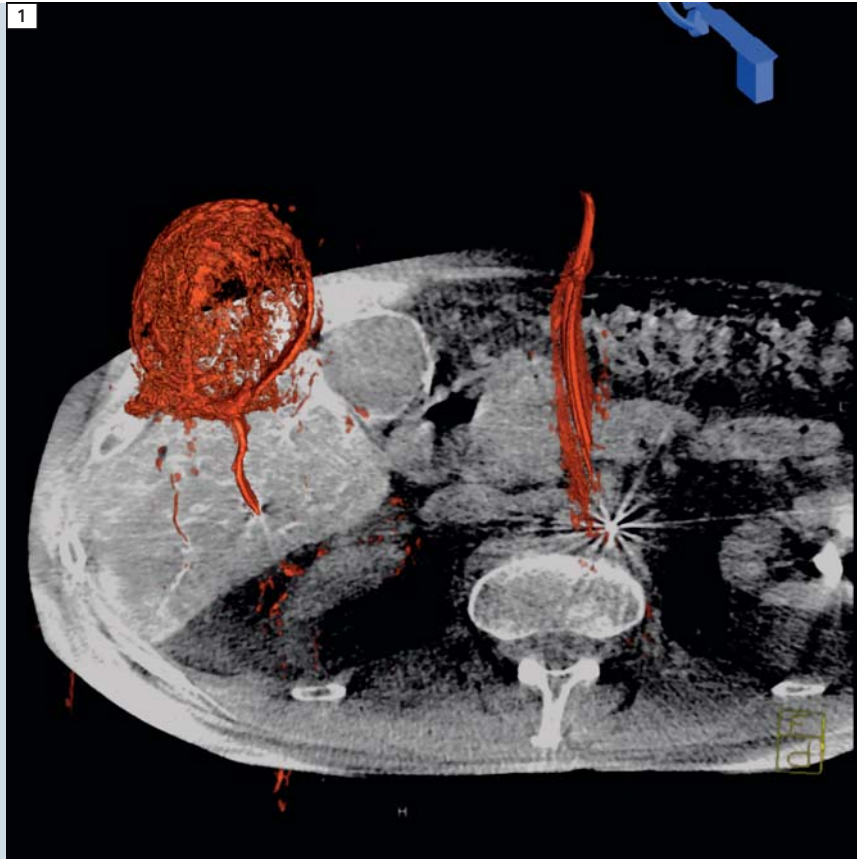
Secondary reconstruction

Mode	DynaCT
VOI	manual
Slice matrix	512 x 512
Kernel	EE
Image characteristics	sharp

Contact

vera.juennemann@siemens.com

1 Embedded MPR visualization by syngo iIdentify.



2 syngo InSpace VRT reconstruction.

