

# Pulmonary Valve Replacement Supported by syngo DynaCT Cardiac

Courtesy of Prof J. Hess, M.D., FESC,  
A. Eicken, M.D., S. Fratz, M.D.  
Department of Paediatric Cardiology  
and Congenital Heart Defects,  
German Heart Center Munich,  
Technical University Munich, Germany

## Patient history

18-year-old male (60 kg)

## Diagnosis

Stenosis of right ventricular-pulmonary artery conduit (homograft) after surgical correction of Tetralogy of Fallot.

## Treatment

Patient was in general anaesthesia and his arms were fixed beside the head. For the syngo DynaCT Cardiac run, the artificial respiration was intermittently stopped to enable best imaging.

## Comments

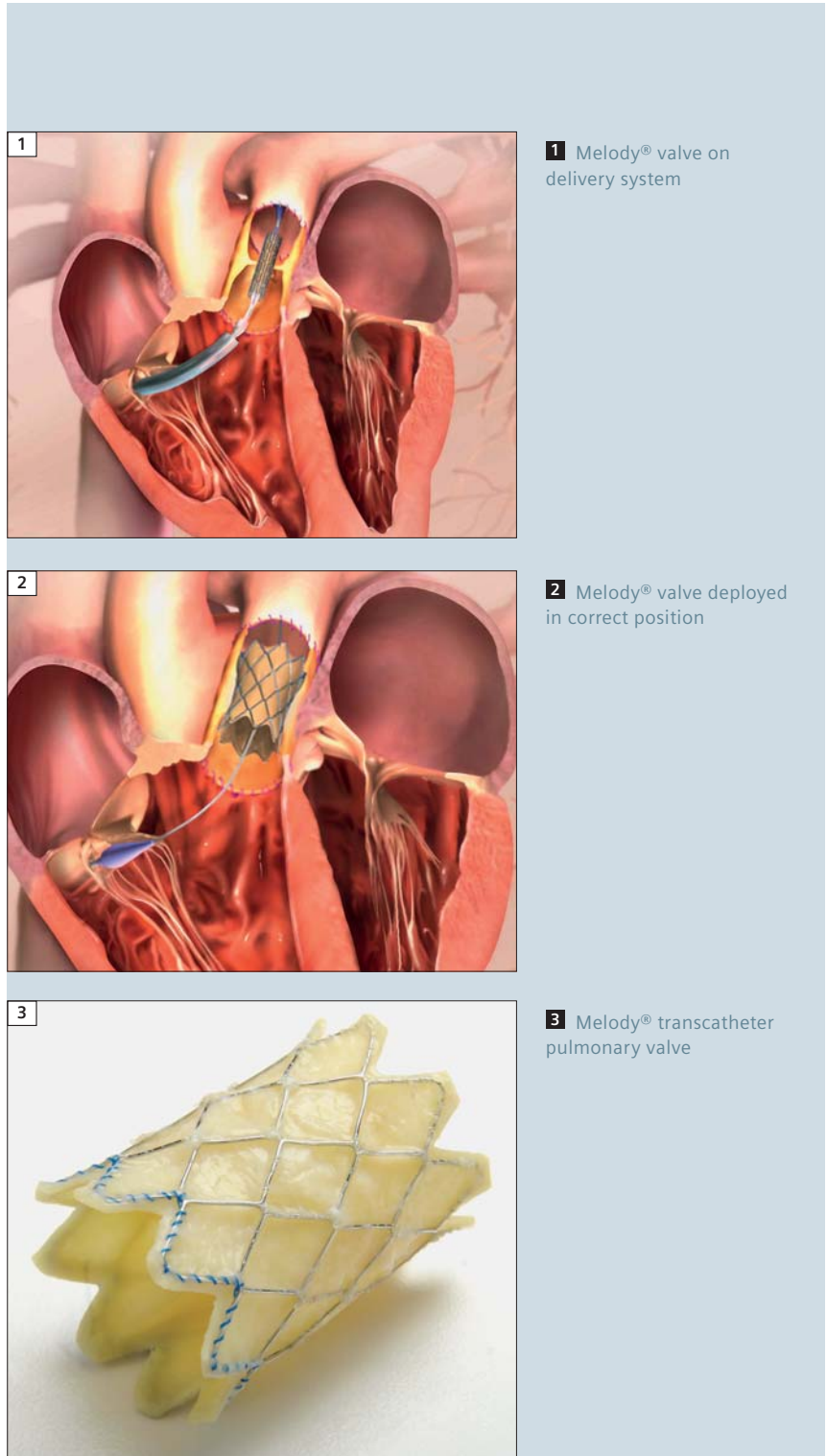
The three-dimensional imaging of the coronary arteries and the inflated balloon in the conduit helped to decide whether a transcatheter insertion of a Melody valve without coronary compression was possible. An injection of 25 cc contrast medium was adequate for complete imaging during the whole procedure and syngo DynaCT Cardiac 3D reconstruction.

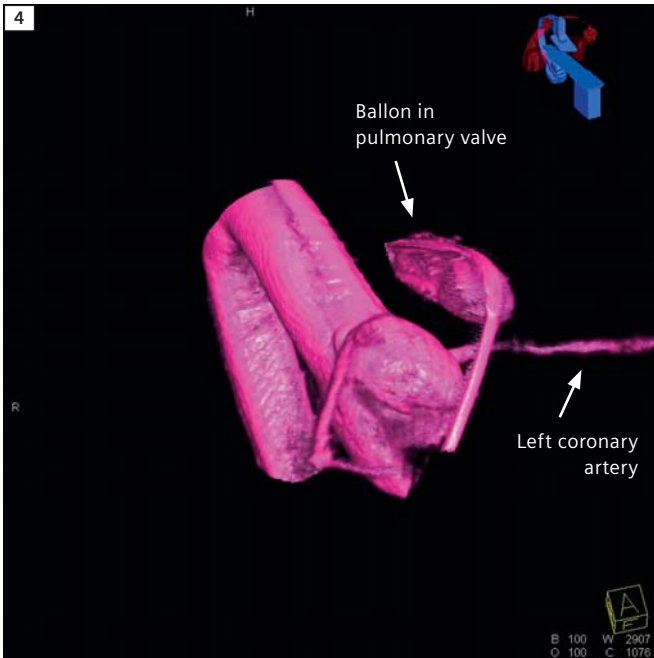
## Examination protocol

Imaging protocol	5 sec DR
Quantity (diluted)	75 cc
Contrast dilution	25 cc to 75 cc (1:3)
Injection rate	15 cc/sec
Injection duration	5 sec during Rapid RV pacing
Rapid RV Pacing	200 bpm
X-ray delay	1 sec

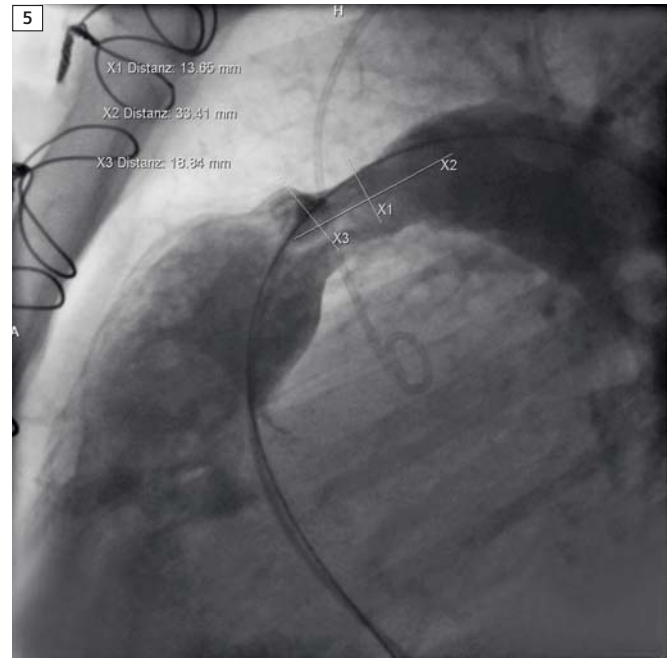
## Contact

nadine.meru@siemens.com

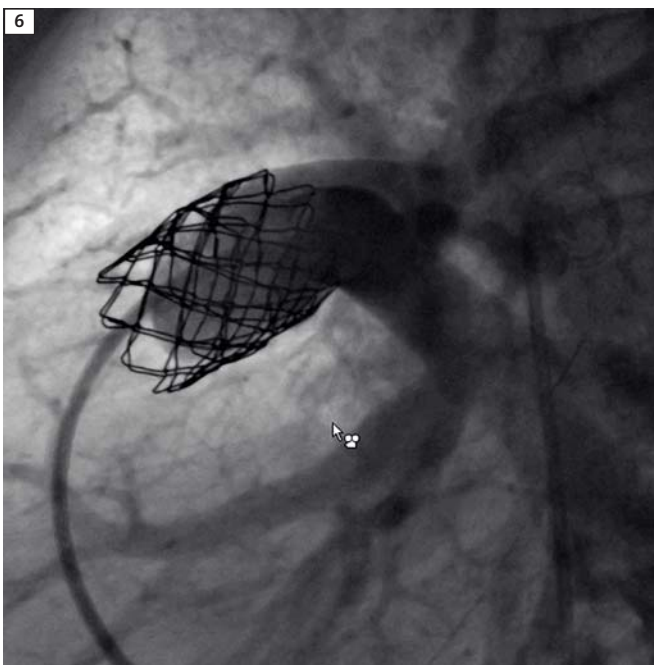




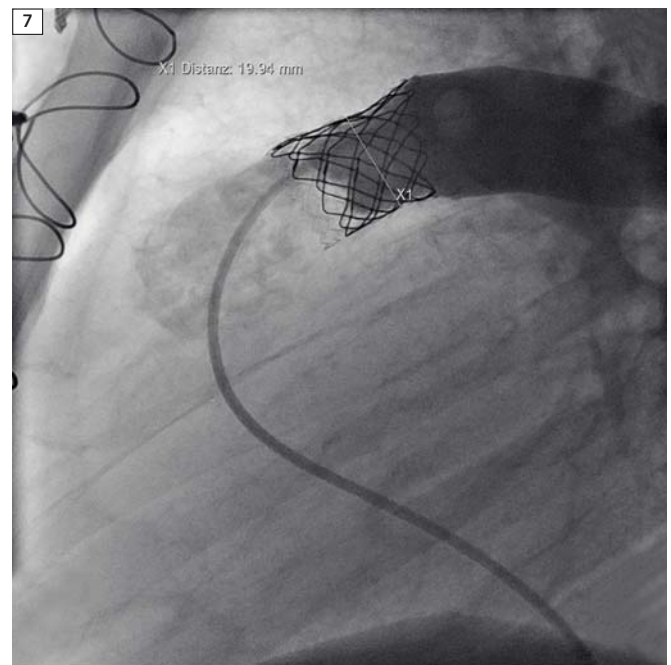
**4** 3D visualization of the inflated balloon in the conduit (pulmonary artery).



**5** Calcified homograft (injection in lateral position).



**6** Verification of the implantation of the stent.



**7** Melody® valve in position.