

Cardiac Resynchronization Therapy Supported by *syngo* DynaCT Cardiac

Courtesy of K.-J. Gutleben, M.D., G. Nölker, M.D. A. Sinha, M.D., J. Brachmann, M.D.,
Department of Cardiology, Klinikum Coburg, Germany

Patient history

A 65-year-old man with ischemic cardiomyopathy and a history of anterior myocardial infarction suffered from New York Heart Association class III symptoms despite optimal medical treatment.

Diagnosis

Left ventricular ejection fraction was severely reduced, echocardiographic signs of dyssynchrony and left bundle branch block were present. For further treatment a cardiac resynchronization therapy (CRT) device implantation was indicated.

Treatment

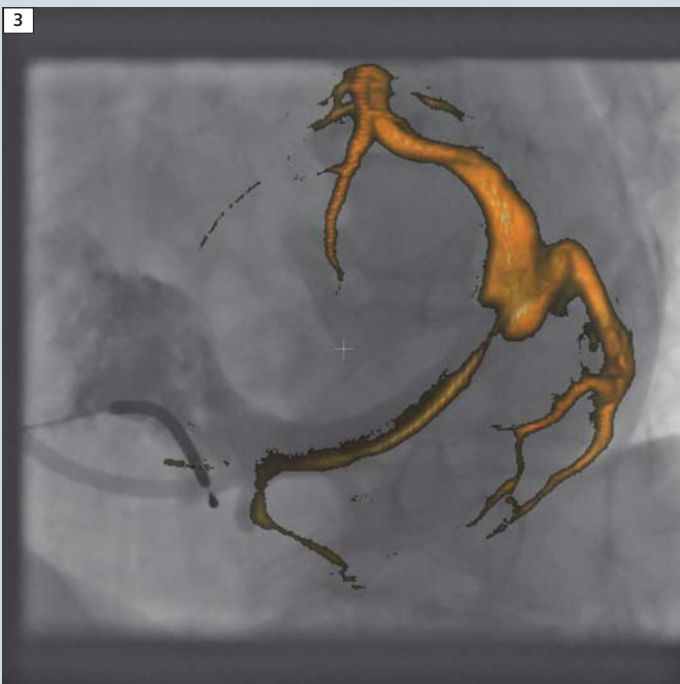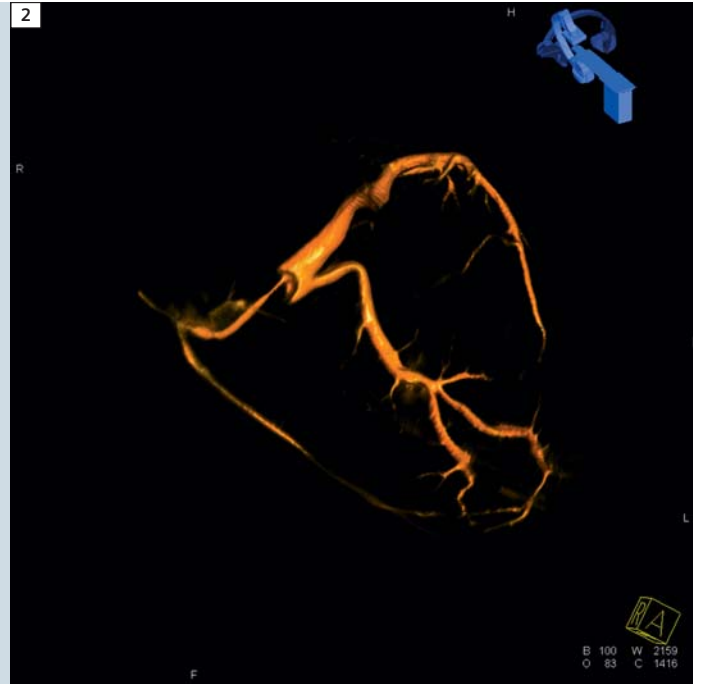
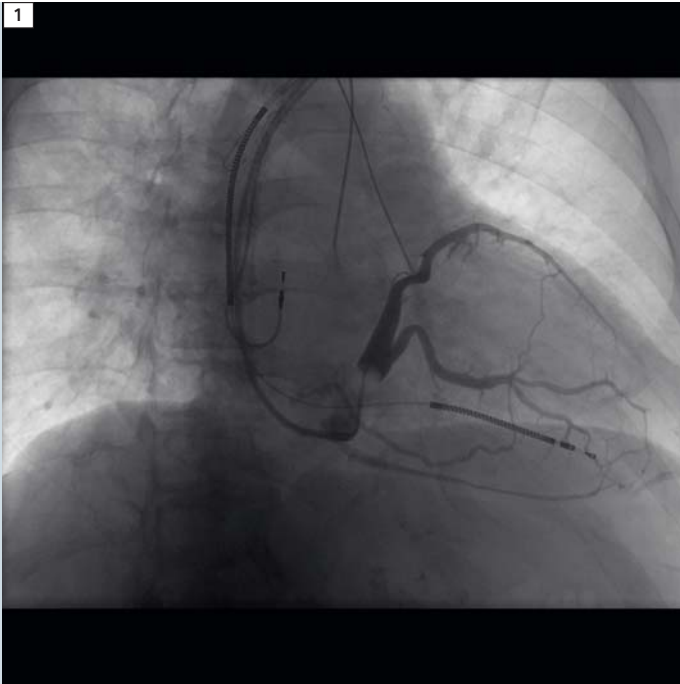
After implanting a right atrial pacing lead and a right ventricular shock electrode through the left subclavian vein another access to the venous system was established. A guiding catheter was inserted through the right atrium into the coronary sinus. A small bolus of contrast media confirmed the correct positioning of the sheath within the coronary sinus before an occlusion balloon catheter was advanced. Consecutively a rotational angiography was performed using *syngo* DynaCT Cardiac while the inflated balloon occluded the coronary sinus. Afterwards the coronary sinus was reconstructed and segmented three dimensionally by using *syngo* InSpace software. The 3D reconstruction was integrated into real-time fluoroscopy. This overlay using *syngo* iPilot software facilitated transvenous pacing lead implantation into the left marginal target vein. After removing the sheaths all implanted leads were connected to the biventricular implantable cardioverter-defibrillator (ICD) and the device was

implanted into the left pectoral pocket. Final tests showed sensing and pacing parameters as well as adequate detection and termination of ventricular fibrillation. Postoperatively the echocardiographic parameters of asynchrony and the clinical status of the patient had improved.

Comments

The three-dimensional imaging of the LCA and the inflated balloon helped in deciding whether an interventional procedure would be possible. Additionally, no selective coronary injections were necessary because of this 3D visualization. Thus 25 cc contrast medium was enough for imaging during the whole procedure and *syngo* DynaCT Cardiac delivered images in high resolution necessary for making the critical determination between interventional treatment and open heart surgery.

Contact
nadine.meru@siemens.com



1 Rotational angiography for acquisition.

2 Representation of the optimal angle for later interventional treatment.

3 Overlay with syngo iPilot.