

Cardiac diagnostics have reached a turning point. Coronary computed tomography angiography increasingly replaces cardiac catheterization, while cardiovascular magnetic resonance imaging tends to replace stress-echocardiography and myocardial scintigraphy. What needs to be decided is the place the two modalities occupy in the clinical decision process.

By Hildegard Kaulen, PhD

Coronary artery disease: yes or no?

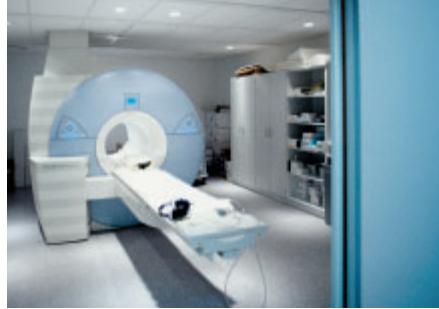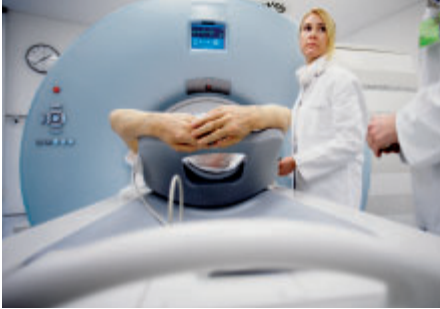Every physician is confronted with this question when examining a patient with pain in the vicinity of the heart and tightness in the chest. A conclusive answer is provided by coronary angiography, where a flexible catheter has to be placed directly into the coronary arteries. However, a balloon dilatation with stent implantation or a bypass surgery is not necessary in all patients. The invasive coronary angiography then serves merely to rule out coronary artery disease (CAD). Coronary computed tomography angiography (CTA) can reduce the number of invasive procedures because it reliably recognizes coronary stenoses. Current efforts involve the development of a modern diagnostic algorithm for diagnosing CAD, which includes this method. At the University Medical Center Mannheim, Germany, radiologists and cardiologists developed and tested this kind of algorithm in close cooperation. The participants include the Institute for Clinical Radiology and Nuclear Medicine headed by Stefan Schönberg, MD, and the 1. Medical Clinic headed by Martin Borggrefe, MD. In addition, Mannheim is involved in examining how to further reduce radiation exposure through intelligent protocols. For this purpose, Schönberg

and his Section Chief for Cardiothoracic Imaging, Christian Fink, MD, received a grant from the German Federal Office for Radiation Protection.

The medical faculty at Mannheim is well prepared for these types of questions. It is a stronghold of medical engineering, offering a master's degree in medical physics, and will hold an endowed chair for radiation physics in the near future. Imaging with computed tomography (CT) and magnetic resonance (MR) is performed with two high-end systems from Siemens at the Institute for Clinical Radiology and Nuclear Medicine: the Dual Source CT scanner SOMATOM® Definition and the MR system MAGNETOM® Avanto. In 2008, the institute also put a 3 Tesla MAGNETOM Trio into operation. It is beyond question for Schönberg that imaging procedures are a core discipline of medicine as well as an integral part of the overall disease management effort. That's why close cooperation with clinical colleagues is so important for him: "We are looking at the definition and implementation of the entire process, from diagnosis to treatment and follow-up. When coronary heart disease is suspected, the cardiologist first determines the risks of its presence. We then hold joint discussions about the diagnostic approach,

Working together on a reliable diagnostic process for CAD at the University Medical Center Mannheim (from left to right): Christian Fink, MD, Associate Chair of Clinical Operations and Section Chief of Cardiothoracic Imaging of the Institute of Clinical Radiology and Nuclear Medicine; Theano Papavassiliu, MD, Junior Faculty of Cardiac Magnetic Resonance Imaging; Professor Stefan Schönberg, MD, Director of the Institute for Clinical Radiology and Nuclear Medicine; and Tim Süsselbeck, MD, Head of the Cath Lab.





Outstanding diagnostic quality: The University Medical Center Mannheim relies on the high-end CT scanner SOMATOM Definition and the MR system MAGNETOM Avanto.

arrive at the diagnosis, and the cardiologists make the necessary interventions, if required. To this end, we require an excellent workflow since every second counts when suspecting coronary artery disease in an acute setting. In addition, decisions regarding the therapeutic approach have to be supported by hard data more than ever due to our steadily decreasing healthcare resources. The high image quality and the informative value of Dual Source CT supply exactly this data.”

Precise Diagnostics

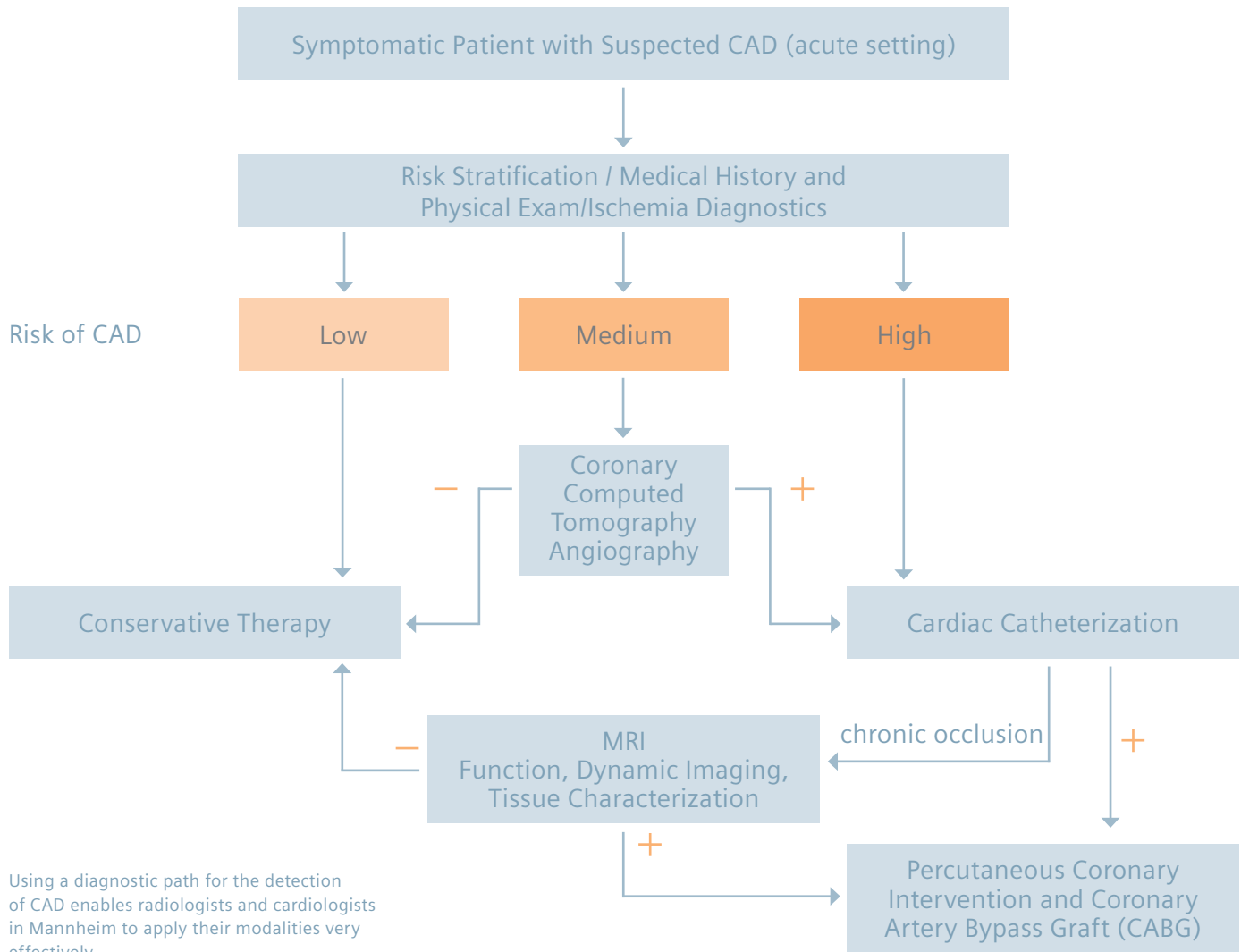
Despite the advances made in treating cardiovascular diseases, it remains the number one cause of death in Western industrial nations and thus has a significant socioeconomic impact. Earlier and more precise diagnosis is a must. Tim Süselbeck, MD, Interventional Cardiologist and Head of the Cath Lab at the University Clinic Mannheim as well as a member of the team working with Schönberg and Borggreffe, explains what is needed to meet this objective: “When suspecting stenotic coronary artery disease, we have to quickly clarify important questions with the patient in mind: Do the coronary arteries show significant stenoses and where are they located? Is there sufficient blood flow in the myocardium at rest and under stress? Which stenoses are hemodynamically relevant? Previously, these questions were answered via cardiac catheterization, echocardiography, and

nuclear diagnostics. Today, contrast-enhanced CTA can be used for excluding relevant stenoses, and cardiovascular MR imaging can be used for evaluating morphology, tissue characterization, and cardiac function. As it were, a 16-slice CT system is considered the minimum prerequisite for CTA. The 64-slice systems are of higher diagnostic efficiency. The best among them is the Dual Source CT.” Whether patients presenting symptoms of angina pectoris should be examined by coronary angiography or CTA is decided by the likelihood of the occurrence of CAD. US associations such as the American College of Cardiology Foundation and the American College of Radiology agree with these findings in their consensus paper.* Süselbeck says, “If the patient has a high risk for CAD, coronary angiography remains the gold-standard diagnostic strategy, because significant coronary stenoses can be treated by balloon dilatation and stent implantation within the same procedure. If you are dealing with a medium risk, additional clarification is planned and a CTA is recommended to exclude relevant narrowing. If the risk is low, conservative treatment is to be applied.” The level of risk assigned to coronary heart disease results from the patient’s history, age, sex, and the findings from a stress-electrocardiogram, as far as it can be utilized. A low value

“We require an excellent workflow, since every second counts when suspecting coronary artery disease.”

Professor Stefan Schönberg, MD,
Chairman of the Institute for Clinical Radiology
and Nuclear Medicine,
University Medical Center Mannheim, Germany

* Editorial remarks are included in *J Am Coll Cardiol* 2006; 48:1475-1492.



represents a risk under ten percent, a medium value addresses risks between ten and 90 percent, while a value above 90 percent is considered a high risk.

High Negative Predictive Value

The strength of CTA lies in its high negative predictive value. According to Fink, "If the data set is conclusive, coronary stenoses can be ruled out at 95 percent probability. Because vessel calcification leads to overexposure in CT diagnostics, it is not always possible to correctly evaluate the internal diameter of vessels. This frequently leads to an overestimation of the severity of the stenosis. For this reason, the positive pretest probability of

CT coronary angiography is lower than the negative one." As vessel calcification is an independent risk factor for a subsequent coronary event, the calcium score provides important additional information for estimating this risk. It is also determined with CT. An iodinated contrast agent is not necessary for this examination. In addition, radiation exposure is lower in this case than with CTA. "If the risk is high, medical treatment with administration of acetylsalicylic acid and cholesterol-lowering medication should be initiated," says Süselbeck. If coronary artery disease can be excluded with a high level of confidence after CTA or when the hemodynamic relevance of

stenoses is to be determined, coronary heart disease imaging diagnostics are applied. These modalities clarify whether there is appropriate blood supply to the myocardium both at rest and in stress. According to present guidelines for diagnostic workflow when suspecting stenotic coronary artery disease, myocardial scintigraphy, stress-echocardiography, and stress-MRI are considered. In myocardial scintigraphy, positron emission tomography (PET) or single photon emission computed tomography (SPECT) are used to measure the uptake of radioactive substance by the cardiac muscle cells – a process that shows cardiac blood circulation. During a stress-echocardiogram,

wall motion abnormalities can be detected, which are caused by severely reduced blood supply. Stress-MRI, on the other hand, provides proof by visualization of wall motion abnormalities or by direct dynamic myocardial imaging.

Myocardial Scintigraphy Becomes Less Important

Theano Papavassiliu, MD, who is a junior faculty member of cardiac magnetic resonance imaging in Mannheim, sees the large advantages offered by an MRI examination. She says, "Its speciality is that it allows for a better differential diagnosis – without radiation exposure. The symptoms of a patient don't necessarily have to relate to coronary artery disease – their cause can also be inflammatory or noninflammatory changes in the myocardial wall, which are a variety of nonischemic cardiomyopathies. This requires careful differentiation. Using cardiovascular MRI, combined assessment of cardiac function, morphology, and tissue characterization within a 45-minute timeframe is possible. For detection of coronary artery disease, especially in patients with intermediate pretest probability, stress cardiac MRI can be performed with dynamic imaging for inducible dynamic defects or stress-induced wall motion abnormalities imaging. This evaluates impairment of myocardial thickening and also indicates underlying coronary heart disease. Additionally, we can determine tissue characterization of the myocardium. This allows us to differentiate healthy tissue from scar tissue, as we can detect the presence, location, and extent of myocardial infarction, and predict improvements in contractile function following revascularization." Schönberg also no longer sees the main role of myocardial scintigraphy in the primary diagnosis of CAD. "Stress-MRI shows a better spatial resolution than myocardial scintigraphy and works without radiation exposure. The 3 Tesla magnet of MAGNETOM Trio further improves spatial resolution, contrast, and speed of acquisition. Parallel acquisition techniques will allow high-resolution functional analyses of the entire heart within a few breathholds. These represent

undeniable advantages for both workflow and patient."

Reducing Radiation Exposure

A modern diagnostic pathway for diagnosing coronary artery disease has to take diagnostic quality as well as radiation exposure into account. Today, the latter is certainly higher with CTA when using conventional CT scanners than with invasive coronary angiography. However, it is difficult to determine the exact dose. It depends on the examination parameters used, such as tube current, tube voltage, and table feed. Furthermore, sex, body constitution, and weight of the patient play a role. In addition, certain tissues are more sensitive to radiation than others, for example, the mammary gland. As radiation exposure is such a major concern in CT, Siemens is constantly working on the development of technologies that reduce radiation dose. SOMATOM Definition, the Dual Source CT used in Mannheim, offers the current lowest possible radiation exposure in cardiac CT. Due to the temporal resolution of 83 milliseconds, the cardiac acquisition time is twice as fast as with a single source CT. That way, the dose for typical heart rate can be cut by up to 50 percent.

Additionally, with the development of their diagnostic path, Schönberg and Fink hope to reduce radiation dose by means of an intelligent and adaptive procedure. "We want to define minimum requirements for the processes to keep the exposure as low as possible", says Fink.

Hildegard Kaulen, PhD, is a molecular biologist. After positions at Rockefeller University in New York and Harvard Medical School in Boston, MA, USA, she has been working as a freelance science journalist for renowned newspapers and scientific journals since the mid 1990s.

Further Information

www.siemens.com/MAGNETOM-Special-2006
www.siemens.com/SOMATOM-Definition

Summary

Challenge:

- Coronary artery disease: the most common cause of death in the Western world
- Making decisions: What does the modern diagnostic pathway for cardiac diseases look like for diagnosing CAD, including CTA and cardiovascular MRI?

Solution:

- Definition of risk groups
- The diagnostic path when suspecting coronary artery disease. High risk: cardiac catheter. Medium risk: CTA to eliminate the suspicion, and coronary heart disease diagnostics with MRI if suspicions are confirmed. Low risk: conservative treatment and determining the ten-year risk for a coronary event
- Overall process from diagnosis to therapy has to be implemented. High requirements to be met by workflow
- CTA and cardiovascular MRI are important modalities for noninvasive cardiac imaging

Result:

- CTA with high negative predictive value enables exclusion of relevant stenoses
- Calcium score helps to calculate long-term risk of coronary event
- Cardiovascular MRI for coronary heart disease diagnostics
- Optimized workflow in radiology through effective use of imaging modalities
- Reduced radiation exposure through intelligent protocols