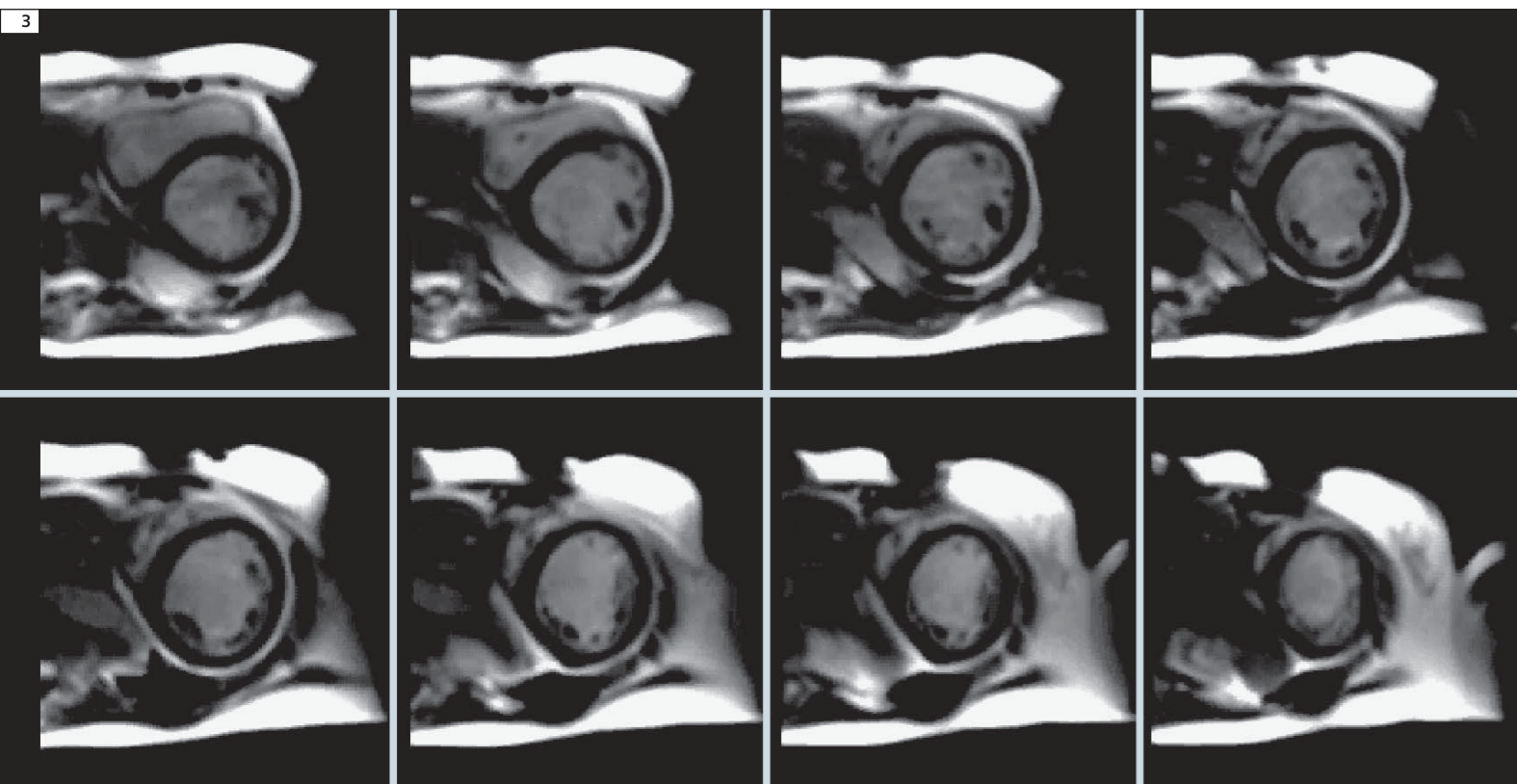

3 In this claustrophobic patient with shortness of breath the tPAT accelerated multi slice real time imaging allowed speedy evaluation of cardiac function. The complete scan was achieved in 10 heart beats for the 10 slices acquired (8 representative slices shown). The ability to perform studies of this quality in such a short time can reduce the number of failed examinations due to breathholding limitations and patient tolerance.

ously achievable. This is a clear benefit especially for patients with dyspnea, a not uncommon condition in cardiac imaging.

Other new features

Some smaller features are introduced with the aim of improving image quality. It is now possible to select if the phase-encoding rewinder is used or not in the dynamic Turbo FLASH protocols – this allows the user to trade off speed of data acquisition against slightly compromised image quality – this is especially true if the operator chooses to use high flip angles in these protocols.

To help with planning scans using the 1D PACE option (mainly coronary imaging) the behavior of the graphics relating to the positioning of the navigator

is changed so that the head to foot off-center position is taken from the graphics during positioning so that if the center of the navigator is placed on the diaphragm this will be the center of the search position in the PACE card. This is of high relevance for a precise and fast set-up especially if the diaphragm position is off-set from the isocenter.

Contact
 Peter Weale
 Siemens Medical Solutions USA, Inc.
 Cardiovascular Research and Development
 737 N Michigan Ave
 STE 1600
 Chicago, IL 60611
 USA
 peter.weale@siemens.com

Improved Workflow and Performance for Contrast-Enhanced MR Angiography Sequences

Gary R. McNeal, MS BME; Yutaka Natsuaki, Ph.D.; Randall Kroeker, Ph.D.; Peter Schmitt; Gerhard Laub, Ph.D.

Siemens Medical Solutions, Inc., USA

The new software version *syngo* MR B17 provides several improvements for *syngo* TWIST (dynamic ceMRA) and FL3D_CE (static ceMRA) sequences, thereby leading to decreased scan time, reduced acoustic noise, and improved workflow.

syngo TWIST (dynamic ceMRA)

- New asymmetric slab-selective RF pulses with better slice profiles allow less slice oversampling, thereby decreasing scan time.
- New symmetric non-selective RF pulses with shorter pulse durations allow shorter TR, thereby decreasing scan time.
- New spiral centric phase-encoding trajectory allows reduced acoustic noise and reduced phase coherence artifacts.
- Switchable phase-encoding rewinder allows shorter TR, thereby decreasing scan time.

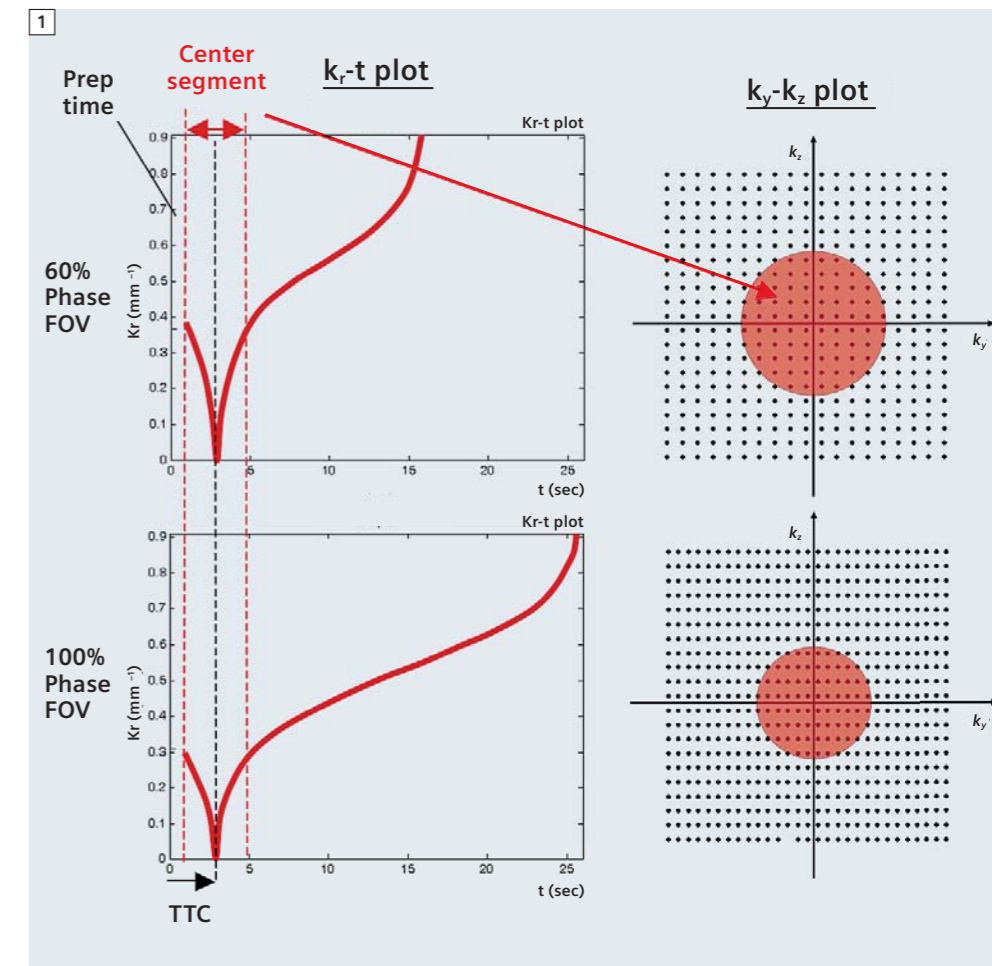
FL3D_CE (static ceMRA)

- All of the above, and:
- Freely-adjustable Time-To-Center (TTC) parameter allows improved workflow and improved visualization of arteries without venous contamination.

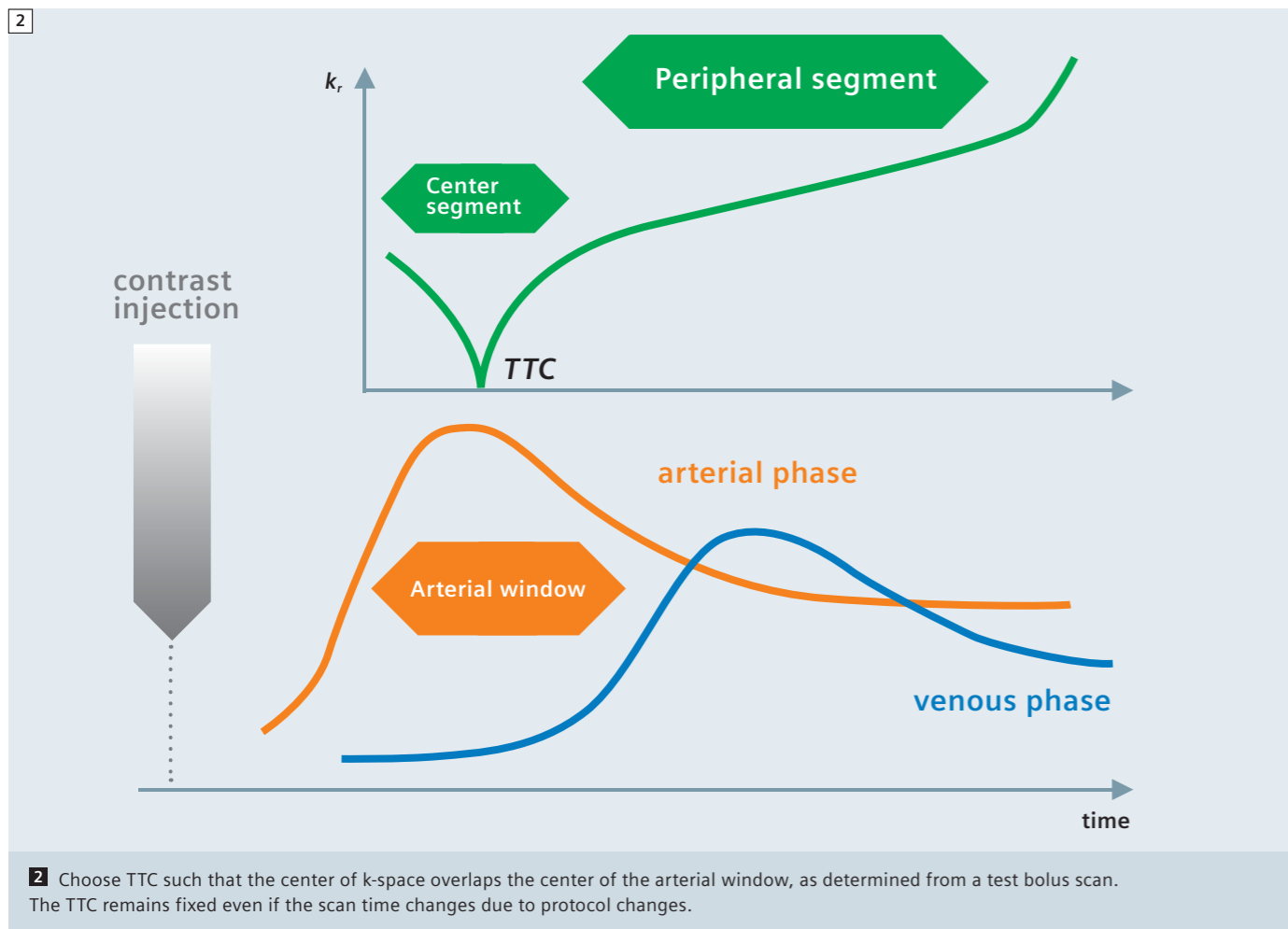
Probably the most significant improvement is the freely-selectable TTC. The FL3D_CE sequence is designed to visualize the signal enhancement in the vessels after the injection of a T1-shortening contrast agent. For the best visualization of the arteries, the center segment of the k_y - k_z plane must be acquired during the first pass of the contrast injection

(Arterial Window). Unlike the previous version of FL3D_CE which only allowed a centric ordering with the trajectory starting at $k_r = 0$, the new version allows the use of a delayed centric ordering where the k -space trajectory starts at the edge

of the center segment moving towards $k_r = 0$, then moves outwards again, and finally scans the region outside of the center segment as shown in figure 1. The selection of k -space points is following a spiral centric trajectory in k -space.



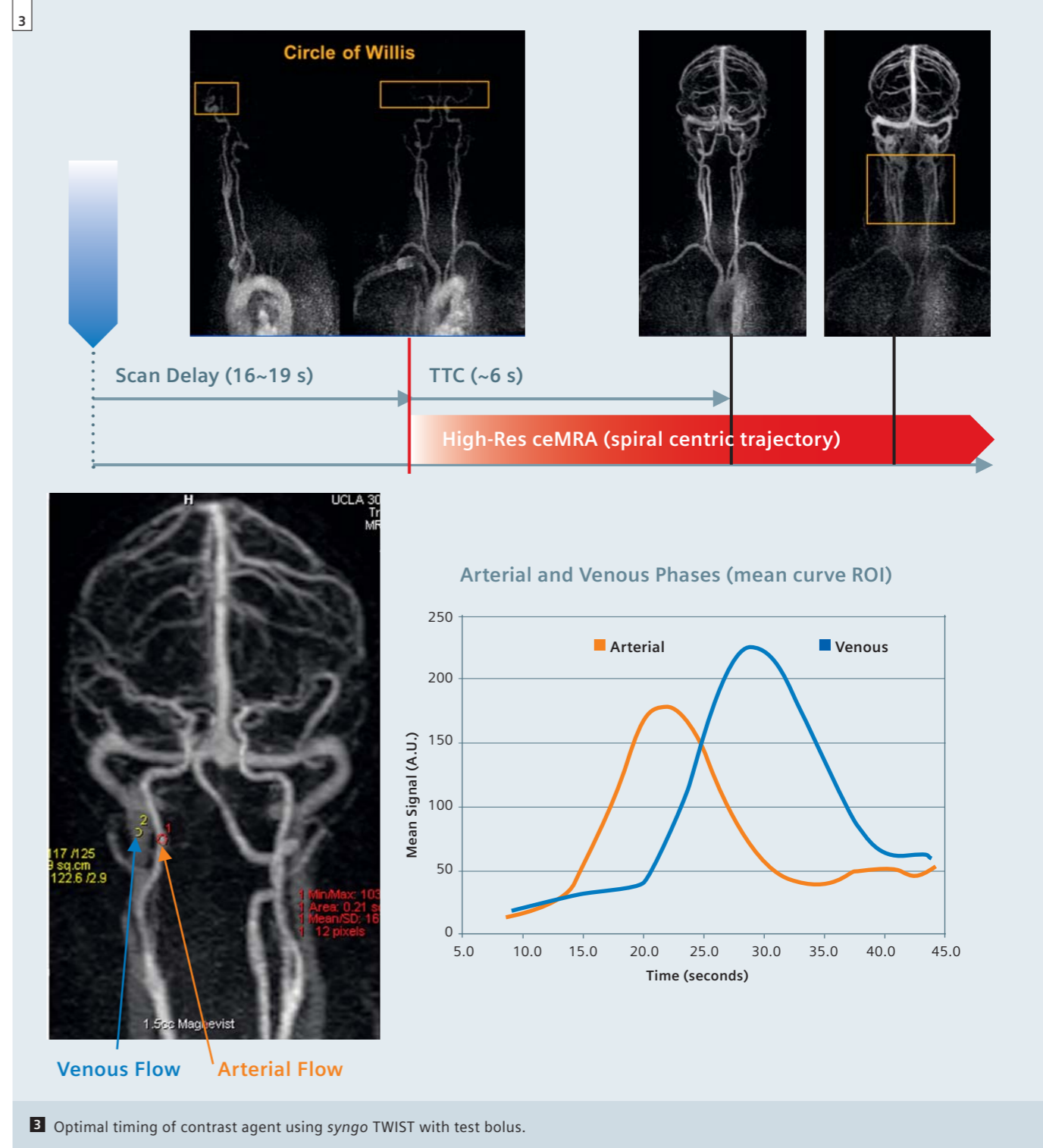
1 k_r - t and k_y - k_z plots of the spiral centric reordering for two different phase FOVs (as an example, 60% and 100%). The center segment of k -space and the TTC remain independent of other sequence parameters that effect resolution and scan duration.



It is important to note that the time-to-center (TTC) is independent of other geometric parameters used in the imaging protocol. For example, if the phase FOV is increased from 60% to 100% as shown in figure 1, the TTC will not change. What happens instead is a corresponding size (area) reduction of the center segment in k-space, while the number of k-space points in the center segment stays the same, independent of the actual value for the phase FOV. Similarly, changing other parameters (e.g., phase and slice resolution, the number of slices, or phase/slice oversampling) will not change the selected value for TTC. This has important practical implications. The center segment can be adjusted to the arterial window as demonstrated in figure 2 independent of the geometric parameters in the protocol, unlike the previous version where the

TTC in the linear sequential phase encode mode (care bolus unchecked) is greyed out, and is always 3/8th of the total scan time. When performing ceMRA using the FL3D_CE sequence, the arteries are best visualized if the center of k-space is acquired only when the arteries are filled with the contrast agent (*arterial window*), thereby avoiding the venous phase. In combination with the new spiral centric trajectory, the new freely-adjustable Time-To-Center (TTC) parameter in *syngo* MR B17 allows the user to more easily and consistently acquire the center of k-space near the center of the arterial window because TTC is independent of other geometric parameters used in the imaging protocol (slices, matrix, FOV, oversampling, partial Fourier). This has important practical implications for workflow and image quality. As

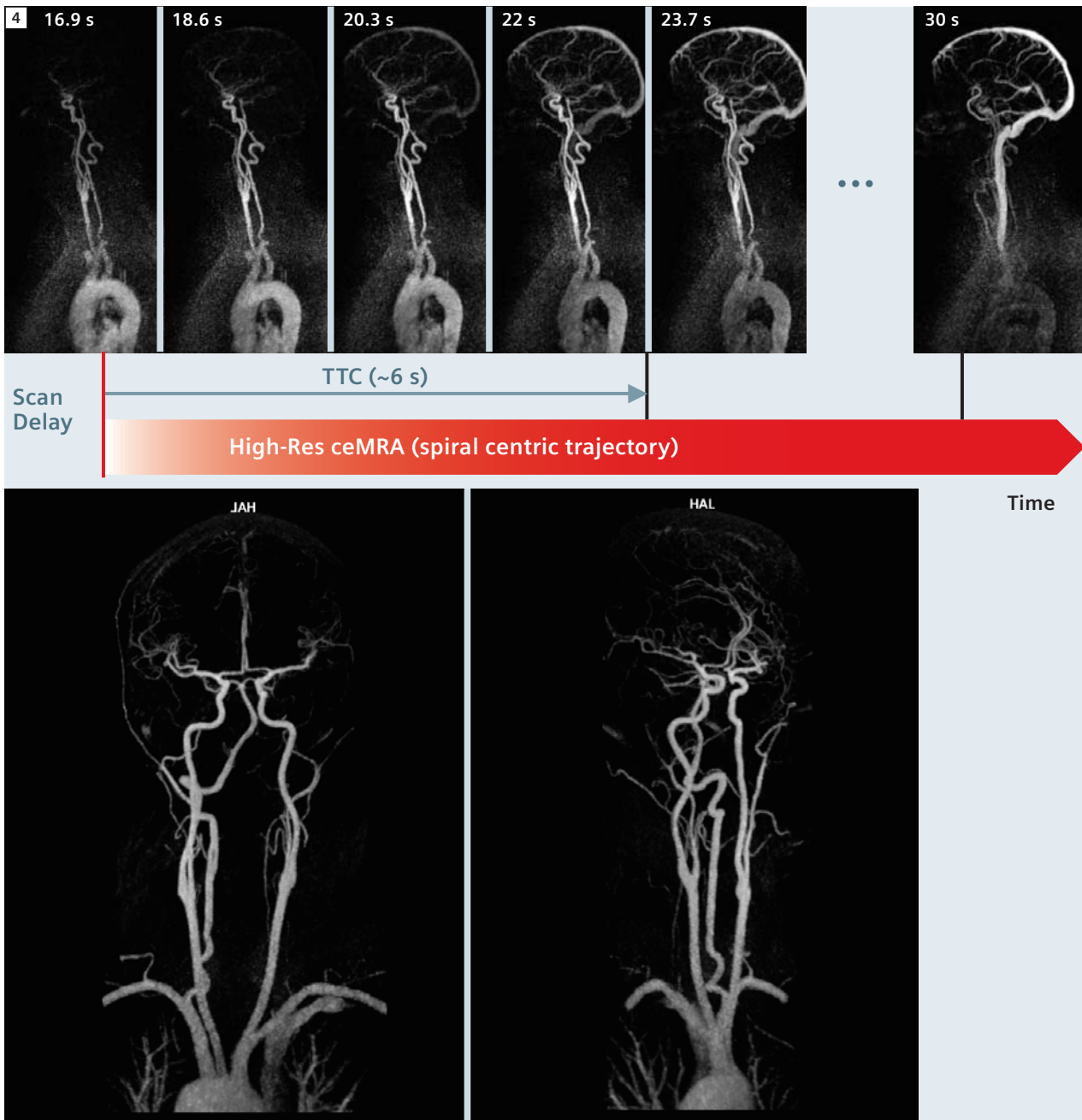
shown in figure 2, by using the new spiral centric trajectory with freely-selectable TTC one can freely change geometric protocol parameters on-the-fly (resolution and slab coverage) without using a complex formula to recalculate the appropriate scan-delay time needed to synchronize the center of k-space to the arterial window. The duration of the center segment remains fixed, while the duration of the peripheral segment increases or decreases to accommodate the protocol changes. This ensures optimal visualization of the arteries without venous contamination. Furthermore, depending on the relation between the cardiac cycle and the duration of the phase encoding loops, ghosting artifacts sometimes occur due to arterial pulsatility when using the older linear phase-encoding method. These newer methods significantly reduce such ghosting arti-



facts because the cardiac motion cannot create any periodic structures in k-space when a centric reordering is used. MR technologists at UCLA Medical Center in Los Angeles, USA have optimized the workflow to consistently yield high quality ceMRA exams of the carotids and intracranial arteries without venous contamination. For over a year this workflow has proven successful on both the 1.5T MAGNETOM Avanto and the

3T MAGNETOM Trio, A Tim System scanners at UCLA. As depicted in figure 3, the arterial window and venous phase are determined from a *syngo* TWIST timing bolus scan (both sagittal and coronal MIPs), but any other test bolus measurement showing the signal intensity in the carotid artery and jugular vein can be used as well. The high-resolution ceMRA scan is started when the test bolus arrives at the Circle of Willis (typically

about 16–19 seconds after injection). TTC is typically set to about 6 seconds, or as needed to ensure that the center of k-space is acquired just prior to jugular vein enhancement. This can be done most easily by reviewing the *syngo* TWIST timing bolus images, or more methodically by assessing the time-intensity curves of ROI's drawn on a carotid artery and a jugular vein, as in figure 3.



4 Results of optimized ceMRA workflow and image quality.

The results of the optimized workflow from UCLA are shown in figure 4. The *syngo* TWIST timing bolus scan shows that the bolus arrived at the Circle-of-Willis at about 17 seconds, which was used for the scan delay of the ceMRA scan. The bolus transit time from carotid arteries to jugular veins was an additional 6 seconds, which was used for the TTC of the ceMRA scan. TTC is reduced for

patients with a faster venous return. The resulting high resolution MIP images of the carotids and intracranial arteries demonstrate full enhancement without venous contamination. In conclusion, the new *syngo* MR B17 version of FL3D_CE with spiral centric reordering does indeed improve workflow and improve image quality of ceMRA.

Contact

Gary McNeal
 Advanced Application Specialist
 Cardiovascular MR R&D
 Siemens Medical Solutions USA, Inc.
 737 N Michigan Ave
 Suite 1600
 Chicago, IL 60611
 USA
 Gary.mcneal@siemens.com