

1



The Mater Misericordiae University Hospital (MMUH) in Dublin, Ireland

MAGNETOM Symphony Tim Upgrade: The Mater Misericordiae University Hospital Experience

Bolster F, Moynagh M, Dolan A, Cradock A, Murray J G

Dept of Radiology, The Mater Misericordiae University Hospital, Dublin, Ireland

The Mater Misericordiae University Hospital (MMUH) is a public, acute voluntary teaching hospital and a tertiary referral center which was established in 1861. Located in Dublin's north inner city it provides a 24 hour on call service to the local and county area and contains approximately 600 beds. The MMUH not only treats patients from its local catchment area but due to its regional and national status, sees patients from all

over Ireland. The MMUH houses the national center for cardiothoracic surgery, the national spinal injuries unit and is a designated national cancer centre. The Radiology Department at the MMUH performed 160,000 radiology studies including over 5000 MRIs in 2008.

Problems

- **Old scanner:** The MMUH had a single 1.5T Siemens MAGNETOM Symphony

scanner in operation since its installation in October 2000.

- **New applications, teaching and research:** As a university teaching hospital and national referral center there was a need to maintain state of the art MR imaging facilities not only for patient care, but also to train radiology and radiography staff as part of national programs, and to facilitate meaningful research programs.

- **Demand for services:** In the first full year of operation 3,200 MR scans were performed. This had risen by 38% to 5,208 MR scans in 2008. However the number of requests for MR had been steadily rising by 5–10% per annum since scanner installation. The waiting list for MR had become unacceptably long necessitating outsourcing of low risk MR studies.
- **Funding:** Any proposal to address the above issues had to be budget neutral. In addition new staff could not be hired due to a government imposed hiring embargo. This precluded purchase of a second scanner.
- **MR in 'Listed Building':** The MR was located in an architecturally preserved 'listed building'. When the scanner was initially installed in 2000, access was gained through an inner back wall via a central courtyard. Since that time further structural building work had taken place in this courtyard which made this route inaccessible. Thus a full upgrade with removal of the magnet bore would have produced serious logistical and secondary cost issues.
- **Downtime:** The MMUH has only a single MR scanner. A short installation time was thus important to ensure continuity of service.

Why the Tim upgrade in the MMUH?

- **Software applications:** Gave access to the same full range of sequences available as if a new magnet purchased. This addressed the clinical, teaching and research issues.
- **Productivity:** We estimated that with the new technology we could increase the throughput in our MR department by about 15% or 3 extra scans per day. With the increase in throughput, we believed that the upgrade would be "cost neutral" over a three-year period of time.
- **Staffing:** No new staff would be required.
- **Architecturally preserved building:** Because the Tim upgrade involved keeping the original magnet bore, the upgrade did not involve building works.
- **Short installation time:** The Tim

upgrade process was estimated to take 10 days to complete. This involved two weekends and as such a loss of just six working days.

Our experience

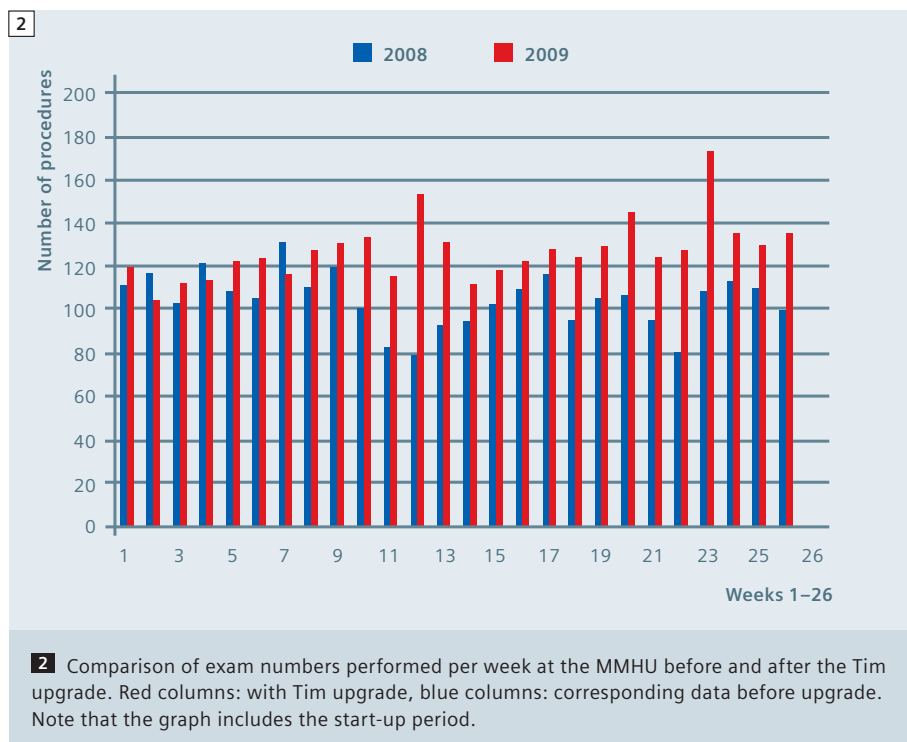
Installation:

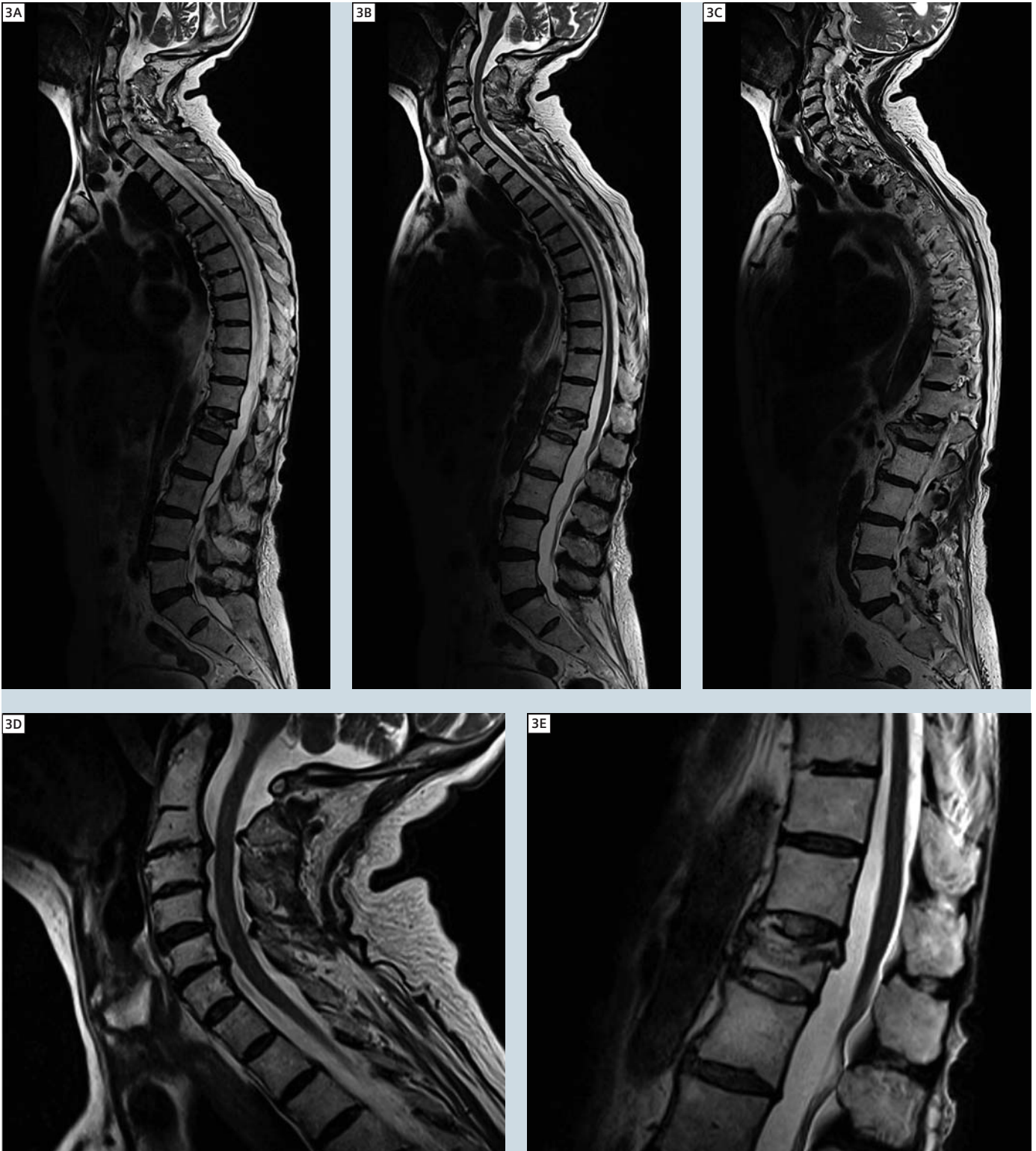- The old scanner was stripped to its bare magnet and new hardware in the form of new external casing and table top, a new RF system, new standard (and optional coils), a new computer system with new software were installed. A mobile MR provided coverage during installation.
- The entire upgrade process took 5 days longer than anticipated. We continued an inpatient and urgent outpatient service from the mobile unit. Engineers worked around the clock to sort out teething difficulties but it was worth the wait!

Technology:

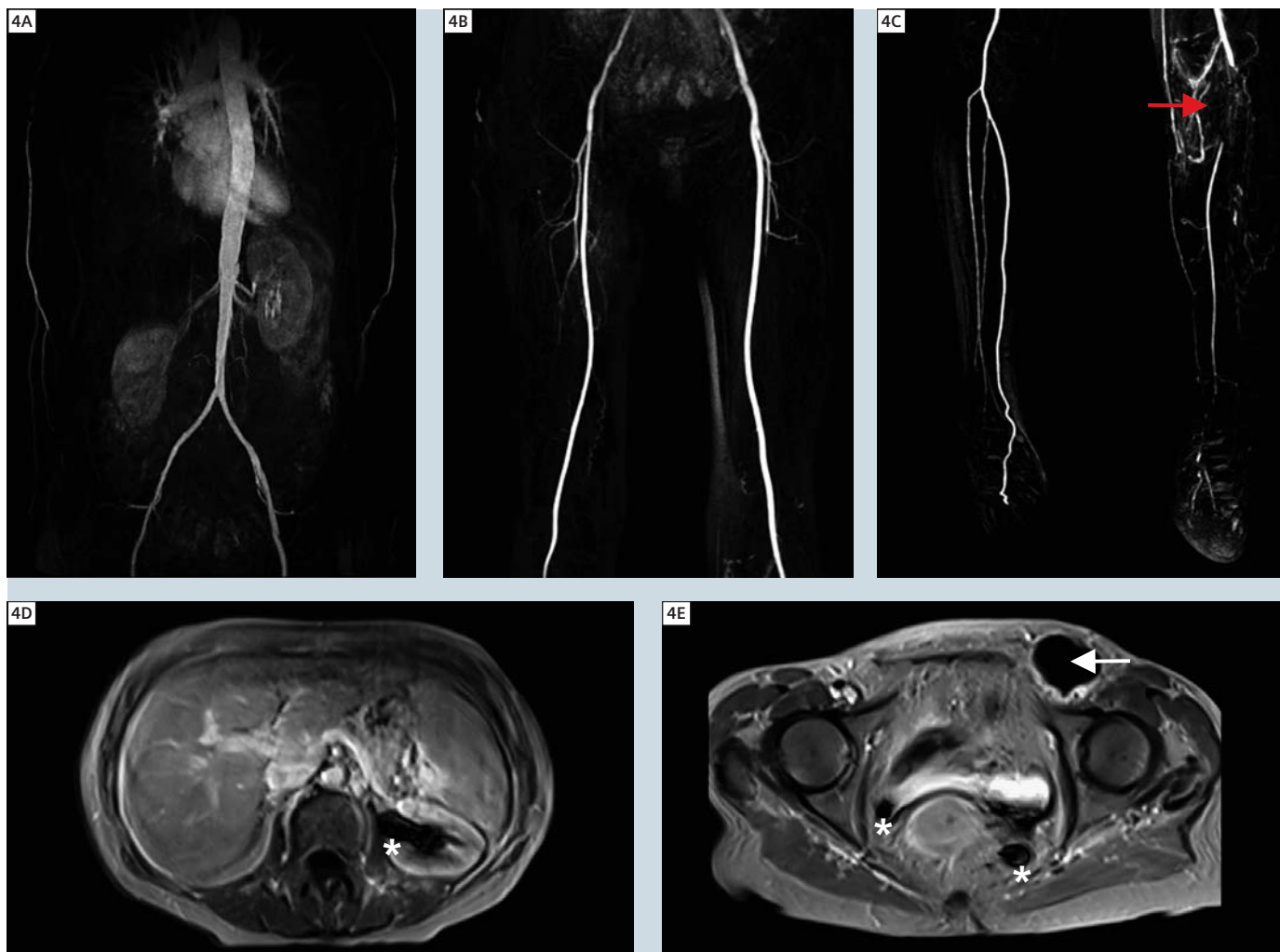
Several tailored upgrade packages were also purchased to the specific services of the adult population with congenital heart defects. We have now applied it to venous and tumor imaging. The *syngo*

BLADE sequence has become invaluable to us and is generally used in patients with movement disorders or patients who are slightly confused. It has greatly reduced the need to sedate these patient groups. The cardiac package included the PMU wireless physio control and vector ECG tracing which has greatly increased the efficiency of our cardiac clinic. The old ECG device was cumbersome and frequently needed replacing and a good trace proved difficult to attain in certain patients. We invested in the 8-channel knee coil and are impressed with the image quality attainable for MR arthrography, foot, ankle and wrist imaging with this device. Parallel imaging technology has greatly reduced scan times for many of our sequences. A new, sturdier head and neck coil replaced the old. Compared to the former flexible neck coil, a clear gain in signal-to-noise ratio (SNR) is obvious and also clinical advantages by application of parallel imaging e.g. for MR angiography of the supraaortic vessel are obvious. However, the old flexible neck coil is sometimes greatly missed, especially for our spinal trauma patients. Our





3 Example of a whole-spine exam. **3A–C** composed sagittal T2w TSE images, consisting of three stages (TR / TE = 4000 / 100 ms; slice thickness 3 mm). Note the slight scoliosis (best shown in **3C**). Magnified images do demonstrate multiple degenerative changes of the cervical spine with narrowing of the spinal canal (**3D**) and the compression fracture of the first lumbar spine without relevant stenoses of the canal (**3E**).



4 Multi-step MR angiography of a 55-year-old female patient with limited breath-hold capabilities. **4A–C** MIP based on the large-FOV MR angiography (TR / TE = 3.10 / 1.08 ms, FOV 328 x 500 mm, matrix 214 x 383, slice thickness 1.4 mm). Complete occlusion of the left popliteal artery is found (red arrow). Note also a seroma on the left inguinal side (white arrow) and susceptibility artifacts at the area of the ureters on both sides (marked by stars). **4D, E:** ce 2D FLASH.

image quality is compromised in these patients as the new neck coil will not fit over spinal immobilization devices and tracheostomy tubes.

Productivity:

Since the upgrade there has been a notable increase in throughput and productivity due to faster scanning and examination times. Over the same 6 month period one year prior to and after installation of the Tim upgrade there has been a 20%* increase in the number of procedures performed. Faster scan times amount to a significant increase of at least 4 proce-

dures per day or an average of at least 20 MR studies per working week.

Cost:

The approximate cost for our institution of outsourcing an MR scan in 2008 was € 220.00. Based on achieved additional throughput of 20 scans per week (Fig. 2) for an operational 50 weeks of the year the total savings will pay for the upgrade including VAT (value added tax) at 21% and our interest costs in 3 years. In summary the Tim upgrade has allowed us to achieve state of the art imaging on site on a cost neutral basis.

This was achieved by a commitment on the part of all staff to increase patient numbers without additional staff.

*Results may vary. Data on file.

Contact

Dr. John Murray, M.D.
Dept of Radiology
The Mater Misericordiae
University Hospital
Eccles Street
Dublin 7
Ireland
jmurray@mater.ie