

# FABS View of the Elbow for Visualization of Distal Biceps Tendon

Peter Cazares, RT (R) (CT) (MR)

MR Clinical Education Specialist, Siemens Healthcare, Iselin, NJ, USA

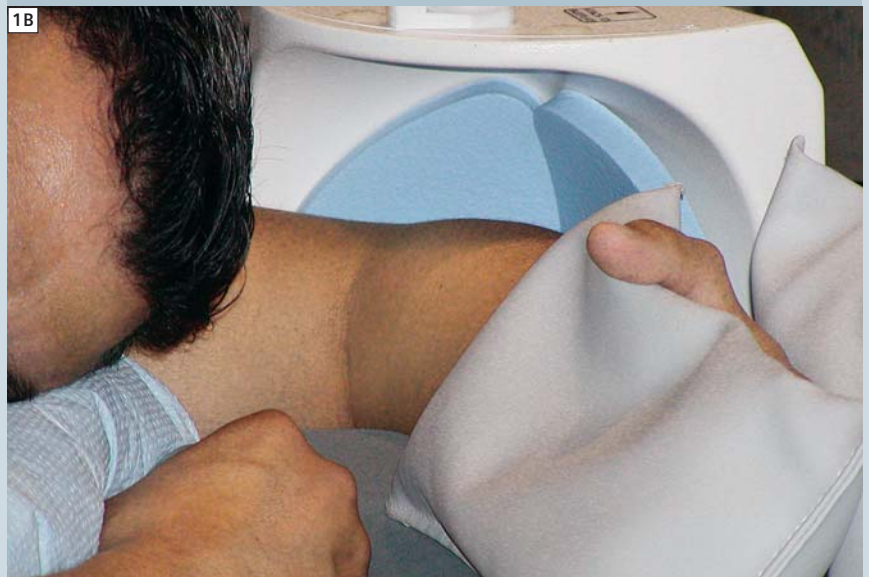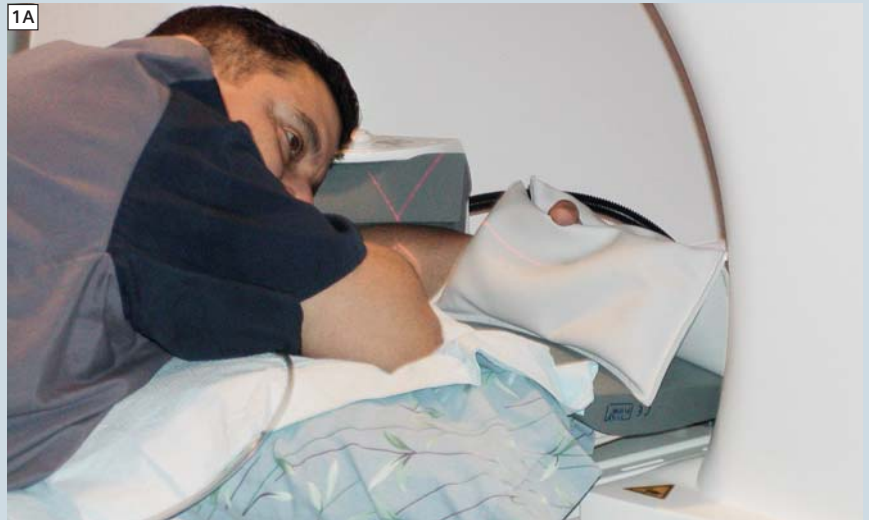## Introduction

Imaging of distal bicep tendon in MR can be somewhat difficult at times given the position of the elbow in relation to the general scanning environment. Common axial / coronal sequences demonstrate the tendon in an oblique projection that make it difficult to appreciate it in its entirety. By using the FABS (flexed elbow, **a**bducted shoulder, forearm supinated) technique, imaging of the distal biceps tendon can be acquired "in plane" with excellent visualization and comfortable patient positioning.

## Conclusion

Distal biceps tendon pathology will be greatly appreciated using this technique and can be incorporated with standard elbow imaging when this clinical referral is presented. Also greater success can be achieved with greater patient comfort using this technique and position.

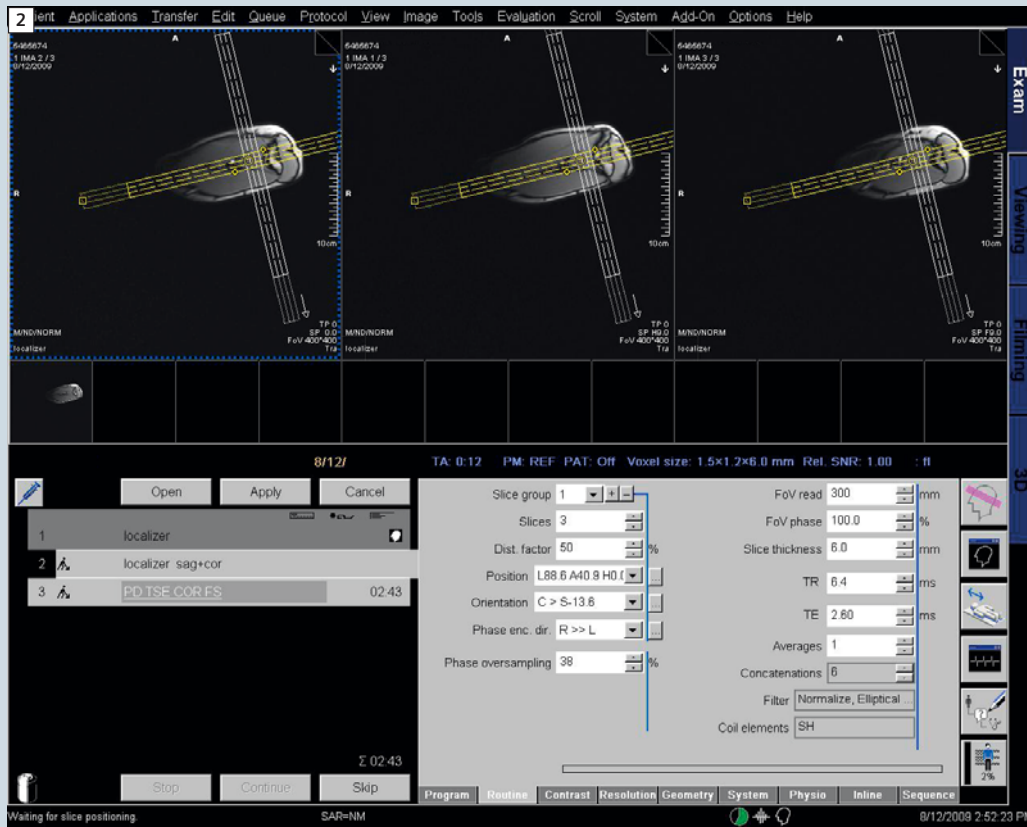
## Procedure



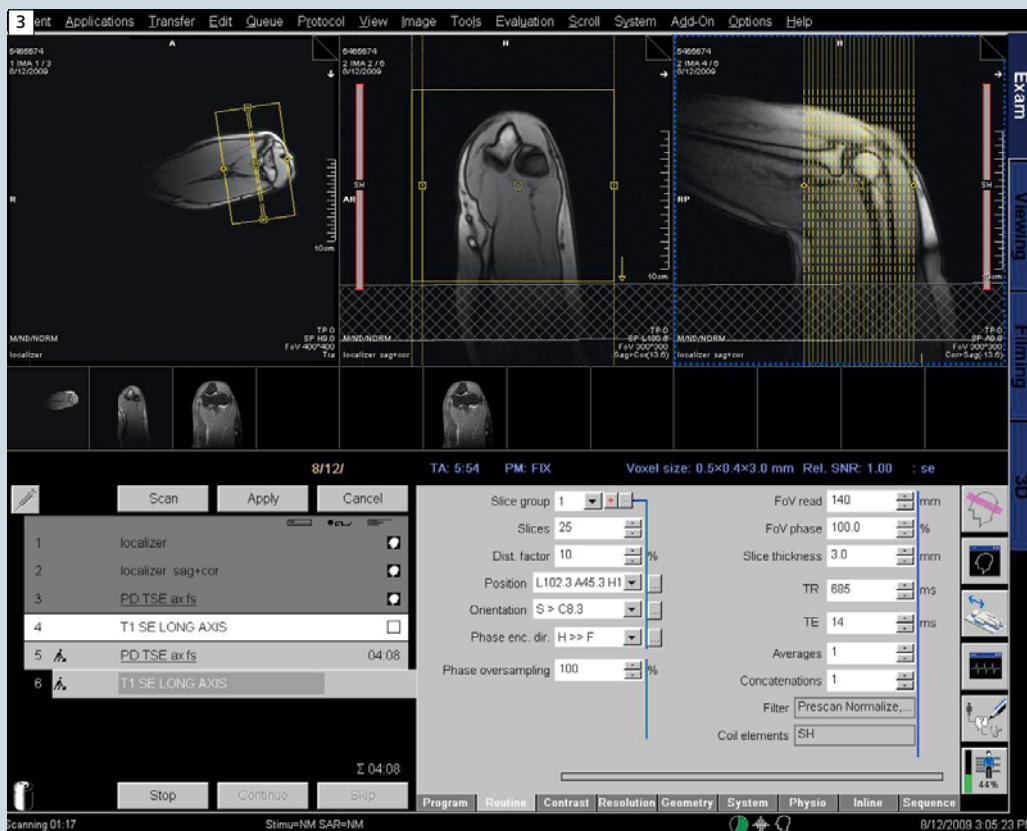
**1 Step 1:** We position the patient using our standard shoulder coil configuration. Have the patient lay on their stomach as comfortable as possible. Flex the elbow 90 degrees and place the elbow in the shoulder coil with the forearm and wrist supinated. Secure the forearm and wrist with either sandbags or a channeled positioning sponge to insure immobilization.

### Contact

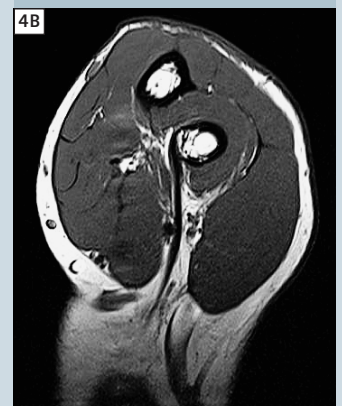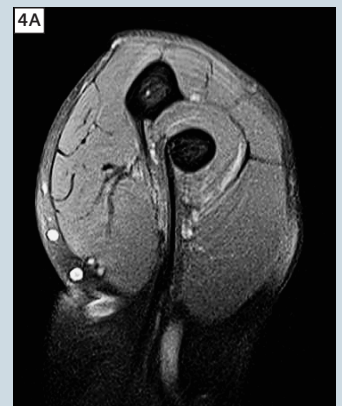Peter Cazares  
Siemens Healthcare USA, Inc.  
HQ Application Specialist – MR  
170 Wood Avenue South  
Iselin, NJ 08830  
USA  
peter.cazares@siemens.com



**2** Step 2: Landmark at the center of the coil and localize. Perform two additional localizers in long and short axis in relation to the elbow.



**3** Step 3: Select sequences so as to image the biceps tendon "in plane". T1-weighted Spin Echo (SE) no fatsat, PD TSE fatsat are one recommendation.



**4** As seen, the distal biceps tendon is presented "in plane" along with the insertion at the radial tuberosity.