

# Let's TWIST again: Temporal and Spatial High-Resolution 3D MR-Angiography of the Hand

Anton S. Quinsten<sup>1</sup>; Stefan Maderwald<sup>1,2</sup>; Katja Seng<sup>1</sup>; Birayet Uçan<sup>1</sup>; Harald H. Quick<sup>1,2</sup>

<sup>1</sup>Institute for Diagnostic and Interventional Radiology and Neuroradiology, Essen University Hospital, Essen, Germany

<sup>2</sup>Erwin L. Hahn Institute for Magnetic Resonance Imaging, University of Duisburg-Essen, Germany

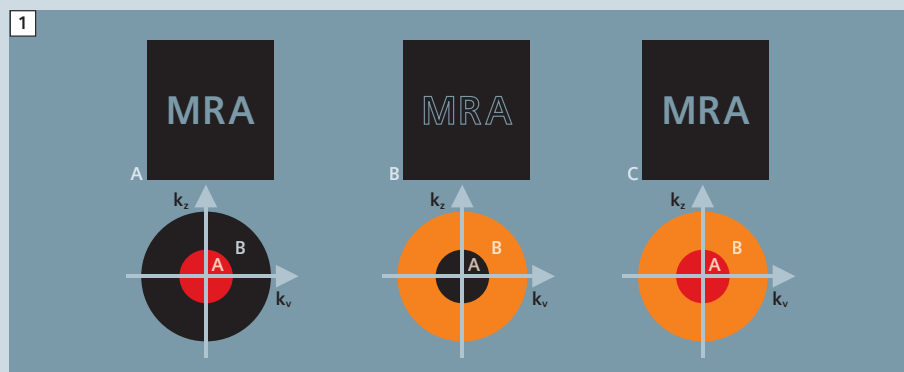
Compared to conventional contrast-enhanced MR angiography (MRA), which provides a spatial high-resolution three-dimensional (3D) MRA data set of the vascular target region, MRA with TWIST (time-resolved angiography with stochastic trajectories) with its high temporal resolution offers an additional dynamic component. It presents a broad range of advantages for all vascular diagnostic questions where blood flow dynamics play a role. For example, an angiographic 3D display with high temporal resolution is a prerequisite for evaluating arterio-venous malformation (AVM), as well as venous malformations (DVM) in the brain, aortic dissections or vascular shunts. Data acquisition with the *syngo* TWIST sequence creates a series of high-resolution 3D MRA data sets that together contain this dynamic in-

formation. Additionally, the acquisition of multiple measurements in rapid succession renders the aspect of contrast agent timing less critical. For the reasons indicated above, *syngo* TWIST examinations are gaining in clinical relevance. From a technical perspective, one challenge to this examination is the relatively high storage capacity required for data acquisition and subsequent reconstruction, whereby data reconstruction of all dynamic 3D MRA data sets requires several minutes. From a medical perspective, the challenge lies in the relatively large number of images to be acquired and diagnosed. For this reason, the data to be reconstructed (source images, subtractions, maximum intensity projections (MIP), etc.) should be clarified beforehand with the physician. In the following, we report on the use

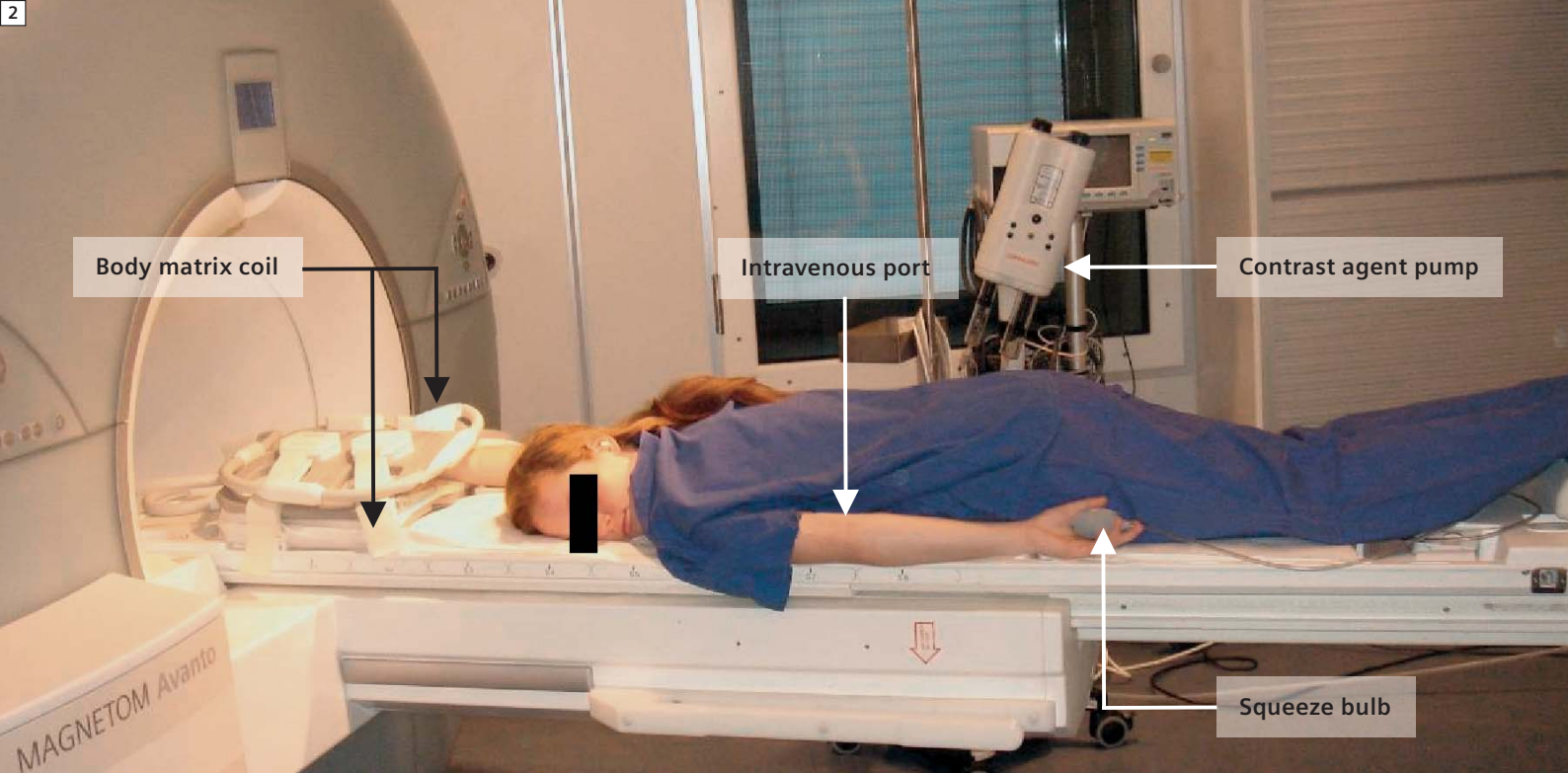
of time-resolved TWIST-MRA of the hand and present a possible examination sequence. We begin, however, by taking a brief look at the theory behind TWIST data acquisition.

## Theory of *syngo* TWIST data acquisition

Before an image can be reconstructed in MRT, the acquired data have to be stored in a specific order in a raw data matrix, the so-called k-space. Generally, the central k-space (Region A) contains the information that delivers image contrast after reconstruction. In contrast, the peripheral portion of the k-space (Region B) contains the information that delivers image details after reconstruction. Only both k-space regions together deliver a sharp, full-contrast image or a sharp, contrast-enhanced 3D MRA data set after reconstruction (Fig. 1). By varying the percentage sizes of Regions A and B, the examining physician can largely vary the contrast or resolution of a TWIST data set. During TWIST acquisition, the previously determined size of Region A is always filled completely. It is in this area that one expects the greatest changes in contrast due to the inflow of contrast agent. Region B is also completely covered in a single measurement, but it is sampled with a reduced sampling density. As a result, multiple passes through B are required to obtain the data from Region B with full density. However, missing points in k-space can be supplemented from previous or future measurements of Region B to calculate a complete 3D MRA data set at any time.



**1** Reconstruction of a 3D data record: (A) only the inner k-space (Region A, core) was reconstructed. Contrast is available, but the sharp structures/edges and detailed information are missing in the reconstructed image. (B) Only the outer k-space (Region B, mantle) was reconstructed. Sharp edges (high spatial frequencies) are visible, but contrast is missing from the reconstructed image. (C) The full k-space (Region A + Region B) was reconstructed. It takes the reconstruction of Regions A+B to produce a sharp, contrast-enhanced image.



2 Patient positioned on tabletop of a 1.5T Siemens MAGNETOM Avanto system.

## The most frequent clinical indications for TWIST MRA of the hand

There are numerous clinical indications for dynamic MR angiographic examinations. Examples include:

- General vascular pathologies
- Vascular malformations
- Hemangioma
- Arterio-venous (AV) fistulas
- Vascular insufficiency
- Raynaud syndrome
- Scleroderma
- Rheumatism
- Tumorous diseases
- Surgical planning e.g., to clarify if surgery is possible

## Patient preparation and positioning

As with all MRT examinations, the patient should first read the internal hospital questionnaire regarding possible contraindications, and then complete and sign a consent form for the examination. Based on this information, the radiologist meets with the patient to answer any questions and discuss possible risks associated with the examination, such as contrast agent side effects. A current creatinine and glomerular filtration rate

(GFR) value should be available for the patient. If it is not in the normal range or if the patient is intolerant to contrast agents, special precautionary measures are required, such as corresponding premedication or targeted hydration (oral or infusion) before and after contrast agent administration. After the patient puts on MR-suitable hospital clothing, an intravenous port is set up in the arm not being examined (at least 22 gauge). It now has to be ensured that the patient has removed all metal objects (e.g., glasses, watch, coins, etc.) before entering the examination room. These represent primarily a potential hazard, but could also interfere with the examination (metal artifacts) or be damaged. This entire procedure ensures that the patient is fully informed and agrees to the examination, and that all potential risks have been minimized, so that the MRT examination can now be performed safely. In the examination room, the patient receives hearing protection (for this examination, earplugs are preferable to headphones) and is placed in the prone position (Fig. 2). The arm to be examined is extended forward (the legendary "Superman pose") and "sandwiched" between two Body Matrix coils. The other

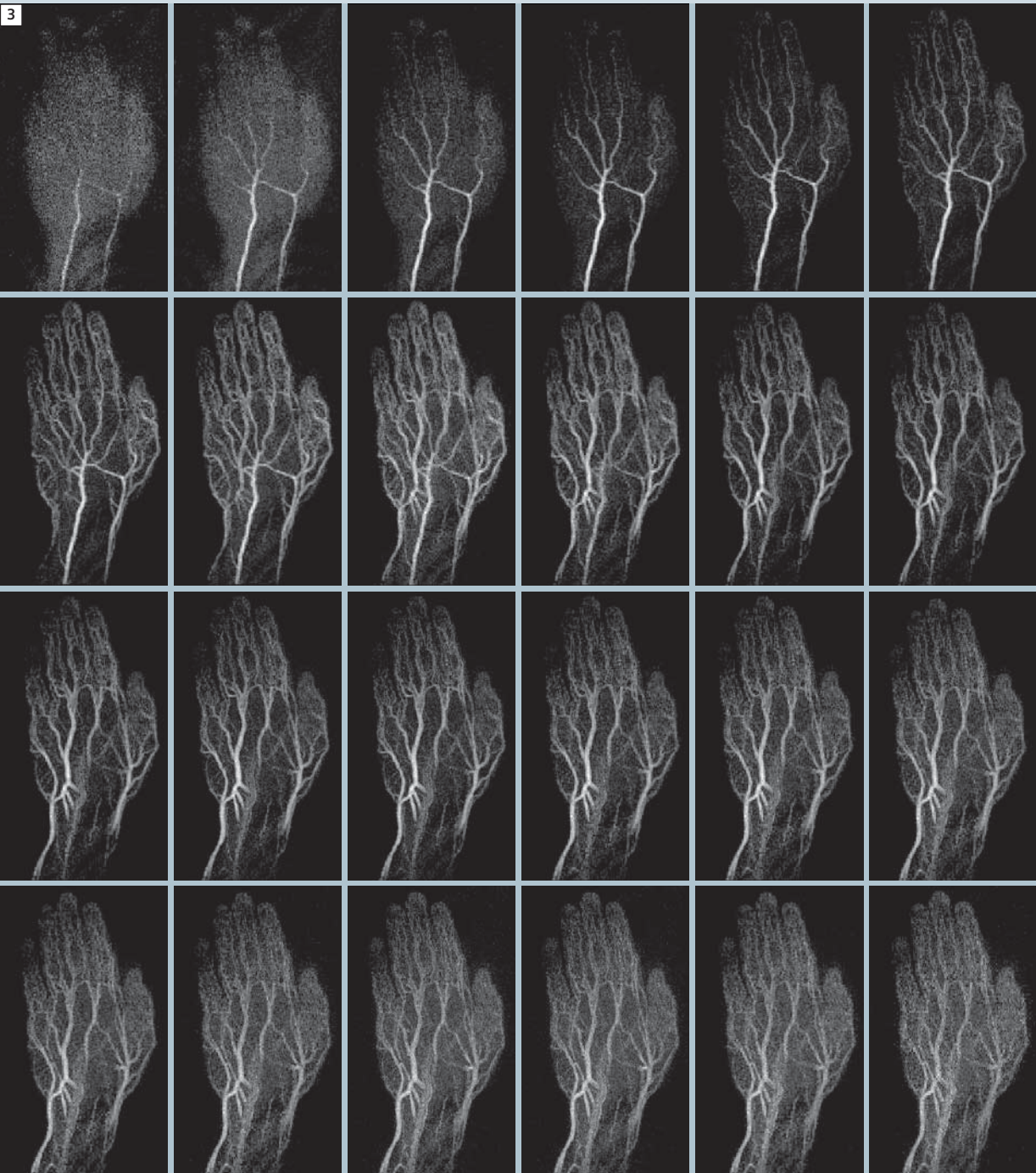
arm is positioned along the body pointed toward the back, and is equipped with the squeeze bulb. Using positioning cushions, sandbags, and if necessary vacuum cushions, a comfortable position is ensured for the patient, while his finger or hand to be examined is immobilized. It is necessary to ensure that the area to be examined is placed in the isocenter of the coil to the fullest extent possible, and remains as far as possible in an unbent position. Through this optimal positioning, smaller fields of view (FOVs) can be used (improving spatial resolution) for example, and fewer slices are necessary (increasing temporal resolution). The optimized position (extended finger, straight back of the hand) ensures the optimal diagnostic course of the vessels. From a technical view, these simple measures optimize temporal and spatial resolution. From a medical perspective, they optimize the examination results. Before the actual examination can begin, and while the contrast agent pump is being connected, the patient should be reminded again regarding motion artifacts and asked to lie still during the entire examination and to not move his fingers or hand.

### Performing the examination

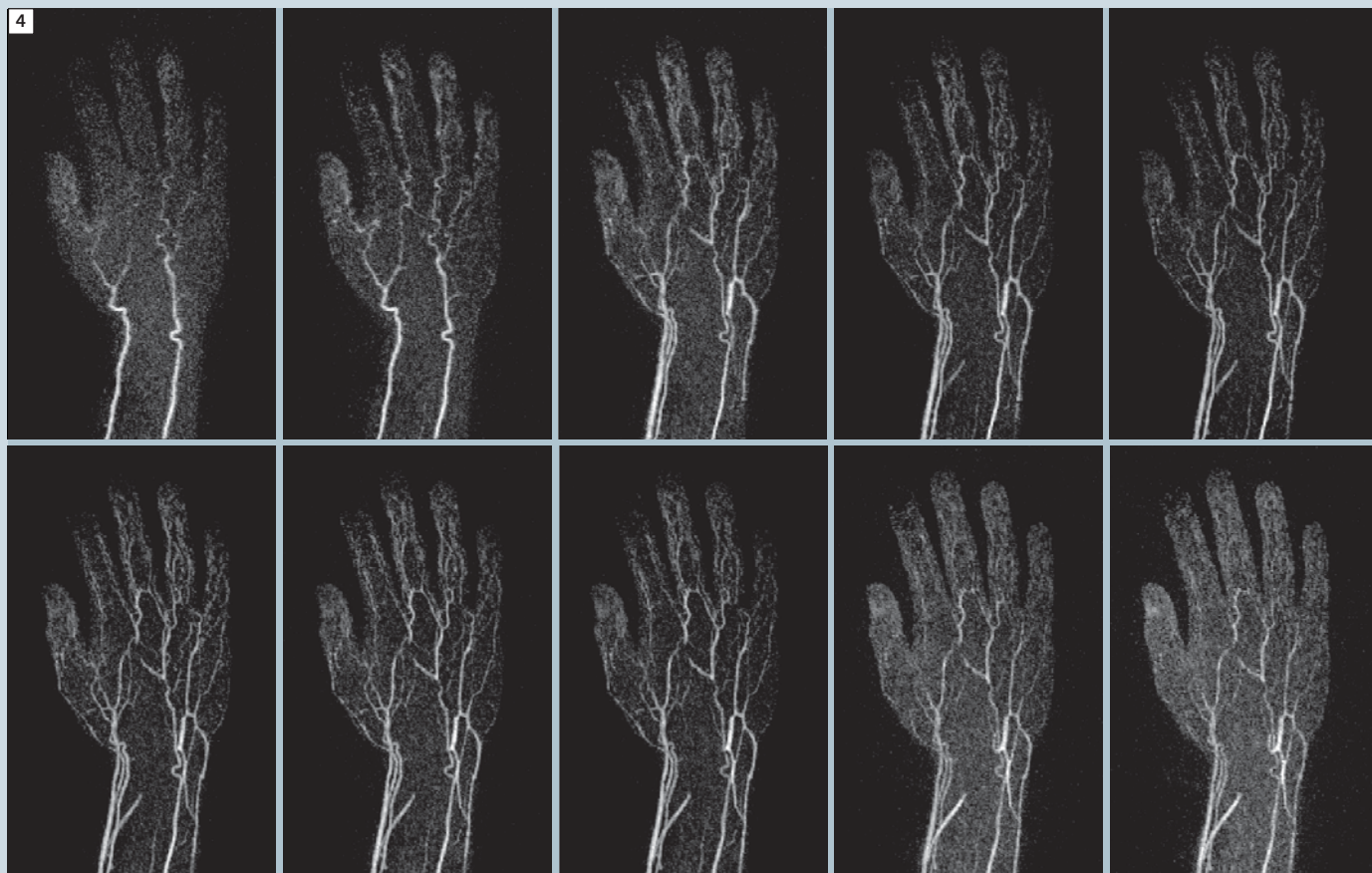
The complete *syngo* TWIST MRA examination of the hand generally takes less than 5 minutes (excluding patient positioning and data reconstruction). First, fast “three-plane localizers” are taken to localize the region of interest (ROI). Ide-

ally, the TWIST data should be acquired in coronal orientation. The *syngo* TWIST measurement is started simultaneously with the contrast agent injection. The TWIST sequence acquires 29 consecutive T1-weighted data sets where A = 20%

and B = 10%, as well as with GRAPPA (iPAT R = 2). The protocol parameters are: TR/TE = 2.92 ms / 1.2 ms, FA = 25°, FOV = 260 mm x 162.5 mm, slices = 36, bandwidth = 650 Hz/Px, with an acquisition matrix of 384 x 240 pixels. This



**3** *syngo* TWIST dynamic MRA of the left hand in a 25-year-old healthy volunteer with normal diagnostic findings. Non-interpolated coronal MIPs across the 28 3D subtraction data sets. The dynamic inflow of contrast agent in the arterial, venous, and late venous phases is easily discernible. The detailed spatial resolution enables display of the smallest arteries.



**4** syngo TWIST dynamic MRA of the right hand for a 47-year-old female patient with functionally incomplete deep and superficial palmar arch. It shows extremely sparse contrasting of the vessels in the thumb (D1) and index finger (D2). 10 of 28 acquired contrast phases are shown.

results in a non-interpolated spatial/temporal resolution of 0.7 mm/0.7 mm/0.7 mm/3.2 sec. These 29 measurements produce a total of 29 raw/source data sets, with 29 subtraction data sets and up to three MIP data sets (ax, cor, sag), which also offer the opportunity to temporally interpolate the dynamic data (Figs. 3 and 4). In total, more than 2000 individual images are reconstructed during this examination.

### Conclusion

The use of temporal and spatial high-resolution 3D TWIST MRA in angiographic diagnostics of the hand enables a spatial display of vascular pathology comparable to that of conventional static 3D MRA, while at the same time generating addi-

tional dynamic information. This information was previously available only through invasive digital subtraction angiography (DSA) or intravascular ultrasound.

### References

- 1 Brauck K, Maderwald S, Vogt FM, Zenge M, Barkhausen J, Herborn CU. Time-resolved contrast-enhanced magnetic resonance angiography of the hand with parallel imaging and view sharing: initial experience. *Eur Radiol.* 2007 Jan;17(1): 183–92.
- 2 Brauck K, Vogt FM, Maderwald S, Ladd SC, Kroeger K, Laub G, Kroeger R, Quick HH, Barkhausen J. Time-resolved MR-angiography (TWIST) of the hand in comparison to digital subtraction angiography (DSA). In *Proc. International Society for Magnetic Resonance in Medicine (ISMRM)*, 19–25 May 2007, Berlin, p. 2491.

### Contact

Anton S. Quinzen  
 Institute for Diagnostic und Inter-  
 ventional Radiology and Neuroradiology  
 University Hospital Essen  
 Hufelandstr. 55  
 D-45122 Essen  
 Germany  
[anton.quinzen@uni-due.de](mailto:anton.quinzen@uni-due.de)