

# Case Report: Non-Contrast Lower Limb MR Angiography Using NATIVE SPACE

Associate Professor Andrew Holden; Anna-Maria Lydon; Associate Professor Brett Cowan

Centre for Advanced MRI, Faculty of Medical and Health Sciences, University of Auckland, New Zealand

## Patient history

A 55-year-old male presented with right leg calf claudication with the onset of pain occurring after walking 50 meters. He had a normal femoral pulse but an absent popliteal pulse on the right and normal pulses on the left. The patient was imaged on a 1.5T Siemens MAGNETOM Avanto using the

8-channel, 16 element Peripheral Angio Matrix coil, combined with the Body and Spine Matrix coils. Standard contrast enhanced MR angiography was followed by the non-contrast NATIVE SPACE sequence at the femoro-popliteal station for comparison.

## Sequence details

The SPACE acquisition is a high spatial resolution 3D TSE sequence offering the use of non-selective refocusing pulses and, thus, short echo spacings. The NATIVE SPACE technique relies on the inherent difference in signal between fast flowing blood during systole and

the slower flowing blood during diastole to generate contrast. Two data sets were acquired after determining the trigger times from a "NATIVE scout mode" acquired from an artery within the imaging volume and subtracted. ECG cardiac gating was used.

## Imaging findings

Contrast-enhanced MR angiography (Fig. 1) demonstrated an 8 cm long stenotic lesion in the distal right superficial femoral artery with the above knee popliteal artery being reconstituted by large profunda femoral artery collaterals. NATIVE SPACE MR angiography (Fig. 2) demonstrated an excellent correlation with the contrast-enhanced study in terms of lesion severity, length and col-

lateral anatomy. Digital subtraction angiography (Fig. 3) confirmed the contrast and non-contrast MR angiographic findings.

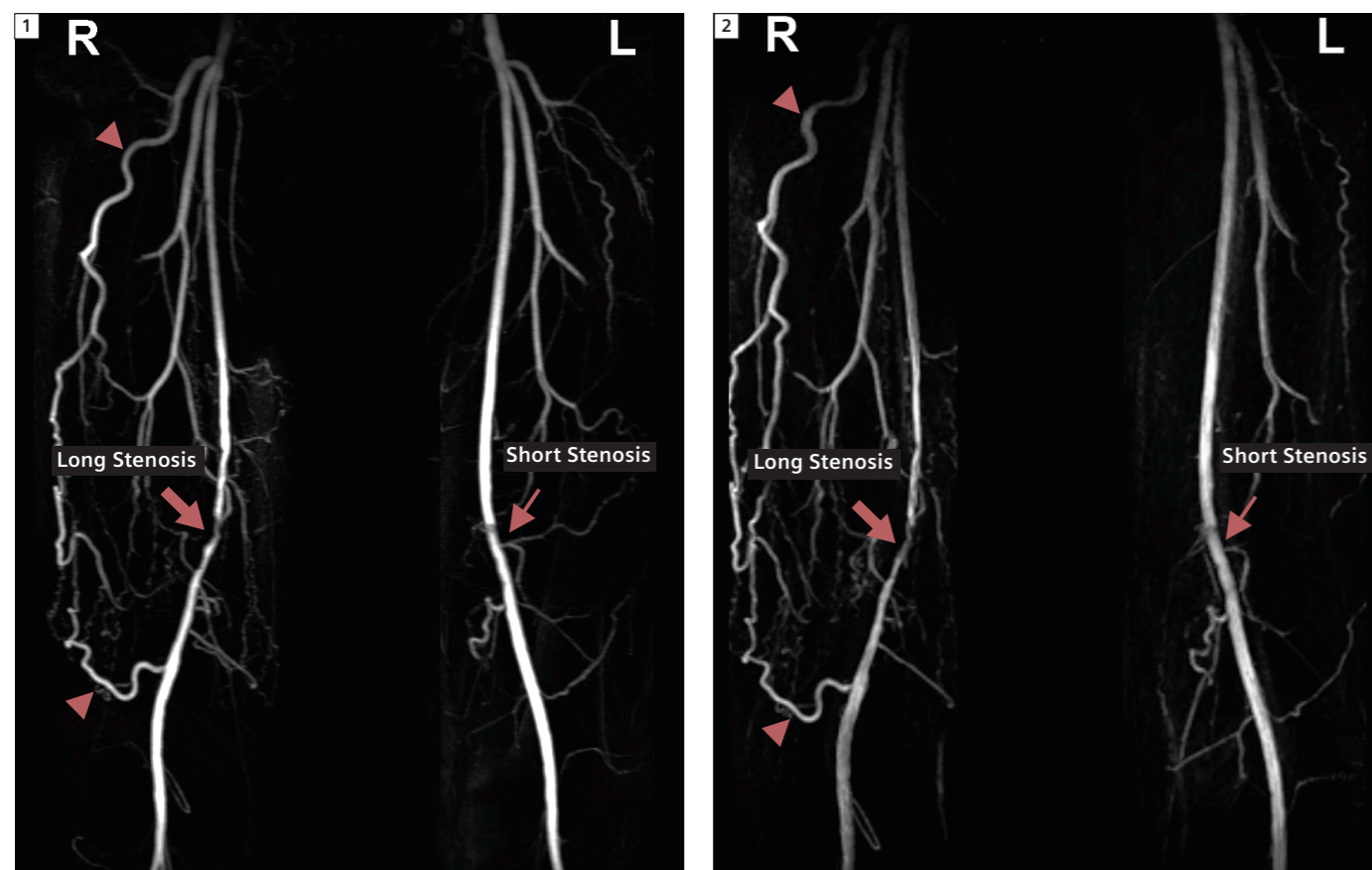
## Discussion

With recent concerns regarding the risk of nephrogenic sclerosing fibrosis (NSF) with gadolinium based contrast agents in renally impaired patients, there has been considerable interest in the development of MR techniques that do not require gadolinium chelates. NATIVE SPACE has considerable advantages over time of flight MR angiography. The sequence is acquired along the long axis of the vessel rather than perpendicular to the flow direction, resulting in extensive z-axis coverage without the flow

saturation. NATIVE SPACE can be used as single or multi-station study and appears to be robust also if contrast has already been given, suggesting a role for 'recovery' if a contrast study is unsuccessful.

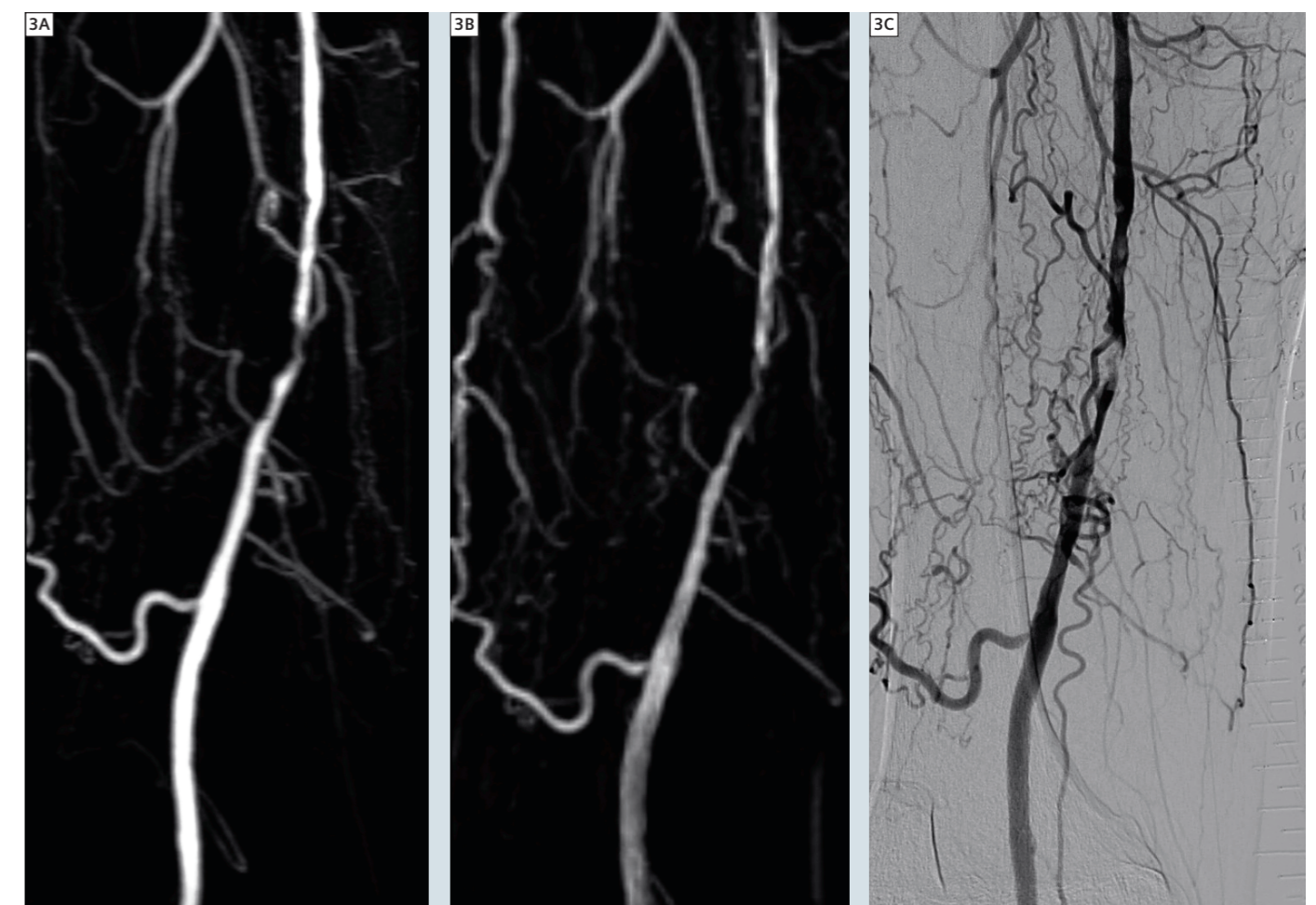
### Contact

Associate Professor  
Andrew Holden  
Director of Interventional Radiology  
Auckland City Hospital  
2 Park Road  
Grafton  
Auckland 1023  
New Zealand  
AndrewH@adhb.govt.nz



**1** Contrast-enhanced MRA of the femoro-popliteal station demonstrating an 8 cm long stenotic lesion in the distal right superficial femoral artery (thick arrow) with the above knee popliteal artery being reconstituted by large profunda femoral artery collaterals (arrowhead). There is also a mild stenosis in the left superficial femoral artery (thin arrow) at a similar level.

**2** NATIVE SPACE MRA demonstrates excellent correlation with the contrast-enhanced study in terms of right superficial femoral artery lesion severity, length (thick arrow) and collateral anatomy (arrowhead). The mid left superficial femoral artery stenosis is again demonstrated (thin arrow).



**3** Magnified view of the distal right superficial femoral artery showing excellent correlation between the contrast-enhanced MRA (A), NATIVE SPACE MRA (B) and digital subtraction angiography (C).