

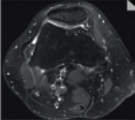
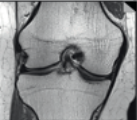

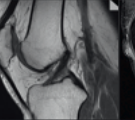
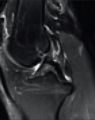
NOTE

This protocol was provided by
**Prof. Michael Recht, NYU
 School of Medicine**, Dep. of
 Radiology, NY, USA, on behalf of
 the MSK Advisory Board


contrast:
 sequence type:
 slice orientation:

acquisition time [min:s]:
 resolution [mm³]:
 matrix [Px2]:
 bandwidth (Hz/Px):
 turbo factor:
 TR [ms]:
 TE [ms]:
 TI [ms]:
 field of view [mm]:

2D SCAN

PD TSE transversal	PD TSE coronal	PD TSE coronal	PD TSE sagittal	T2 TSE sagittal
				
04:31	03:35	03:54	03:35	03:51
0.5x0.4x3.0	0.3x0.3x2.5	0.4x0.3x3.0	0.4x0.3x2.5	0.5x0.4x3.0
384x288	448x403	448x381	512x384	384x288
181	180	180	257	181
15	4	5	5	15
5380	2630	3750	3000	5590
50	38	35	20	60
140	140	140	140	140

3D SCAN

NOT YET AVAILABLE


clinical requests

general
injury ligaments
 osseous
 minisci
 quadriceps tendon
degenerative pain cartilage

total scan time [min:s]

2D scan → 19:26
 15:51
 15:51
 15:32
 15:51
 15:32

pd_fs_tra	pd_cor	pd_fs_cor	pd_sag	t2_fs_sag
pd_fs_tra		pd_fs_cor	pd_sag	t2_fs_sag
pd_fs_tra		pd_fs_cor	pd_sag	t2_fs_sag
pd_fs_tra	pd_cor		pd_sag	t2_fs_sag
pd_fs_tra		pd_fs_cor	pd_sag	t2_fs_sag
pd_fs_tra	pd_cor		pd_sag	t2_fs_sag

MAGNETOM Verio Knee Protocol

www.siemens.com/magnetom-world

SIEMENS