



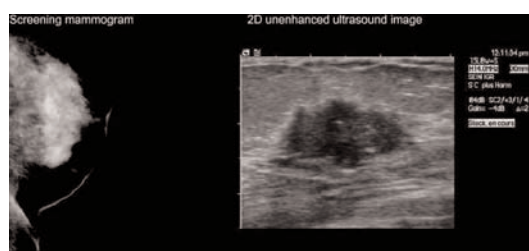Case Study

Contrast Enhanced Ultrasound in Breast Cancer Detection and Characterization

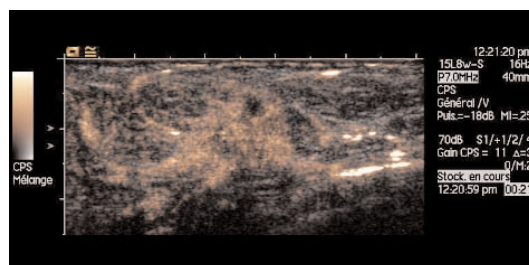
Patient History

A screening mammogram on a 66-year-old female patient with no family history of breast cancer demonstrated an architectural distortion and dense micro-calcifications at the inferior right breast. An initial ultrasound confirmed a 19-mm, irregular, hypoechoic and hyper vascular nodule in that breast. A contrast enhanced ultrasound (CEUS) was ordered to help stage and characterize the cancer. Contrast enhancement can improve detection of angiogenesis by overcoming visualization difficulties created by poor blood vessel density in the periphery of breast-cancer lesions.

Image Findings



The screening mammogram detects architectural distortion and micro-calcifications. 2D ultrasound confirms an irregular, hypoechoic and hyper vascular nodule.



Contrast enhanced ultrasound demonstrates an irregular nodule with spiculated enhanced areas, indicative of malignancy.

C. Balleyguier M.D.

Institute Gustave Roussy, France

www.siemens.com/ultrasound

SIEMENS
medical

Clinical Outcome

Pathology studies on a fine-needle aspiration indicated adenocarcinoma. The patient had a lumpectomy, followed by chemotherapy, radiation and hormone therapy. Early detection, plus superior characterization methods like CEUS, can help improve the probability of recovery.

Ultrasound Solution

The study was enhanced by employing Cadence™ contrast pulse sequencing technology (CPS). CPS improves sensitivity at high ultrasound frequencies (>7 MHz needed for breast imaging) by overcoming the challenges associated with the native resonant frequencies of the contrast agents (1.5 MHz – 7 MHz). The technology provides excellent special resolution; mix and live dual modes increase confidence when evaluating breast lesions for angiogenesis. Auto-tracking contrast quantification, performed on the *syngo*® US Workplace, improves online and offline

evaluation accuracy. CEUS in breast exams can be considered for same indications as a breast MRI, including characterization, BIRADS (Breast Imaging Reporting and Data System) coding, staging, and tracking of treatment response, recurrence and fibrosis. No ionizing radiation is involved, and patients tolerate the contrast agents well.*

syngo is a registered trademark and Cadence is a trademark of Siemens AG.

** At the time of publication, the US Food and Drug Administration cleared ultrasound contrast agents only for use in LVD. Check the current regulation for the country in which you are using the system for contrast agent clearance.*

Headquarters

Siemens Medical Solutions USA
51 Valley Stream Parkway
Malvern, PA 19355-1406 USA
Telephone: +1-888-826-9702
www.usa.siemens.com/medical

Europe: +49 9131 84-0
Asia Pacific: +65 6341 0990
Latin America: +1 786-845-0697

USA

Siemens Medical Solutions USA, Inc.
Ultrasound Division
1230 Shorebird Way
P.O. Box 7393
Mountain View, CA 94039-7393 USA
Telephone: +1-888-826-9702