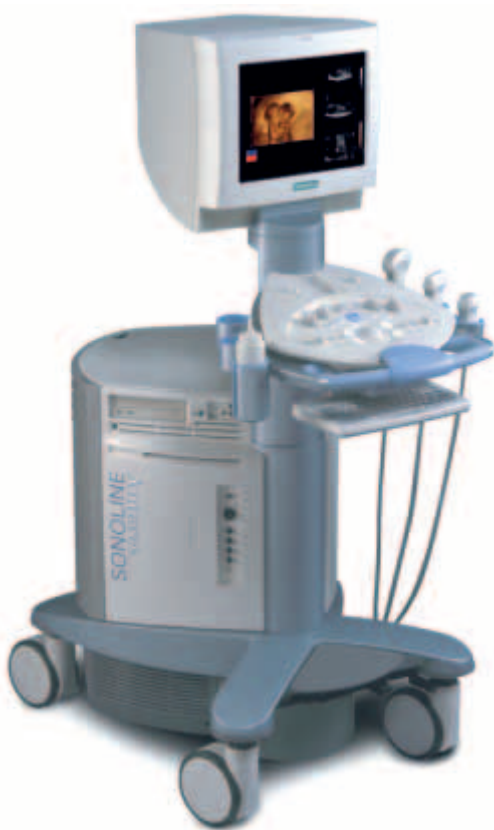

First Trimester Diagnosis of Conjoined Twins Using 4D Ultrasound: A Case Report

Conjoined twinning is a rather rare occurrence which, in the past, was not always detected at an early stage of pregnancy. 3D and 4D ultrasound is now taking first-trimester imaging to a new level.

By Frank J. Craparo, MD

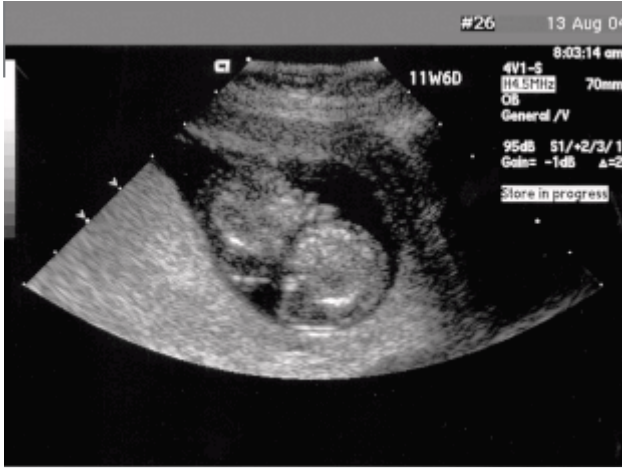

Conjoined twinning is a rare and often lethal complication of monozygotic twins, which happens when the zygote of identical twins fails to completely separate. The incidence of conjoined twins has been reported to range from 1/12,000 to 1/200,000, with approximately half being still born. The overall survival rate for conjoined twins is between 5% and 25%, and conjoined twins are more likely to be female (70%-75%).

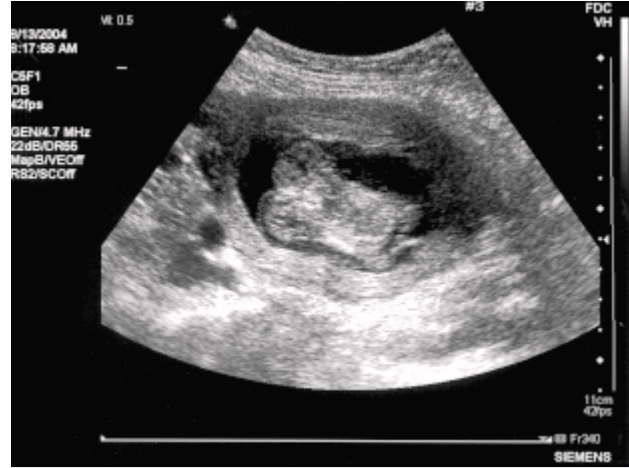The utilization of both two-dimensional (2D) ultrasound and MRI in the prenatal diagnosis of conjoined twins has been reported, and recently, three-dimensional (3D) ultrasound has been reported in the diagnosis of a set of conjoined twins at 13 weeks gestation. The following case report describes the use of real-time 3D, or four-dimensional (4D) ultrasound in the first trimester diagnosis of thoracopagus twins – the most common form of conjoined twins (about 35%), which is the anterior union of the upper half of the trunk and involves sharing the heart.

Case

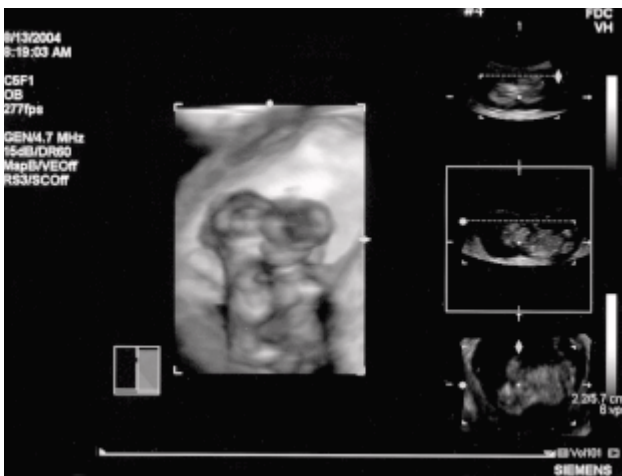
The patient is a 36-year-old female, who presented at 11 weeks, six days gestation for a first-trimester ultrasound and nuchal translucency measurement. The ultrasound examination was performed using an ACUSON Sequoia™ ultrasound system. A monoamniotic twin gestation was identified, and both twins were noted to have an increased nuchal translucency, with measurements of 5.9 mm and 4.9 mm for twins A and B respectively (Image 1). Additionally, the twins appeared to be fused in the area of the chests (Image 2).



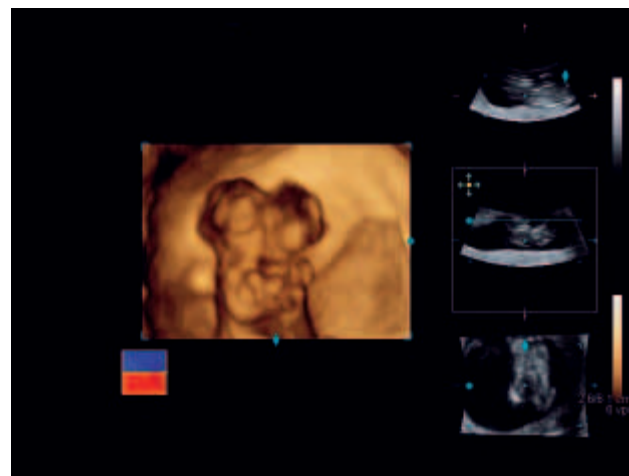
[1] 11.6 week transverse view monoamniotic twin, with increased nuchal translucency.



[2] 2D ultrasound image suggesting conjoined twins.



[3] 4D image of conjoined twins at 11.6 weeks gestation.



[4] 4D color image demonstrating thoracopagus, conjoined twins.

The findings were discussed with the patient and her partner. Additional evaluation was then performed using 2D and the new fourSight™ 4D ultrasound imaging technology on ACUSON Antares™ ultrasound system. This evaluation was used to further delineate the anatomic findings. The fourSight 4D imaging clearly demonstrated the presence of thoracopagus twinning (Image 3), and color mapping suggested that there was a single vascular system within the common chest (Images 3 and 4).

Discussion

The use of either prenatal ultrasound or MRI has been reported in the diagnosis of conjoined twins. The use of 3D ultrasound has previously been reported in both second, and third trimester diagnosis of conjoined twins. However, this case describes the diagnosis of conjoined twins in the first trimester using real-time 3D ultrasound. The usefulness of this modality is twofold. First, by using 2D imaging, the abnormal twinning was identified, and second, the use of real-time 3D ultrasound imaging further enhanced the defect, clearly demonstrating thoracopagus twins. Perhaps more importantly, the use of this modality provided further clarity of the defect for the parents.

Two-dimensional imaging of various fetal abnormalities may be readily identified and understood by trained sonographers/sonologists, however, often these diagnoses are not as apparent to the patient. Although we provide a verbal description of the abnormality for the patient, visual recognition clearly is beneficial in her understanding. With the patient's improved understanding of the findings, she can better appreciate the significance of the abnormality and its associated prognosis.

Future Outlook

This case provides another example of the increasing role and importance of real-time 3D imaging in prenatal diagnoses. The use of this modality provided enhanced imaging of the defect, and although the couple understood the concept of conjoined twins and stated that they recognized and understood the 2D ultrasound images, the application of real-time 3D imaging provided dramatic images, which were understandable to all. The importance of real-time 3D continues to expand and evolve with increasing experience in prenatal diagnosis.

Author: Frank J. Craparo is the chief of the Division of Maternal/Fetal Medicine and Genetics at Abington Memorial Hospital in Abington, Pennsylvania.