

## Fetal Skeletal Rendering

Roe Lazebnik, M.D., Ph.D.  
Senior Director of Product Management and Medical Affairs  
Siemens Healthcare, Ultrasound  
Mountain View, CA USA

Gareth Funka-Lea, Ph.D.  
Program Manager  
Siemens Corporate Research  
Princeton, NJ USA

Answers for life.

**SIEMENS**

# Fetal Skeletal Rendering

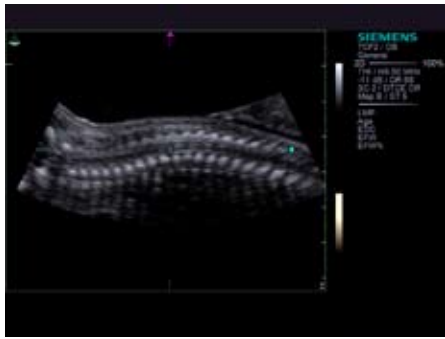


Figure 1a: Sagittal

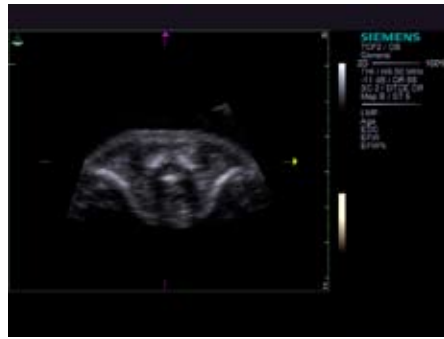


Figure 1b: Axial

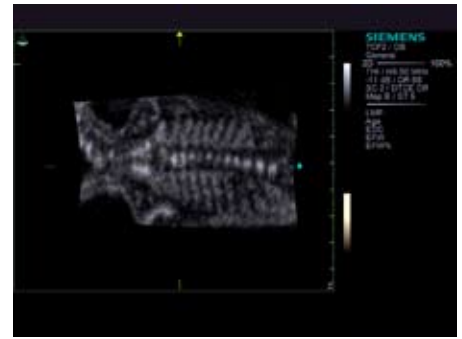


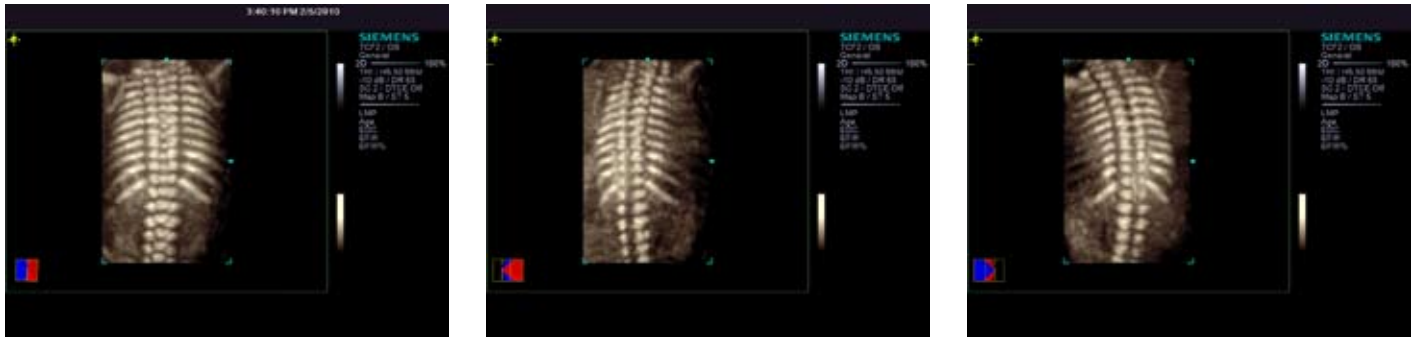Figure 1c: Coronal

Figure 1: Sagittal (a), axial (b), and coronal (c) MPR views of the normal fetal vertebral column.

Skeletal dysplasias are a heterogeneous group of conditions associated with abnormalities of the skeleton. These include abnormalities of bone shape, size, and density that manifest as abnormalities of the limbs, chest, or skull. The prevalence of skeletal dysplasias (excluding limb amputations) is estimated at 2.4/10,000 births and the overall prevalence among perinatal deaths is 9.1/1000. If suspected during a routine obstetrical ultrasound examination after a shortened bone or abnormal skeletal finding is observed, then a more detailed ultrasound-based survey is recommended.<sup>1</sup>

Currently, fetal skeletal visualization is predominately performed using 2D ultrasound but many studies have established the utility of a volumetric (3D) based approach. Compared with 2D imaging, a volumetric approach enables the clinician to more intuitively visualize skeletal structures as well as relationships between adjacent structures.<sup>2</sup> In addition, multi-planar reformatted (MPR) images are easily generated throughout the volume at arbitrary orientations as shown in Figure 1.

Using sonographic imaging, there is typically a significant echogenicity difference between fetal bone and soft tissue. Specifically, bone is hyperechoic relative to surrounding soft tissue. Due to this high contrast difference, the most common volumetric rendering method for visualizing bony structures is maximum intensity projection (MaxIP) as shown in Figure 2. This technique displays a sub-volume of tissue as a 2D image by only displaying the most intense



**Figure 2:** MaxIP views of the same fetal vertebral column. Multiple views of a given structure are possible by rotating the visualized sub-volume

(echogenic) voxel value encountered along projected paths perpendicular to the image plane. Thus, an echogenic bony structure contained within the sub-volume will be visualized on the resulting image even if surrounded by soft tissue. The most significant advantage of this approach is the relatively easy visualization of bony structures without manually segmenting them from surrounding tissues. However, there are several parameters required for effective MaxIP-based visualization, particularly sub-volume orientation and thickness.

There are limitations to MaxIP-based visualization. First, adjacent bony structures contained within a given sub-volume and along the same projected path cannot be differentiated. Thus, there is a tradeoff between contrast and spatial resolution, which can be manipulated using rendering tools. Second, apparent foreshortening of structures occurs if they are not parallel to the image plane. In addition, there are no visual cues when

this occurs and thus the user must often examine a given structure using multiple orientations to gauge its true shape. Third, true volume-based measurements including distances are not possible as resulting images are 2D.

### Technology Overview

Skeletal Rendering is a novel method for visualizing the fetal skeleton using volumetric ultrasound data. Visualization of the data is performed using a true volumetric technique and thus the user may intuitively manipulate the skeleton in three dimensions. The method relies on the relative hyperechogenicity of the fetal skeleton relative to surrounding structures, the spatial relationship between anatomically continuous skeletal structures, and assumptions of maximum and minimum sizes of skeletal elements. Using these assumptions, the fetal skeleton is automatically segmented from the surrounding soft tissues and the resulting data is rendered using a customized variant of a volume

rendering technique termed Amnioscopic Rendering. Other rendering methods including Opacity and Gradient Light may also be utilized to visualize the data.

In order to enhance the fetal skeleton within a sonographic volume, every location within the volume must be classified as to whether it is more likely to contain skeleton or something other than skeleton. Then those locations that do not contain skeleton have their intensity value decreased relative to those locations that contain skeleton. Several echogenicity and morphological characteristics, both local and regional, are considered in classifying each voxel as either "skeleton" or "non-skeleton". Calcified bone is bright (hyperechoic) and if one location is bone then nearby locations with bright intensities are also likely to be bone. In addition, the skeleton has a distinct morphology. It forms continuous elongated structures such as ribs and limb bones, knobs such as the head of the femur, and curved




Figure 3a: MaxIP-based Rendering

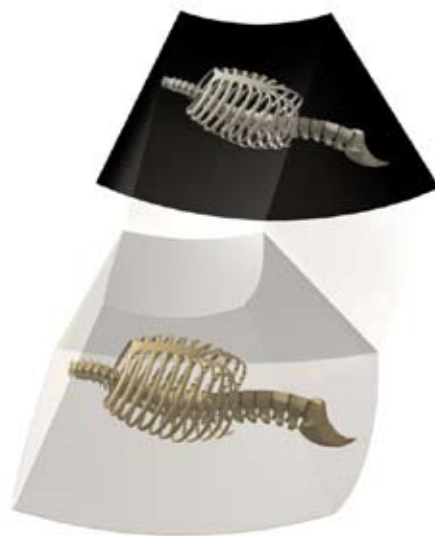


Figure 3b: Skeletal Rendering

**Figure 3:** A MaxIP-based image is a 2D projection (a) that depicts only the most echogenic voxel value for each column within the volume limiting spatial resolution. In contrast, Skeletal Rendering (b) facilitates true volumetric visualization of the imaged anatomy.

plates such as the skull or pelvis. In contrast, other imaging features may also be echogenic, including speckle or noise, but do not form continuous structures and are thus classified as non-skeleton.

### Technology Advantages

There are several advantages to the described method compared with conventional 2D imaging or MaxIP visualization. First, adjacent bony structures may be differentiated by simply rotating the volume to visualize their spatial relationship. Second, spatial resolution is fixed by the volume acquisition method, not its processing. Third, the method is highly automated. While there is opportunity for the user to vary parameters as to control the described algorithm's performance, many cases are feasible without user interaction using a default set of parameters. Fourth, the apparent foreshortening of structures not parallel to the image plane that happens with

MaxIP does not occur. Finally, true volume-based measurements including distances are possible as resulting images accurately depict 3D relationships. Overall, compared with MaxIP visualization, Skeletal Rendering enables a more intuitive and true volumetric visualization of anatomical and pathological structures as shown in Figure 3.

### Conclusions

Skeletal Rendering is a novel method for rapid, highly automated, and intuitive visualization of anatomical or pathological structures of the fetal skeleton using volume ultrasound. In addition, the method is highly versatile, allowing for various levels of soft-tissue subtraction, arbitrary viewing angle, and a user-movable light source. Compared to conventional 2D grayscale imaging as well as MaxIP images, 3D visualization may enable more effective communication among physicians as well as physician and patient.

### References

1. Camera G, Mastroiacovo P. Birth prevalence of skeletal dysplasias in the Italian Multicentric Monitoring System for Birth Defects. *Prog Clin Biol Res.* 1982;104:441-9.
2. Lazebnik N., Bornstein E., Timor-Tritsch I.E. The Utility of Volume Sonography for the Detection of Fetal Spine Abnormalities. In: Lazebnik N. Lazebnik R.S., ed. *Advanced Obstetrical Ultrasound – Fetal Brain, Spine, and Limb Abnormalities.*; 2008:529.

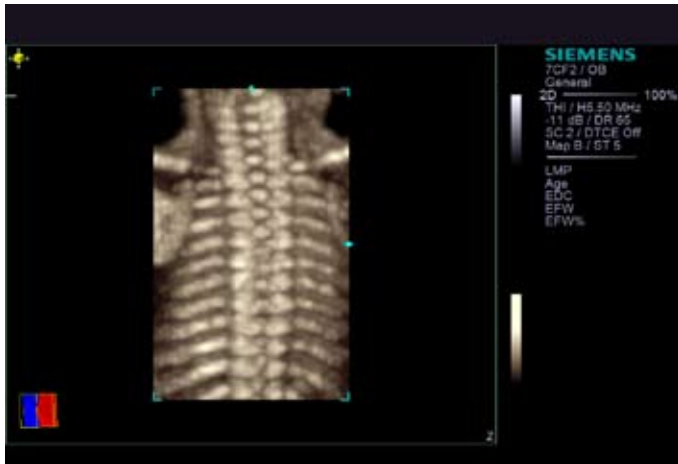

Figure 4a: MaxIP-based

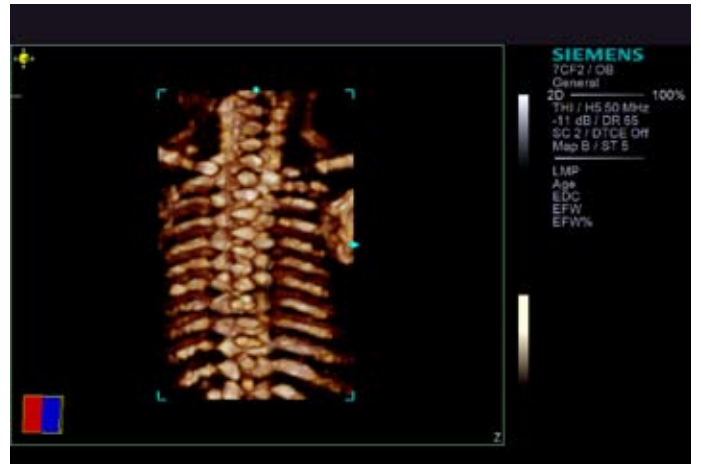


Figure 4b: Skeletal Rendering

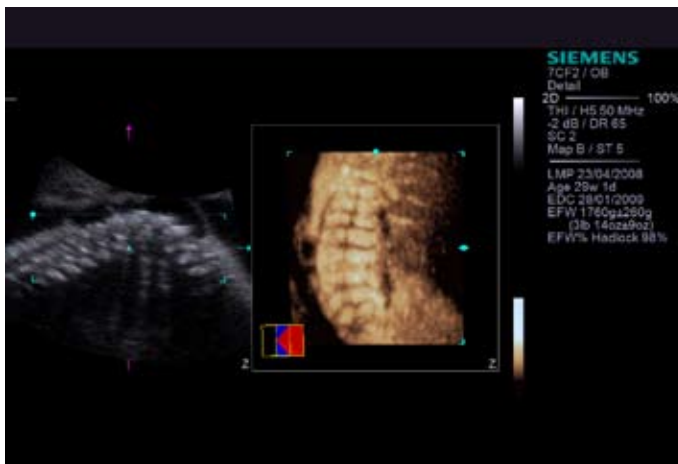


Figure 5a: MaxIP-based

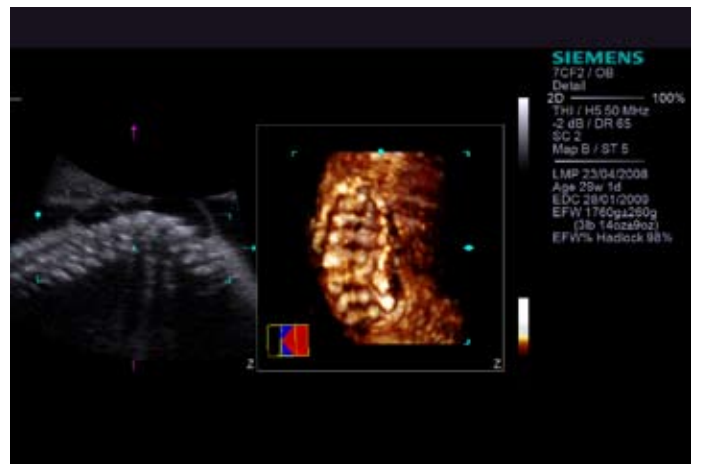


Figure 5b: Skeletal Rendering

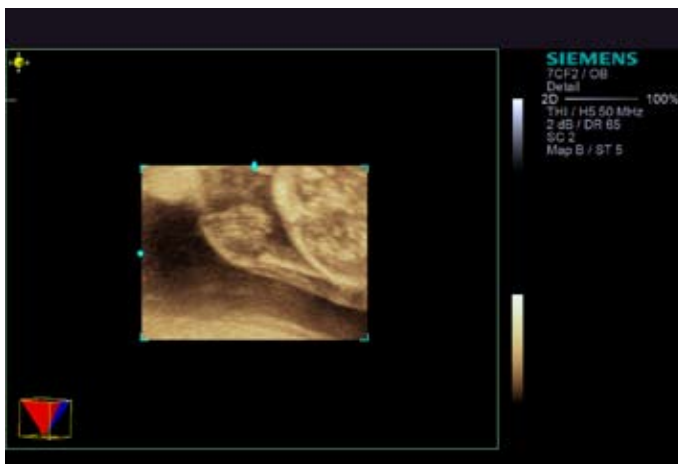


Figure 6a: MaxIP-based

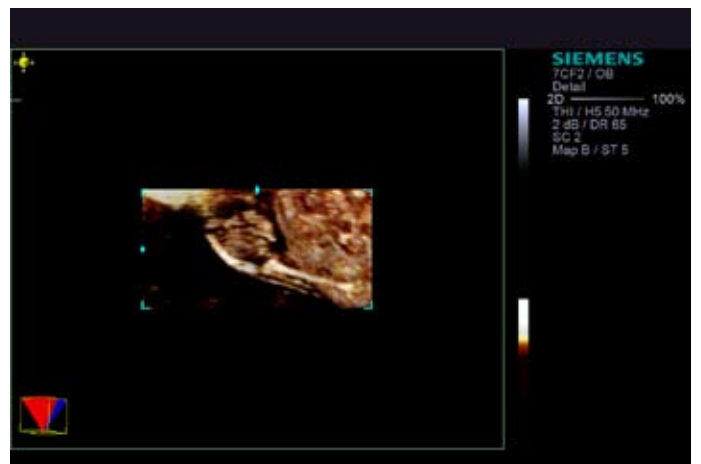


Figure 6b: Skeletal Rendering

Figure 4 (a) MaxIP-based image of a normal fetal spine.

(b) Skeletal Rendering image of the same anatomy demonstrating improved detail resolution.

Figure 5 (a) MaxIP-based image of a large Spina Bifida.

(b) Skeletal Rendering visualization of the same pathology. This true volumetric technique clearly demonstrates widening of the vertebral bodies and adds the depth cues necessary to evaluate spatial relationships.

Figure 6 (a) MaxIP-based image of a 20 week fetus with radial aplasia.

(b) Skeletal Rendering image of the same patient provides superior visualization of the fetal ulna.

**Local Contact Information**

Siemens Medical Solutions USA, Inc.  
51 Valley Stream Parkway  
Malvern, PA 19355-1406 USA  
Telephone: +1-888-826-9702  
[www.usa.siemens.com/healthcare](http://www.usa.siemens.com/healthcare)

Europe: + 49 9131 84-0  
Asia Pacific: + 65 6490 6000

**Global Business Unit Address**

Siemens Medical Solutions USA, Inc.  
Ultrasound  
1230 Shorebird Way  
Mountain View, CA 94043 USA  
Telephone: +1-888-826-9702  
[www.siemens.com/healthcare](http://www.siemens.com/healthcare)

**Global Siemens Headquarters**

Siemens AG  
Wittelsbacherplatz 2  
80333 Munich  
Germany

**Global Siemens  
Healthcare Headquarters**

Global Siemens AG  
Healthcare Sector  
Henkestrasse 127  
91052 Erlangen  
Germany  
Telephone: + 49 9131 84-0  
[www.siemens.com/healthcare](http://www.siemens.com/healthcare)

**Legal Manufacturer**

Siemens Medical Solutions USA, Inc.  
Ultrasound  
1230 Shorebird Way  
Mountain View, CA 94043 USA  
Telephone: +1-888-826-9702  
[www.siemens.com/healthcare](http://www.siemens.com/healthcare)