Endovascular Coil Embolization of Acutely Ruptured Basilar Tip Aneurysm
Supported by *syngo* DynaCT

Arnd Doerfler, MD and Gregor Richter, MD
Department of Neuroradiology, University of Erlangen-Nuremberg, Germany

Patient history
A 56-year-old man presenting with an acute onset of severe headache.

Diagnosis
Acute subarachnoid hemorrhage (Hunt & Hess 1) due to a ruptured multilobulated basilar tip aneurysm.

Treatment
Complete endovascular coil embolization of the aneurysm using detachable platinum coils.

Comments
During placement of the first platinum coil, slight perforation of the aneurysm occurred. Subsequent placement of four additional coils resulted in complete aneurysm occlusion. Clinically, intraprocedural aneurysm rupture was not associated with any deterioration; the patient recovered completely. *syngo* DynaCT was able to immediately visualize the rupture and the amount of new subarachnoid blood und could thus improve complication management within the angio suite.

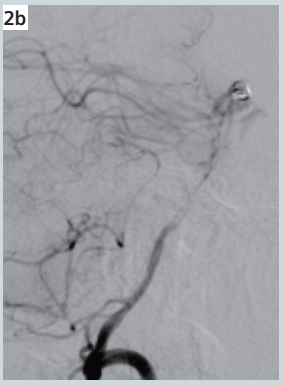

1 Initial CT showed a perimesencephalic subarachnoid hemorrhage.

2 [a-c] 3D rotational angiography illustrating the multilobulated basilar tip aneurysm. Slight contrast extravasation after placement of the first coil. Complete aneurysm occlusion after placement of four additional platinum coils.

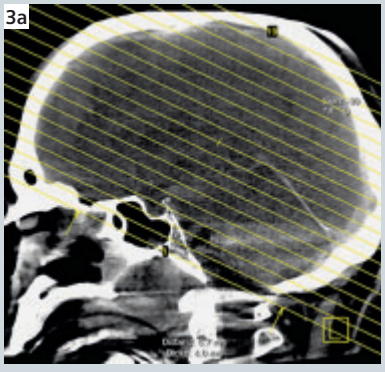

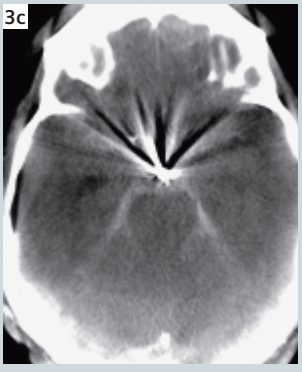

3 [a-d] Immediate *syngo* DynaCT demonstrated the amount of new subarachnoid blood in the basal cisterns with good correlation to conventional CT performed after embolization.