

# DynaCT: A Renaissance in Angiography

Hideyuki Takano, M.D., of the Chiba Cancer Center in Chiba, Japan, discovered a hidden code in DynaCT, a new method allowing the acquisition of CT-like images with an advanced angiography system. Being a passionate art connoisseur and an admirer of Leonardo da Vinci, it is no wonder that he named the code after the renowned Italian Renaissance artist and scientist.

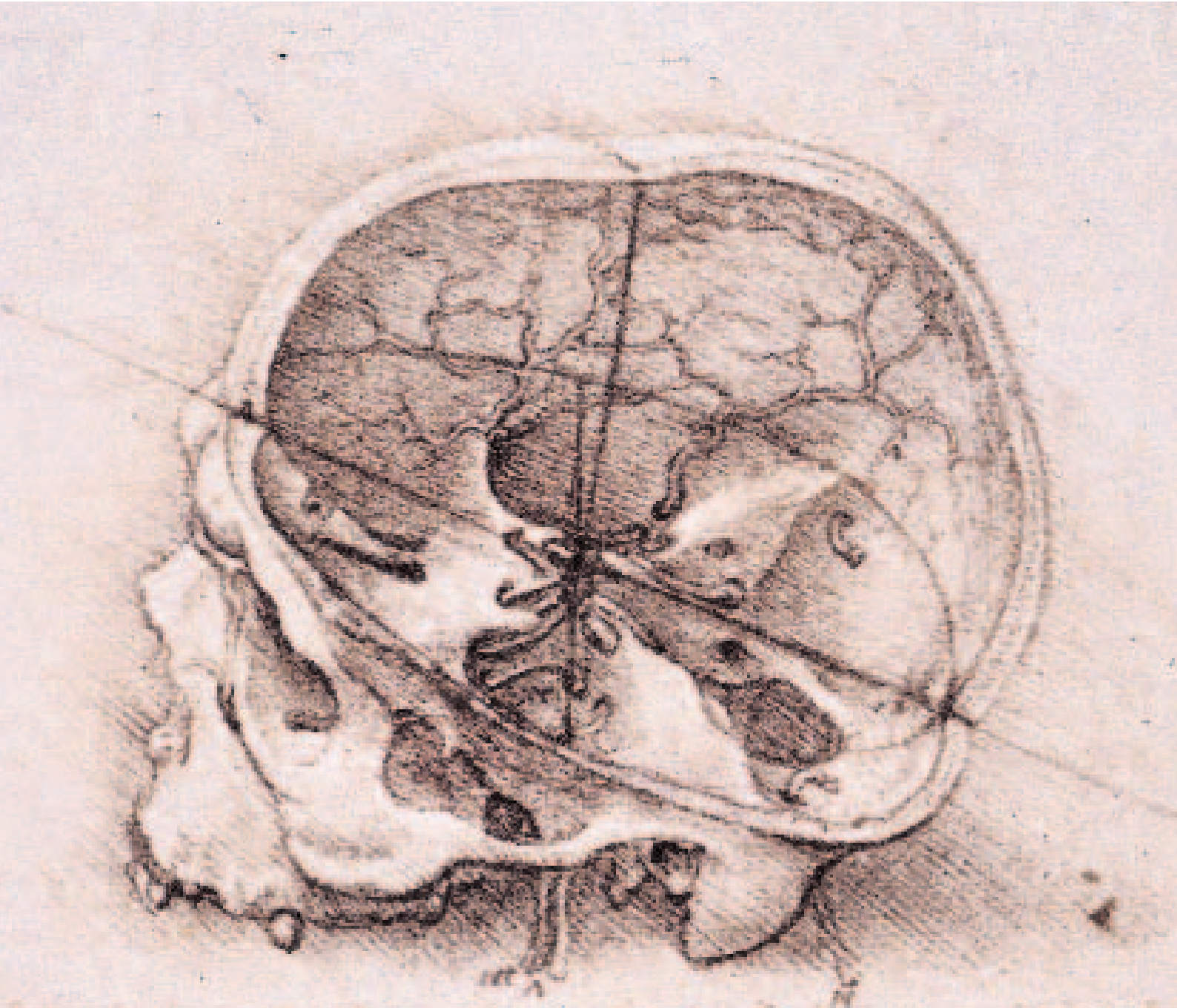
At a symposium hosted by Stanford University during the Annual Meeting of the Society of Interventional Radiology (SIR) in New Orleans in March 2005, Hideyuki Takano, M.D., of the Chiba Cancer Center, Chiba, Japan, shared his experience with DynaCT, a new technology for interventional angiography that produces CT-like images with an angiography system. The keywords in his lecture were “ukiyo-e” and “Da Vinci Mode.” What is behind these keywords and how they are related to DynaCT is illustrated in the following.

## Advantages of DynaCT

In November 2004, Japan’s first DynaCT was installed on Dr. Takano’s AXIOM Artis dTA. DynaCT is an application that can generate CT-like 3D images of soft tissue by rotating the C-arm up to 220°. After the installation,

the Chiba Cancer Center team started to compare DynaCT images with conventional CT images and evaluated its clinical effectiveness. Various areas throughout the body, including the head and the abdomen, were scanned and the evaluation results were impressive.

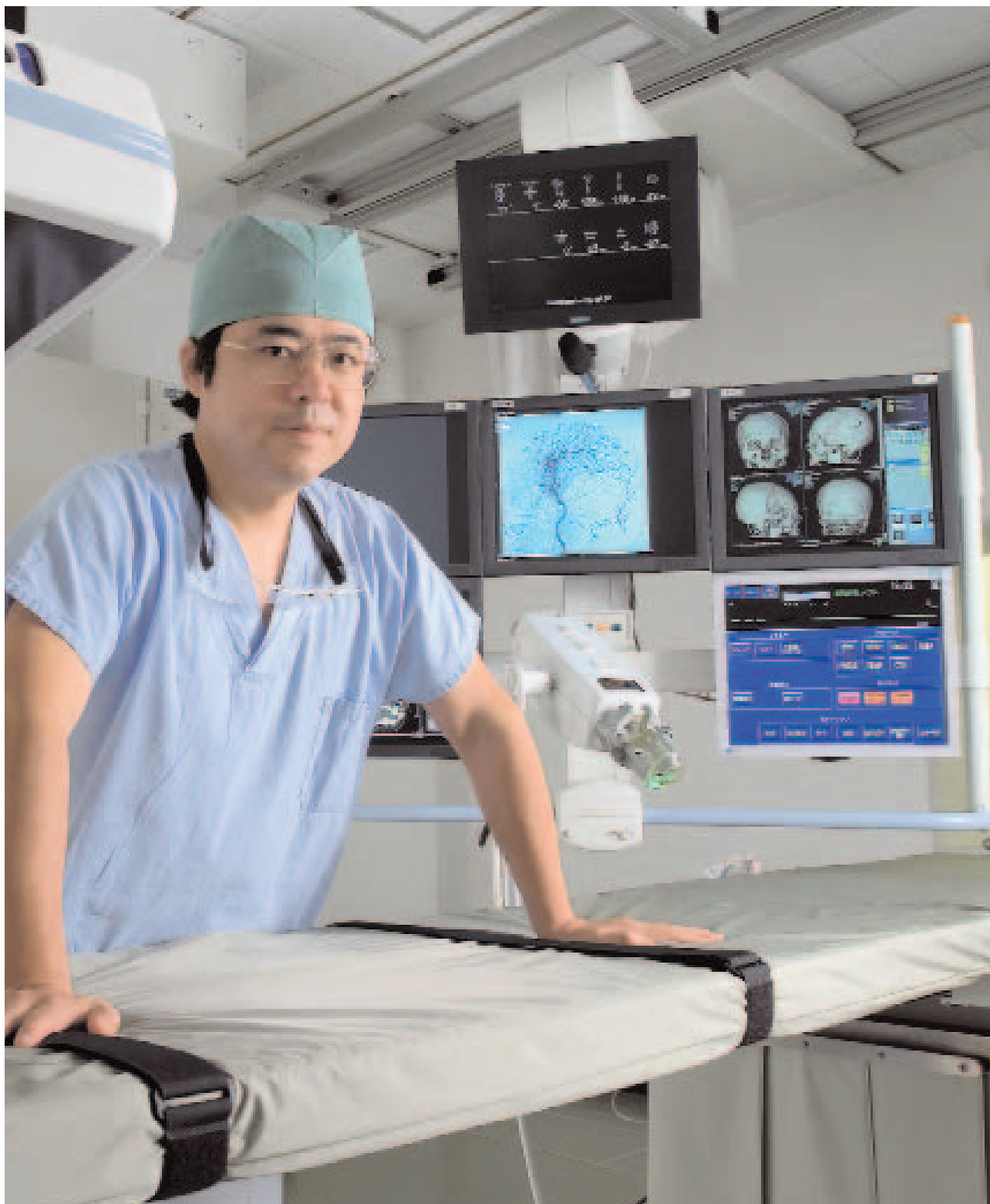“DynaCT performed extremely well and it will become an indispensable function in the interventional field in the near future”, said Takano only two months after the start-up of DynaCT. Although its contrast resolution cannot be compared to that of conventional CT, it is sufficient for interventional applications, providing MDCT-like 2D/MPR images. “This is effective because we can observe images of anatomical structures, including soft tissue, on a monitor in a cath lab without patient transfer. DynaCT will be able to



LEONARDO DA VINCI had a soft spot for anatomical investigation, just like Dr. Takano. One example of Leonardo's series of 3-dimensional skull drawings: an extremely accurate cross-sectional representation of the skull from 1495. Over five hundred years later, Dr. Takano creates completely accurate digital 3-dimensional images using his "Da Vinci Mode" and DynaCT.

replace most of the CT imaging required during interventional procedures," he says, and also commends the significantly improved visualization of small vessels which, in his

opinion is what makes DynaCT so revolutionary. The potential of DynaCT imaging is obvious when comparing it to MDCT images. "First, DynaCT has a smaller voxel size. This is why it

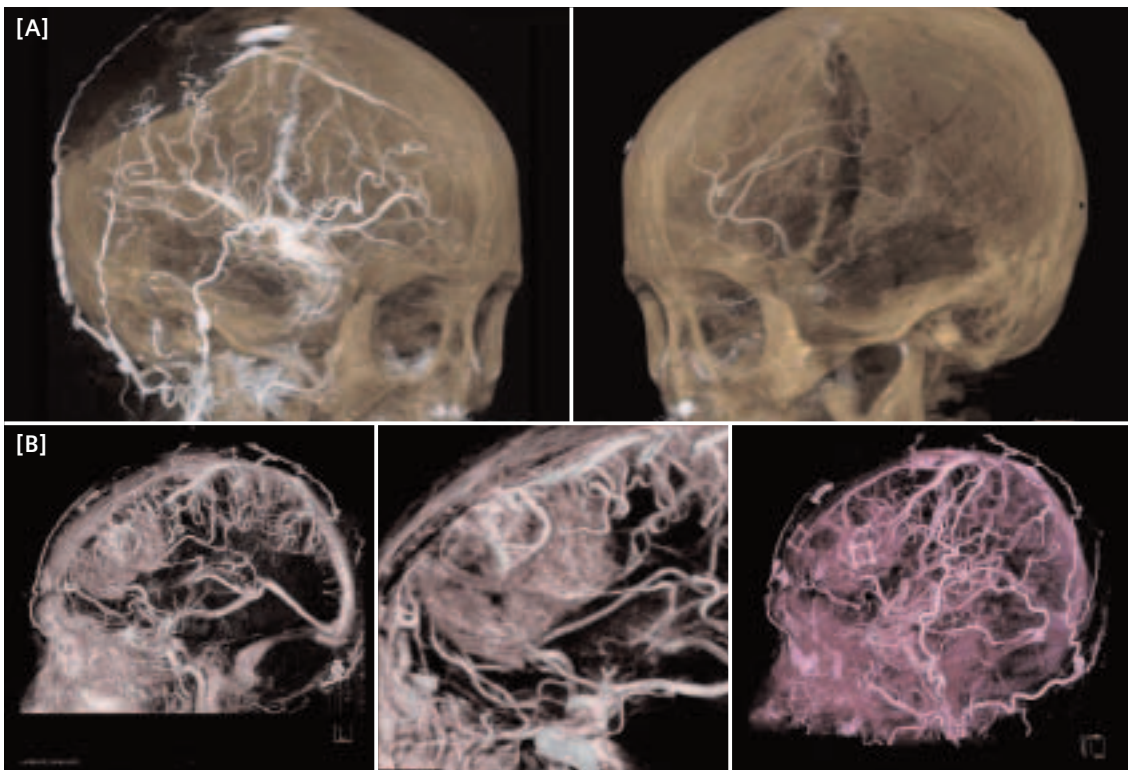


APART FROM DR. TAKANO'S main field of work, abdominal intervention, he is also involved in the entire spectrum of diagnostic imaging, including CT and MRI. He is versed in the latest imaging and processing techniques, such as volume rendering and functional imaging.

DA VINCI Mode

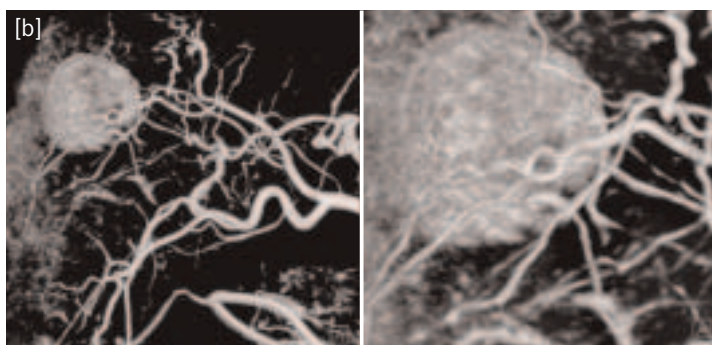
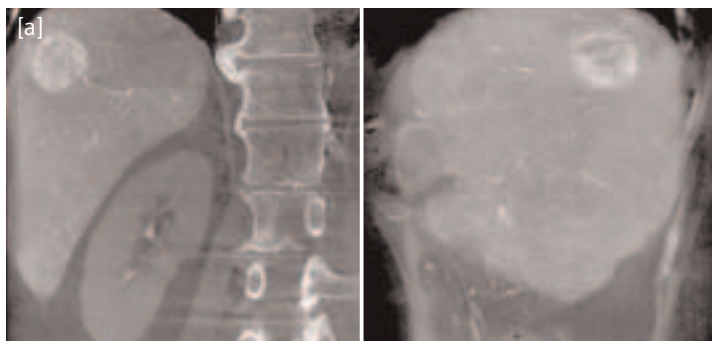


Left: Representative ukiyo-e, "Mikaeri Bijin" ("Looking-Back Beauty") by Hishikawa Moronobu. Right: "The Virgin of the Rocks" by Leonardo da Vinci. Shading, linear perspective, and aerial perspective technique was used in this picture. Dr. Takano associates Da Vinci's more "lifelike" painting with the detailed 3D visualization of soft tissue. "The difference between the ukiyo-e drawing and the Renaissance painting is comparable to the difference between the fine display of solid models and the detailed visualization of soft tissue as a cluster of particles and lines using the Da Vinci Mode," Dr. Takano explains.



**[A] RECURRENT MENINGIOMA:** "Da Vinci Mode"; 3D display, DynaCT DSA/DR 10 sec; Occipital artery supplies a recurrent meningioma adjacent to a bony defect. Intra- and extra-cranial arteries can be easily differentiated on each single image.

**[B] RECURRENT OLIGODENDROGLIOMA:** DynaCT DSA/DR 10 sec: 3D geometries of the soft tissue and small vessel structures in DSA can be evaluated at the same time with the "Da Vinci Mode."

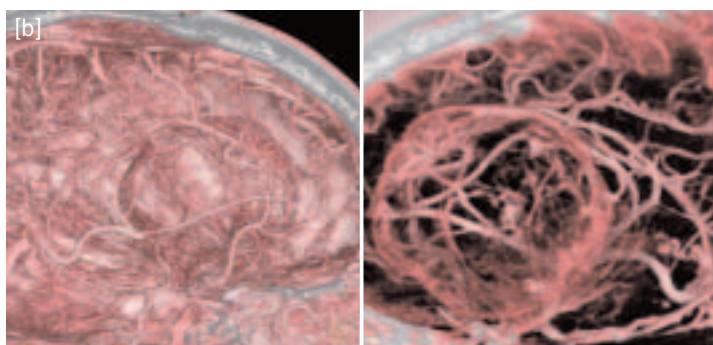
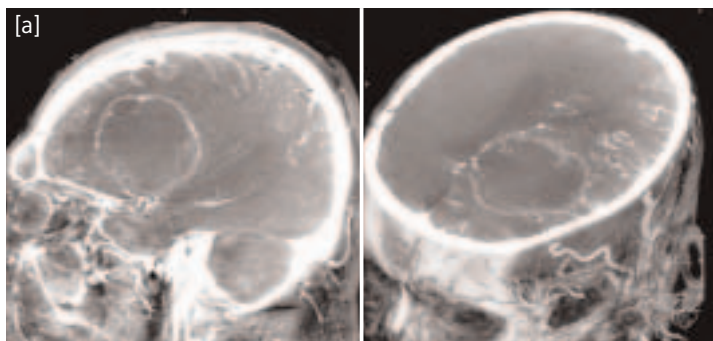


**HEPATOCELLULAR CARCINOMA – EMBOLIZATION**

DynaCT: DR 10 sec

[a] MPR (coronal, right lateral) images showing enhanced tumor on S8.

[b] VRT images: DynaCT can visualize small vessels – in three-dimensional direction.

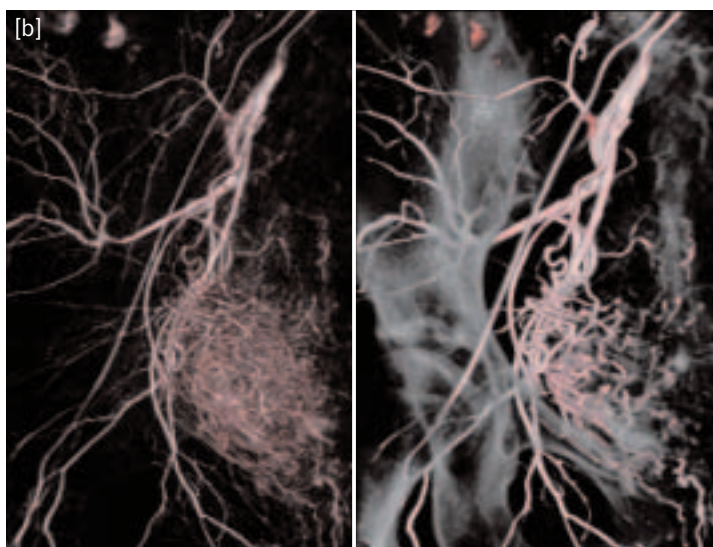
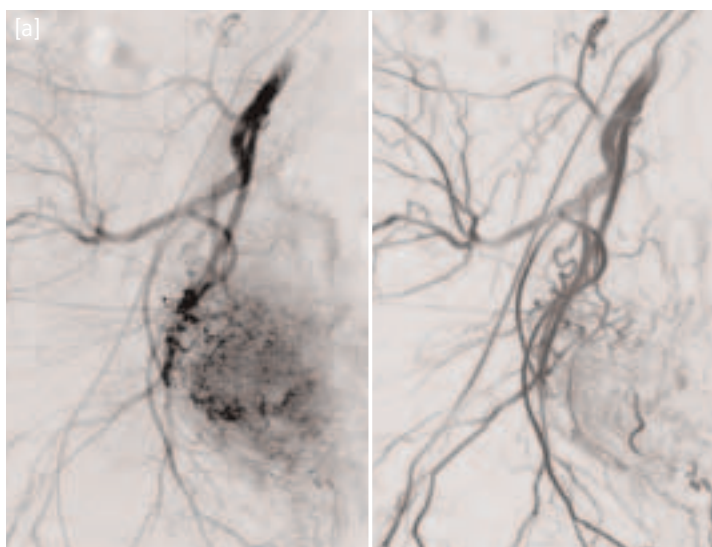


**METASTATIC BRAIN TUMOR – NEURO NAVIGATION**

DynaCT: DR 10 sec

[a] MPR (sagittal, oblique) images: Size and shape of the enhanced tumor and the other soft tissue is shown.

[b] VRT images: Spatial relationship between tumor and vessel is obvious. Clear differentiation of artery and vein. This kind of information is useful for neuro navigation or vessel mapping.



**COMPARISON ORIGINAL DSA AND DynaCT – recurrent ovarian tumor – DynaCT: DR (Dynavision Run)/DSA 10 sec**

[a] Left: Original DSA image. Right: DynaCT – Negative MIP DynaCT image can provide fine peripheral vascular. The image quality is equivalent to original DSA.

[b] Left: DynaCT – VRT. Right: DynaCT – Dual volume VRT (DSA + DR mask). DynaCT can provide three-dimensional information. Spatial relationship between vessel and other vessel or bone is clearly shown on VRT image processed by DSA and DA data.

delivers a higher spatial resolution than MDCT. Second, it has a wide dynamic range and improved continuity of the density of adjacent voxels. Third, the voxels have a perfect cubic shape, which is a great advantage over MDCT. The thickness of the MDCT slices has a negative effect on its voxel shape," Dr. Takano explains.

Regardless of their direction, DynaCT can accurately depict contrast-enhanced vessels, from large to small. The revolutionary imaging method is capable of more accurate data acquisition than isotropic CT in the form of "Cubic Voxel Imaging." With its capability to accurately visualize the details, DynaCT is now used as an effective tool in abdominal, oncologic, neurologic, and other procedures.

### The Code in DynaCT

Dr. Takano has been so immersed in the evaluation of DynaCT data, he made a significant discovery himself: an important hidden code in the DynaCT data. This code reveals that some enhanced soft tissue data is in fact included in the DSA data. To visualize these data as a 3D object, Dr. Takano proposed an innovative 3D display mode. With this 3D rendering technique, an object is not displayed as a solid model composed of contours and surfaces, but displayed as a cluster of particles and lines or a cloudy volume. "With this display mode, 3D geometries of both the soft tissue and small vessel structures can be evaluated at the same time. And since the DSA technique removes the bone tissue data that interfere with the observation of internal structures, time-consuming 3D editing has become a thing of the past," explains Takano. "The fine display can be referred to as a drawing rather than a painting. And the detailed visualization reminds me of realistic or lifelike Renaissance art rather than Impressionism art influenced by ukiyo-e art, known for its typically flat, two-dimensional paintings. In this mode, a third perspective is employed to facilitate three-dimensional viewing of the object," he adds.

According to Dr. Takano, this is very similar to the technique that Leonardo da Vinci used in his art, and differs greatly from the one

employed in ukiyo-e. No wonder he calls his new display technique "Depth-aligned Vasculatures in cloudy imaging mode," or "Da Vinci Mode."

### The Future of DynaCT

The potential of DynaCT is tremendous. Besides using DynaCT as a substitute for conventional CT, it is also important to explore its unique characteristics and its new fields of application. "From the viewpoint of diagnostic imaging and interventional radiology, DynaCT has great potential," Takano emphasized. "Indeed, I like to think of it as a Renaissance in angiography."

»DynaCT performed extremely well and it will become an indispensable function in the interventional field in the near future.«

Hideyuki Takano, M.D., Chiba Cancer Center, Chiba, Japan

### The Functional Principle of DynaCT

DynaCT is the latest innovation for C-arm angiography systems, enabling the visualization of soft tissue. It enhances diagnostic capabilities in the angio lab with a technology called Angiographic Computed Tomography (ACT). CT-like 3D images can be generated during an ordinary angio procedure, thereby virtually avoiding patient transfers to CT or MRI systems.

Images from a rotational angiography which run at a C-arm angle of 220° are reconstructed on the LEONARDO workplace and available for assessment in approximately 3 minutes. Image acquisition takes approximately 10 seconds. DynaCT images enable the visualization of objects of 10 HU difference and 10 mm in size.