

# Technical Advances in Colorectal Cancer Screening

In the colon and rectum, the vast majority of cancers develop very slowly, approximately over a period of 10 to 15 years, from benign precursor lesions. These lesions, so-called polyps, can undergo malignant transformations based on the adenoma-carcinoma sequence. Therefore, the resection of polyps reduces colorectal cancer mortality by over 90 percent.

*By Anno Graser, M.D., and Christoph R. Becker, M.D., Department of Clinical Radiology, University of Munich, Grosshadern Campus, Munich, Germany*

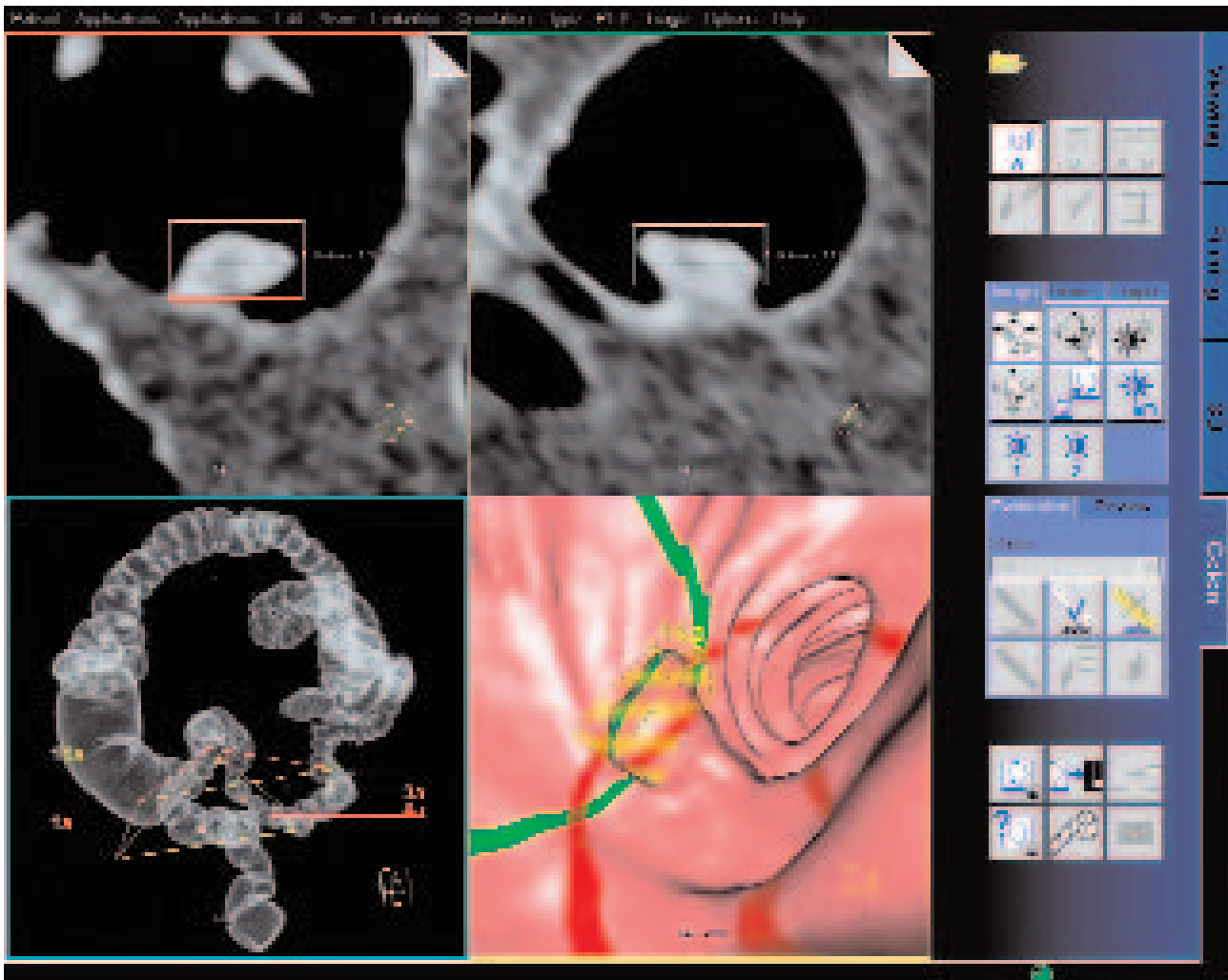
Computed tomographic colonography (CTC), also referred to as virtual colonoscopy (VC), shows a promising potential for colorectal cancer (CRC) screening due to its high sensitivity and specificity in the detection of colorectal polyps [1, 2]. Over the last months, the ongoing discussion about how to perform screening for colorectal cancer has intensified. In Germany, as well as in the United States, recommendations have been made that every person over 55 years of age undergo a CRC screening with colonoscopy. However, this type of examination lacks acceptance among patients, requires sedation, and is associated with the risk of bleeding and colonic perforation, which may have to be treated by laparoscopic or open repair. Although the risk of these complications is negligible if colonoscopy is performed by an experienced gastroenterologist, many patients are not comfortable with the exam. In Germany, overall participation in the national colorectal cancer screening program was as low as 2.2 percent or 300 000 persons screened in 2004. In

view of the fact that 20 million people are in the risk age group, looking for reliable alternative screening tests becomes indispensable.

Over the last ten years, technical advances in CT scanners, as well as post-processing software, have led to increased diagnostic performance of CTC. After the introduction of four-detector row scanners in 1998, the technique of virtual colonoscopy has improved tremendously. A recent multi-center study showed a very high sensitivity in the detection of colorectal polyps [1]; two studies published shortly afterward raised doubt as to whether these results are reproducible [2, 3].

## Technical Advances in CT Colonography

These scientific papers, published in late 2003 and 2004, have clearly shown that the sensitivity for polyp detection depends on technical parameters as well as reader experience. Therefore, using the best available CT technique and thorough



**3-DIMENSIONAL ENDOLUMINAL VIEW** (right bottom), coronal and axial views of a 17-mm polyp in the sigmoid colon showing automated polyp size measurement with *syngo* Colonography.

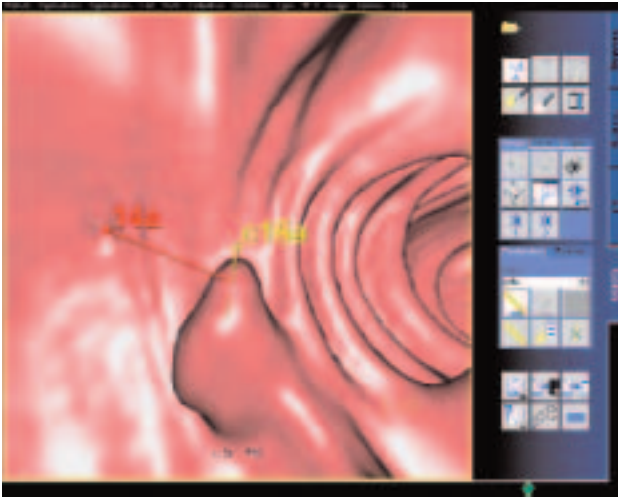
training on how to read the scans when getting started on performing CTC becomes mandatory. Image quality is crucial for the detection of lesions within the colonic lumen. In CTC, image quality depends on the number of detector rows, X-ray beam collimation, reconstructed slice thickness, and image noise which is influenced by the radiation dose delivered to the patient.

### Image Quality

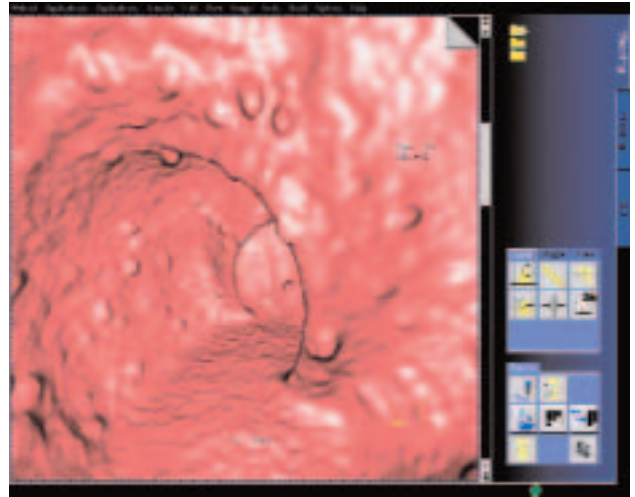
In our institution, we previously used a 4-slice SOMATOM® Sensation 4- and 16-detector row scanner for CTC exams. At an X-ray beam collimation of 4 x 2.5 mm, resolution was sufficient for the detection of larger intraluminal filling defects, and the short examination time enabled scanning the whole

abdomen in one single breath hold. However, peristaltic motion artifacts, breathing artifacts, and the detection of small lesions have remained an issue. When the first 16-slice scanners were installed in 2002, image quality and resolution were exceptionally improved. With a slice thickness of 0.75 mm, an improvement in quality for endoluminal fly-through images could be achieved, and lesions as small as 2 mm were reliably detected.

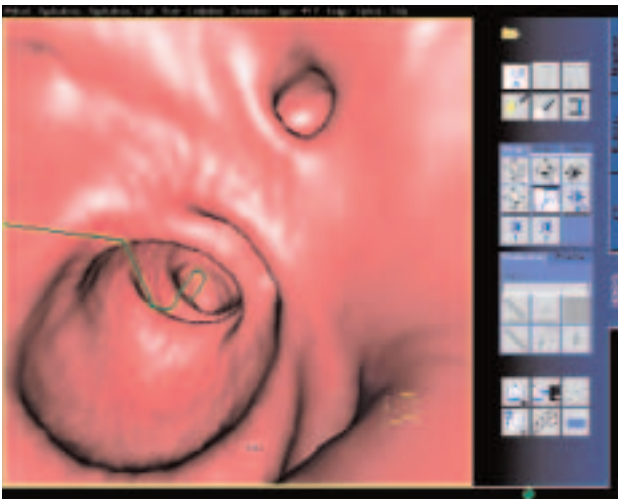
Since July 2004, we have been using a SOMATOM Sensation 64, yet again an improvement in image quality and resolution at a collimation of 0.6 mm, with z-Sharp™ Technology. Visualization of both normal bowel wall and intraluminal filling defects have improved in a way that can truly be called a quantum leap compared to the first multidetector row



**COMPUTER-AIDED DETECTION** (Polyp Enhanced Viewing, PEV) detected this 10-mm polyp (yellow marker "c15a"). The polyp was also detected by the reporting radiologist (red marker "14a").



**A RARE CASE OF FAP** as seen on endoluminal low-dose CTC scan in a 37-year-old female patient. Multiple polypoid lesions line the mucosa of the sigmoid colon. SOMATOM Sensation 64, 120 kV, 40 reference mAs, CARE Dose4D.



**DIVERTICULA ARE A COMMON FINDING** at CTC. Their typical appearance on endoluminal fly-through images makes them easily distinguishable from polypoid lesions in most cases. Image from SOMATOM Sensation 64, 0.6-mm collimation, 120 kV, 120 reference mAs, CARE Dose4D.

scanners. In addition, the extremely short acquisition time of 6 to 7 seconds per position makes it comfortable for patients to hold their breath.

## Radiation Dose Considerations

People who want to undergo colorectal cancer screening should be offered the most reliable and least invasive method. If performed with state-of-the-art MDCT scanners, in the detection of polyps, CTC certainly has the potential to

become just as sensitive as optical colonoscopy. However, the issue about applying ionizing radiation to a healthy individual may not be neglected. The radiation dose used in this examination should be kept to a minimum. When assessing the colonic wall, the high, intrinsic contrast between the wall and the air-filled lumen enables low-dose scanning. However, in order to assess extracolonic findings, a certain amount of image noise should not be exceeded.

A complete CTC exam always includes scanning in supine and prone position to differentiate between real lesions which will not alter their position between the two scans, and residual fecal material which, even after thorough bowel cleansing, can be detected inside the colonic lumen. To keep patient radiation exposure as low as possible, scans should be performed using low-dose technique. The reduction of tube current to very low settings (lower than 60 mAs at 120 kVp), however, will prevent the evaluation of extracolonic findings.

Both systems, SOMATOM Sensation 16 and 64, are equipped with a sophisticated dose modulation technique, CARE Dose4D™, which was clinically tested in our institution. As image quality is very important in order to reach high sensitivity in polyp detection, very low dose settings will result in increased image noise. On endoluminal images this shows as the characteristic "cobble stone" pattern of the colonic wall. Obviously, small polyps are not detected in noisy images. CARE Dose4D, a software tool that modulates the CT tube current-time product (mAs) in the patient's x-, y-, and z-plane allows a significant dose reduction in CTC. Based on the patient's individual attenuation profile, the X-ray tube delivers

\* Results may vary. Data on file.

the amount of radiation required to reach the image quality defined beforehand. There is minimal interaction between the technologist and the CT scanner, as CARE Dose4D automatically measures the attenuation during the topogram scan. By using this software, the amount of dose during a CTC exam can be decreased by 32 to 35 percent\* while retaining a constant image quality. Our study has shown that this occurs at settings of 120 kVp and 120 mAs (supine) as well as 120 kVp and 40 mAs. The overall radiation exposure in a normal-weighted patient is as low as 4 to 5 mSv when using these settings and CARE Dose4D [4]. The routine use of CARE Dose4D leads to a significant dose reduction in CTC, which is especially important in a screening population.

## Computer-Aided Detection (CAD) in CT Colonography

As mentioned above, reader experience is crucial in CTC, reading time and diagnostic accuracy depends on the number of scans a radiologist has read. To reach an acceptable sensitivity at low numbers of false positive findings, we recommend that a minimum of 50 training cases should be read before working with CTC in a clinical setting. The long learning curve and interpretation time can be reduced by CTC workstation training sessions. Siemens' LEONARDO® workplace enables rapid evaluation – no matter whether primary 2D or 3D evaluation is preferred by the user. There is still no consensus among professionals which method should be preferred.

As computer-aided detection software is becoming available for CTC, it appears that its use as a so-called "second reader" may increase the "human reader's" confidence and shorten evaluation time. When using CAD, a computerized scheme automatically analyzes images, searching for polypoid lesions within the gas-filled colon. After segmentation of the colon, possible polyps are being marked in the image. This population will be reviewed by the CAD algorithm in order to eliminate false positive findings while maintaining the highest possible sensitivity. Therefore, CAD can decrease human readers' perceptual errors, in other words, reduce the number of polyps missed by the radiologist, and in addition decrease inter-observer variability [5].

In a study that was performed at our institution and presented at the meeting of the European Society of Gastrointestinal and Abdominal Radiology (ESGAR) in May 2005, we showed that in 120 patients that the Siemens CAD tool, *syngo* Colonography with PEV (polyp enhanced viewing), detects 94 percent of polyps between 6 and 9 mm in size and 87 percent of polyps 10 mm in size or larger. Using 16-MDCT datasets, the number of false positive findings was 3.3 per dataset. Most false positive findings, like the ileocecal valve or stool residua, could be easily dismissed. The average time

of *syngo* Colonography with PEV amounts to 4 minutes per dataset. While the program runs in the background, the radiologist reviews the dataset without any interference.

## Conclusion

CTC is an emerging technique in colorectal cancer screening. There is an increasing demand for this noninvasive and quick examination, which can only be met by radiologist training. Technical prerequisites, however, are of key importance for reproducible results. Scans should be performed on 16- or 64-slice scanners, and a dedicated workplace like LEONARDO is necessary to enable smooth clinical workflow and short reporting times. Computer-aided detection algorithms can further increase readers' diagnostic confidence, and help to lower inter-observer variability; in addition, they improve the diagnostic performance of radiologists with little experience in reading CTC and may therefore facilitate implementation of CTC in a clinical environment.

## References

- [1] Pickhardt PJ, Choi JR, Hwang I et al. Computed tomographic virtual colonoscopy to screen for colorectal neoplasia in asymptomatic adults. *N Engl J Med* 2003; 349:2191-2200
- [2] Cotton PB, Durkalski VL, Pineau BC et al. Computed tomographic colonography (virtual colonoscopy): a multicenter comparison with standard colonoscopy for detection of colorectal neoplasia. *JAMA* 2004; 291:1713-1719
- [3] Rockey DC, Paulson E, Niedzwiecki D et al. Analysis of air contrast barium enema, computed tomographic colonography, and colonoscopy: prospective comparison. *Lancet* 2005; 365:305-311
- [4] Graser A, Wintersperger BJ, Suess C, Reiser M, Becker CR. Dose reduction and image quality assessment in multi-detector row CT colonography by x, y, z-axis tube current modulation. *AJR Am J Roentgenol* 2005; in press
- [5] Yoshida H, Dachman AH. Computer-aided diagnosis for CT colonography. *Semin Ultrasound CT MR* 2004; 25:419-431

**Authors:** *Anno Graser, M.D., became assistant physician at the Department of Clinical Radiology at University of Munich's Grosshadern Campus in 2004. His research specializes on virtual colonoscopy and urogenital radiology. After finishing medical school at the University of Munich, he completed his clinical elective at Memorial Sloan-Kettering Cancer Center, Department of Radiology, New York (body imaging). He spent his residential practical trainings at Universidad de La Laguna de Tenerife, Spain (orthopedic surgery and traumatology), University of California San Francisco (UCSF), Department of Radiology (body imaging, musculoskeletal imaging, ultrasound), and University of Munich, Grosshadern Campus, Medical Clinic and Polyclinic I (internal medicine).*

*Christoph R. Becker, M.D., was born in 1964 in Giessen, Germany. He visited the School of Medicine at the Semmelweis University in Budapest, the University Homburg-Saar and the Ludwig Maximilian University in Munich. His doctorate thesis had the topic "In vivo and in vitro H1-MR-spectroscopy of intracerebral tumors." He is an assistant medical director at the University Clinic in Grosshadern, Munich, for computed tomography. His main research area is noninvasive imaging of the heart and vessels.*