

Case Report: Abdominal Neuroblastoma

Michael Kean; Michael Ditchfield, M.D.

Children's MRI Centre, Royal Children's Hospital, Parkville, Victoria, Australia

Patient history

3-year-old* girl with a history of Neuroblastoma presented with urinary retention and constipation. Suspicion of spinal cord compression.

Sequence details

Transverse Turbo Spin Echo (TSE) sequence with *syngo* BLADE motion correction. TR 4000 ms, TE 99 ms, BW = 360 Hz/Pixel, Turbo Factor 35, slice thickness 5 mm, FOV 250 mm, Matrix 256 x 256. Images were acquired on our 1.5T MAGNETOM Avanto using the Body Matrix coil.

Image findings

Confirmation of intraspinal disease progression through neural foramin to form an extradural mass. There is impingement of the distal spinal nerve roots but no spinal cord compression. The MR clearly depicts greater disease extent than represented on the previous CT scan.

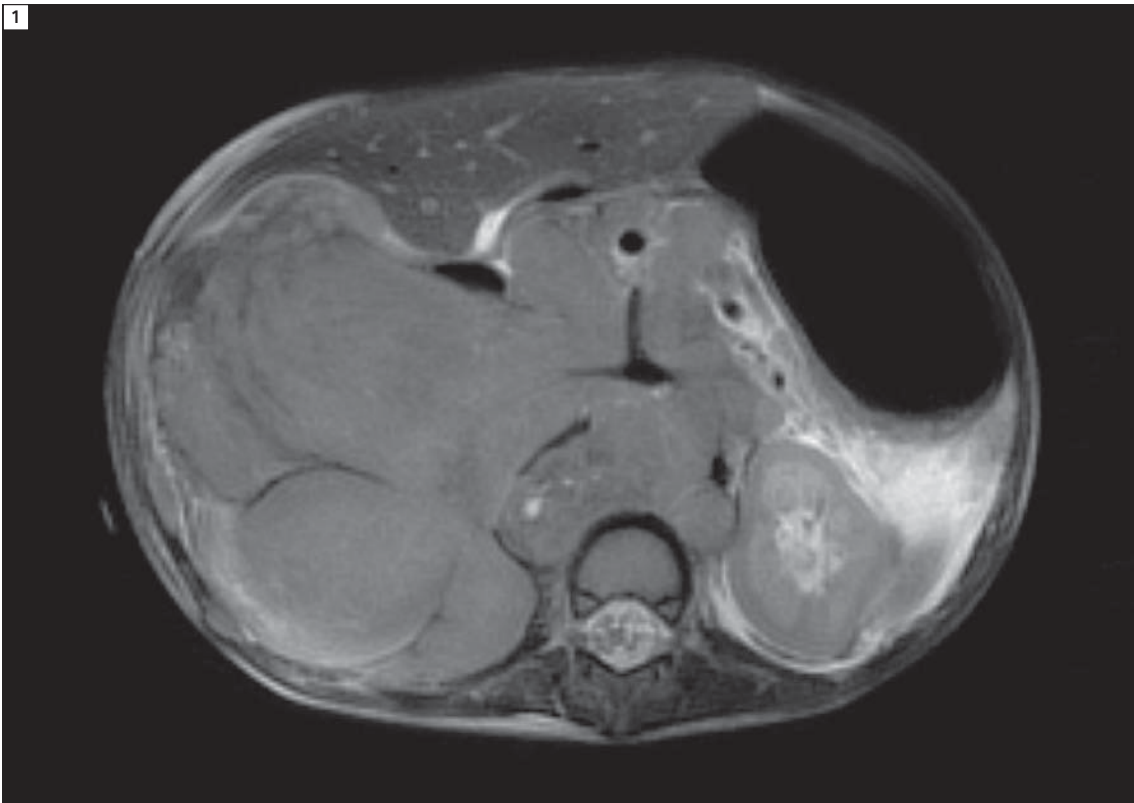
Comments

syngo BLADE was used to offset the motion of abdominal contents due to respiration. The images did not use any form of navigator based respiratory compensation.

Contact

Michael Kean
Children's MR Centre
Royal Children's Hospital
Melbourne, Australia
michael.kean@rch.org.au

* The safety of imaging fetuses/infants has not been established.



1 Transverse T2-weighted Turbo Spin Echo sequence with *syngo* BLADE motion correction was used in this case of a 3-year-old girl. This image was acquired while free breathing and without navigator based respiratory compensation, clearly demonstrating the potential of *syngo* BLADE in reducing motion artifacts. In this exemplary chosen transversal slice it is demonstrated that the extent of the abdominal neuroblastoma is well delineated and all relevant anatomical structures are visualized in detail.